

## 03 Years Outcome Analysis of Non-cemented Total Hip Arthroplasty in Complicated Hip Pathologies in Young Adults of Poor Socioeconomic Background

Faisal Masood,<sup>1</sup> Abdul Latif Sami,<sup>2</sup> S. M. Awais<sup>3</sup>

### Abstract

**Place of Study:** Department of Orthopedic Surgery and Traumatology Unit I, K.EM.U, MHL, LHR.

**Period:** September 2008 to September 2011.

**Design:** Analytical.

Hip joint is very commonly involved by traumatic and non-traumatic conditions in younger age group especially of poor socioeconomic and industrial workers (who are commonly encountering such problems) and frequently requires surgical intervention and Non-cemented Total Hip Arthroplasty in young Patients is considered a better option.<sup>1-3</sup> We evaluated the outcome of this procedure in such cases and operated 53 cases of complex Hip problems with NC THA, which were Hydroxyapatite coated. Majority of the cases were Idiopathic AVN (15), Post Infectious Hip Arthritis (07), Skeletal Dysplasia (01), Post Traumatic Colla-

pse (11), 01 case of B/L hip neglected dislocation in an epileptic patient, Ankylosing spondylitis (08) and Old Perthe's disease (03), Rheumatoid Arthritis (03), Old Fracture Acetabulum with Posterior Dislocation with AVN of femoral Head (01). There were more males (25) as compared to 05 females with M:F ratio 5:1. Mean age was 32 years (range from 18 years to 48 years). There were 03 cases of bilateral involvement so total No of THRs were 53. All the patients were assessed pre-operatively by Harris Hip score, which was 49 with Pain interfering with daily activities, was the main complaint. Average shortening was 02 cm except in three Hips (02 of Girdle Stone Procedure and 01 Old Fx neck of femur). These 03 hips were having 5 – 7 cm shortening with GT abutting against the Ileum. Skeletal traction was applied pre-operatively for 03, and GT were brought down and THR was done after 06 – 08 Wks of removal of fixator. Mean shortening was 03cm. Harding's anterolateral approach was used in all cases. Hydroxyapatite coated Modular type Non-cemented THA was used. Wt. bearing started at 12 – 14 weeks. Mean Harris Hip Score Improved from 49 to 88 at 03 years after surgery. We had only one case of superficial Infection, which settled with antibiotics. Only one case developed recurrent (05 episodes in 03 years) dislocation on left side in epileptic patient, which occurred each time after fits & could be reduced under GA. The right hip remained stable. There was no DVT, implant subsidence, Myositis ossificans or NV damage no residual shortening. There

---

Masood F.<sup>1</sup>

Department of Orthopedic Surgery and Traumatology Unit I, K.EM.U, Mayo Hospital, Lahore

Sami A.L.<sup>2</sup>

Department of Orthopedic Surgery and Traumatology Unit I, K.EM.U, Mayo Hospital, Lahore

S. M. Awais<sup>3</sup>

Department of Orthopedic Surgery and Traumatology Unit I, K.EM.U, Mayo Hospital, Lahore

was a learning curve with positioning of acetabulum, which was vertical in the beginning but improved subsequently. Although the follow up is very short but so far now, Non-cemented THA is a good option in younger pts even with complex Hip problems that significantly improves the functional abilities of the patient as well as eliminates pain. Moreover, even if it requires revision later on it can be done with cemented implants.

## Introduction

Hip joint, in contrast to Knee and ankle is very frequently the focus of problematic pathologies whether be it trauma, infection, AVN, Congenital, Infantile, Inflammatory or iatrogenic. More over majority of such problems involve younger patients who have most of their productive as well as reproductive life ahead. Adding insult to the injury these hip problems are so crippling that most of the time patient has to seek for surgical intervention. There are different available options such as Hip Arthrodesis, Girdle stone resection arthroplasty and Hip replacement. Each has its own merits demerits.

Traditionally such pathologies in past had usually been treated by Arthrodesis or Girdle stone Resection arthroplasty depending upon the requirement of the patient. Arthrodesis was handicapped with limitation of sitting and squatting where as Girdle stone had the disadvantage of poor control of limb around hip and eventually many of them become painful either at hip or spine due to increased forces acting on these areas after resection of proximal femur. Arthroplasty was usually avoided keeping in mind the price of the implant as most of such patients are from lower socioeconomic class and could not afford this expansive treatment. Aseptic loosening is the most common mode of failure of cemented total joint replacements. Various factors including patient selection, implant design and cementing technique have been implicated in the failures. Most of such patients are unfortunately young are responsible for bread and butter of their family so that their disability always had more socioeconomic effects than the disease itself. We persuade with Pakistan Bait-ul-Maal for such deserving but non-affording cases. By their kind co-operation we were able to help such cases. Therefore, from September 2008 we started operating such cases of complex Hip pathologies

with non-cemented THR in about 50 patients (53 Hips), and followed them for 03 years.

## Materials and Methods

All cases were young. All of them were assessed with Harris Hip Score both pre and post-operatively. Radiographic evaluation was done with AP and Lateral views of hip and Templating was done. Patients were evaluated for any obvious or hidden infection in the body. 2<sup>nd</sup> generation Cephalosporins were started pre-operatively and were given for 03 days post operatively and then switched over to oral Cephalosporins for 10 days when stitches were removed. Pt was kept non-weight bearing for 03 months with crutch ambulation. Oral Vit. D and Bisphosphonates were given for better Bone-implant interphase development. Patients were evaluated on regular basis clinically as well as radiologically. Functional and Radiological outcome was documented based on Harris Hip score and X-ray evaluation respectively. Results were statistically analyzed using SPSS and T-test.

## Results

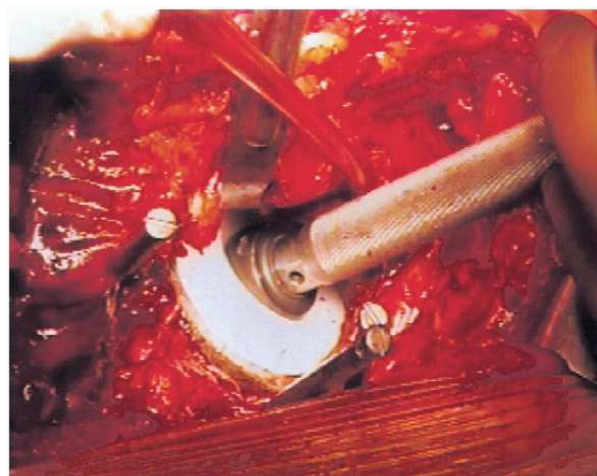
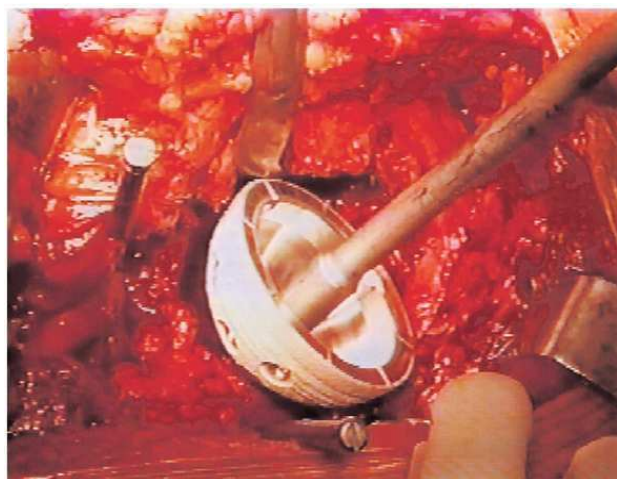
A total 50 patients with different Hip pathologies were operated. Out of which majority were of Idiopathic AVN (15), Post Traumatic Collapse (11). There was 01 case of B/L painful posterior dislocations which were neglected for more than 06 months. MRI showed a non-viable head and it was interesting to see that most of the orthopedic surgeons declared him untreatable. The detail of these cases is shown in the table. There were more males (25) as compared to 05 females with M:F ratio 5:1. There were 03 cases of bilateral involvement so total No of THRs were 53.

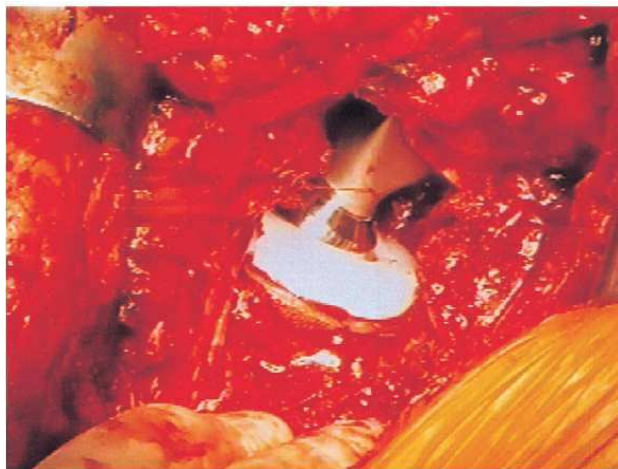
The mean age was 29 with range from 18 to 48 years. Patients with active infection anywhere in the body were excluded and all the patients which were selected were screened with ESR and CRP other than the routine investigations. Patients were evaluated radiologically with AP and Lat views of Hip both for assessing the type and severity of problem as well as for pre-operative Templating. Patients were assessed clinically and Harris Hip Scoring System was used to evaluate the severity of problem both pre-op as well as post-op. the most important aspect of this study was that all of these patients were very poor and were non-affording but required surgery. They all were helped to have total free treatment with the help of Pakistan Bait-ul-Maal. Patients were given 2<sup>nd</sup> generation Cephalosporins IV for 03 days post-operatively. Non-wt

bearing early ambulation and physical exercises were started. We use 325 mg of aspirin daily, in conjunction with elastic compression stockings and mechanical foot pumps for thromboembolic prophylaxis.

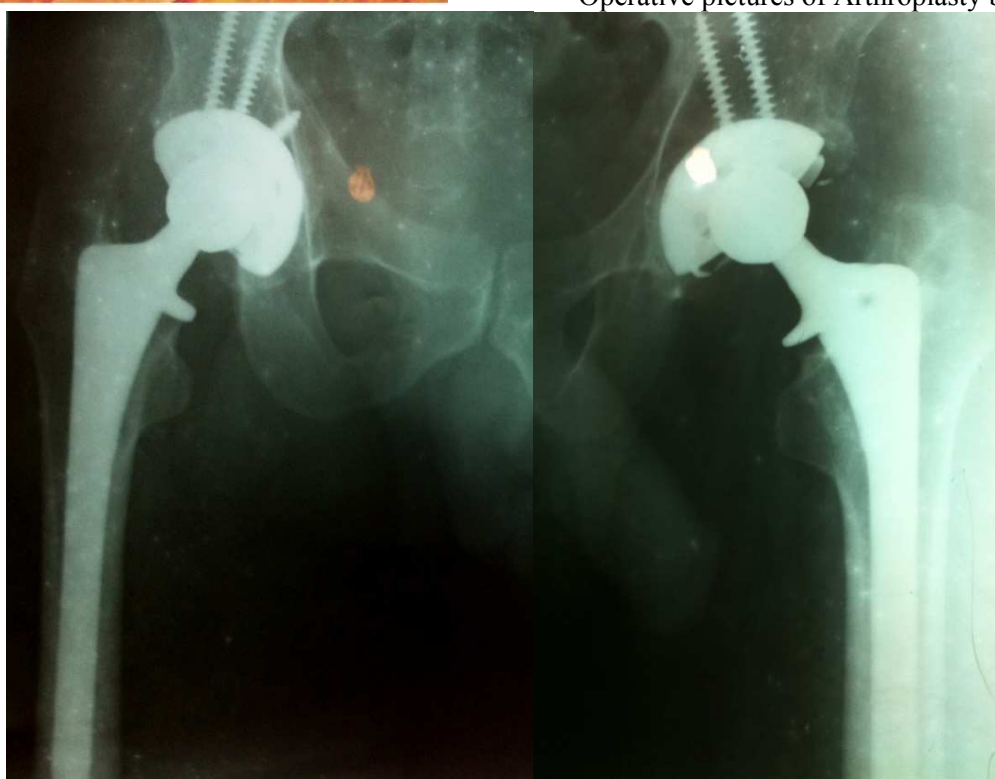Patients were mobilized on the first postoperative day. Physical and occupational therapy included instruction in total hip precautions with avoidance of hip flexion of greater than 90 degrees and any degree of internal rotation or adduction. Patients were discharged with Lofstrand crutches and are advanced to the use of a cane in the contralateral hand at the discretion of a home physical therapist (usually at 3 weeks). The occupational therapy department arranged for the use of an elevated toilet seat and additional devices. All the patients were assessed monthly for first three months with X-rays and Harris Hip Scoring was applied. Weight bearing was

Sr. No.	Detail of Cases	Total
01.	No of patients	50
02.	No of Hips	53
03.	No of Bilateral Hips	03
04.	Idiopathic AVN	15
05.	Post traumatic collapse	11
06.	Post Infectious Hip Arthritis	07
07.	Ankylosing Spondylitis	08
08.	Old Perth's disease	03
09.	RA	03
10.	Skeletal Dysplasia	01
11.	Old Fracture Acetabulum with AVN of Hip	01
12.	B/L painful neglected posterior hip dislocations	01

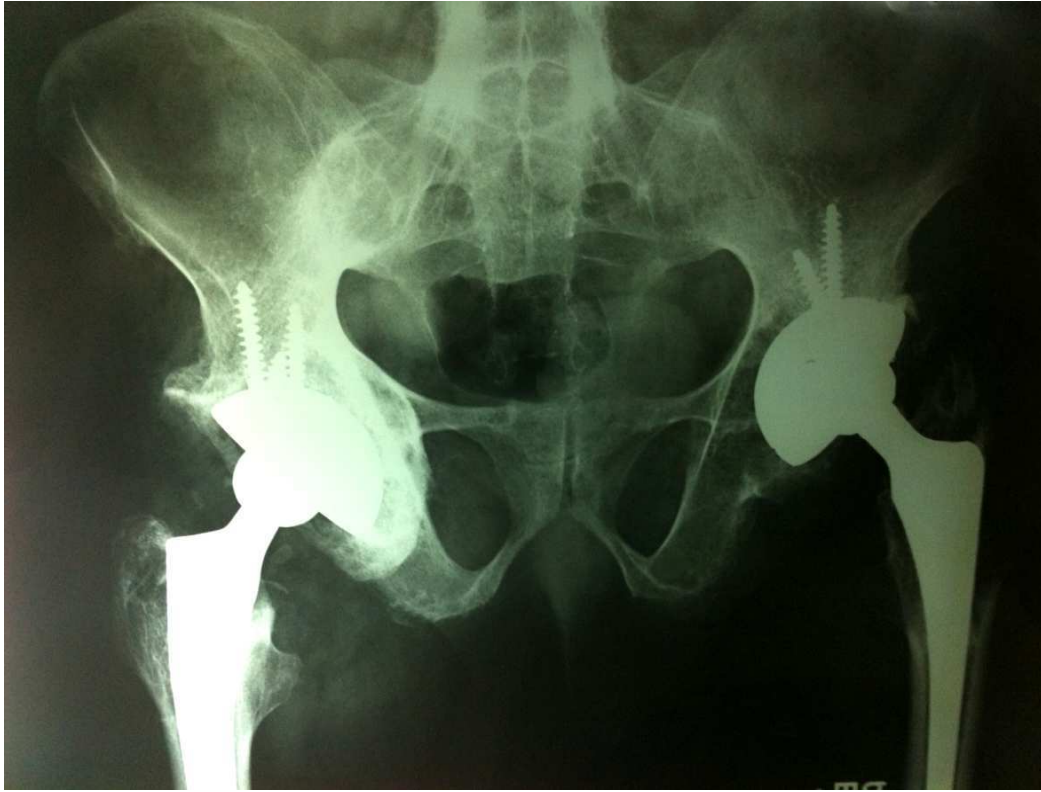



Operative pictures of Arthroplasty being done.



B/L THA done in a Pt with AVN



Same pt 03 years Post Op with no loosening.

started at three months. After 03 months they evaluated at 06 months intervals for 04 years.

All the patients showed a mean increase in Hip Score from 49 to 88, which are comparable to most of the studies.<sup>6,7</sup> Only one case showed infection which was superficial and settled with debrima, IV antibiotics according to culture. Only 01 case of dislocation was seen on left side in the epileptic patient. It turned out to be recurrent and each time following an epileptic fit. Dislocation had always been successfully reduced by close methods. Pre-operatively mean shortening was 03 cm. Posterior approach was used in all cases. There was no per/post-operative fracture, DVT, implant subsidence, Myositis ossificans, knee stiffness or NV damage and no residual shortening. There was a learning curve with positioning of acetabulum which was more vertical in the beginning but improved subsequently.

## Discussion

The modern total hip replacement was invented in 1962 by Sir John Charnley. His work has been one of the great triumphs of Twentieth Century surgery.<sup>2,5,8</sup> Two revolutionary features of the Charnley hip replacement were 1) the combination of metal gliding on plastic, and 2) the use of methacrylate cement to attach the artificial components to the bone. The major long-term problem with cemented hip replacements is loosening of the bond between the implant and the bone. There are two problems associated with the cement. Firstly, in time it cracks and becomes fragmented, resulting in loosening. Secondly, the body reacts to the smaller fragments, and attempts to remove them, but unfortunately in the process also removes bone adjacent to the cement particles, leaving the bone structurally weakened.<sup>9,10</sup> If the implant loosens, a **second surgery** may become necessary to reattach it. Much research is being done to try and solve the loosening problem. It is widely believed that the solution is to eliminate the cement. This has led to the development of the **Cementless Hip Replacement** in which the surface of the metal parts is porous, and looks like coral. Bone can grow into the metal pores and lock the implant into place without the use of cement. Improvement of the long – term clinical results with a reduced rate of non-septic loosening has been the major goal with non-cemented total hip replacement, which is consequently desirable in younger patients especially laborers and industrial workers.

Hip joint in contrary to Knee & other major joints of the body is more commonly involved by different pathologies such as AVN, Ankylosing Spondylitis and Congenital / developmental problems. More importantly, most of these pathologies are seen in younger age group.<sup>8,9,11</sup> These young patients definitely seek for some treatment because these hip pathologies are always more crippling to the patients as they have problems in daily, socioeconomic and sexual activities. In past and in Pakistan even today, such patients are routinely treated by traditional Girdle stone procedure and/or hip Arthrodesis. Both of this procedure has their own limitations and problems. Above all, patient is never happy to declare himself as normal active person. Non cemented THA have emerged to be best regarding outcome and patient satisfaction.<sup>11,12</sup> The only limiting factor in our society is that of financial issues which keeps the patient and surgeons opting for less desirable alternatives. We realized this problem, which is worse in industrial workers which were non-affording. With collaboration of Pakistan Bait-ul-Maal we started doing Noncemented THA free of cost to all such patients who otherwise could not afford it and at the same time analyzed the outcome so that a convincing conclusion could be made to compel surgeons and the patients for this most rewarding procedure. Along with it, all such poor but deserving patients especially laborers and other industrial workers could get the best possible treatment.

A total 53 noncemented THA were done in 50 patients of labor class and industrial workers totally free of cost with the help of PESSI. They were evaluated by Harris Hip Score which was 49 pre-operatively and improved to 88, which is desirable & comparable to most of the studies.<sup>1,8,10</sup> All the patients had limp because of the pain and shortening (mean 03 cm) which was successfully addressed with surgery. There was no sciatic nerve palsy. Only two cases had complications 1) a superficial infection which settled with debrimas and IV antibiotics. The second problem faced was of recurrent dislocation on left side in an epileptic patient. Each time the dislocation followed a fit and could be reduced under GA. Right sided hip in the same pt remained stable. There was significant improvement in activities of daily living with no pain, limp and / or shortening.

## Conclusion

All patients reported that the operation had been

worthwhile in improving the quality of their lives. 90% of patients were attending their professional duties and occupations. One remained housebound because of recurrent hip dislocation because of persistent fits, but was pain free in the hips. All except one patient were able to drive cars or could use public transport. The authors feel there is still a continuing place for the Un-cemented total hip replacement in this particular group of patients. It is hoped and anticipated that good long – term results may be achievable with increasing experience. Moreover if the society adopts such measures to accommodate such poor but deserving patients the financial barriers can be eliminated and such poor patients can become a useful member of the society if they could get the appropriate treatment. Otherwise they are dependent not only on their families but also a burden on the society.

## References

1. J. Steen Jensen, Jens B, Retpen. Scope of Noncemented Hip Arthroplasty in younger workers. *Acta Orthop. Scand.* 1987; 58: 23-26.
2. Bobyn, J. D., Pilliar, R. M., Cameron, H. U. and Weatherby, G. C. The optimum pore size for fixation of porous coated surface metal implants by the ingrowth of bone. *Clin. Orthop.* 1980; 149: 263-270.
3. Brooker, A. F. and Collier, J. P. Evidence of bone ingrowth into a porous coated prosthesis. *J. Bone Joint Surg.* 1984; 66-A: 619-620.
4. Harris, W. H. (1985). *Advanced concepts in total hip replacement.* Slack Incorporated, Thorofare. Judet, R., Siguier, M., Brumpt, B. and Judet, T. 1978.
5. Lord, G. A., Hardy, J. R. and Kummer, F. J. A non-cemented total hip prosthesis. *Clin. Orthop.* An uncemented total hip replacement: experimental study and review of 300 madreporique arthroplasties *Clin. Orthop.* 1979; 141: 2-16.
6. Harris WH, Muiroy RDJV, Maloney WJ, Burke DW, Chandler HP, Zalenski EB. Intra-operative measurement of rotational stability of femoral components of total hip arthroplasty. *Clin Orthop Rel Res* 1991; 266: 119-26.
7. Lord, G. and Bancel, P. The madriporic cement – less total hip arthroplasty. *Clin. Orthop.* 1983; 176, 137, 67-76.
8. Martin H. Meyers. Non-cemented Total Hip Arthroplasty. *J Bone Joint Surg Am.* 1988; 70: 1437.
9. A comparison of three varieties of non-cemented porous – coated hip replacement. Ray j. Haddad, Stephen d. Cook, Mark R. Brinker. January 1990; Vol. 72-B, No. 1.
10. Biedermann R, et al.: Reducing the risk of dislocation after total hip arthroplasty: the effect of orientation of the acetabular component. *J Bone Joint Surg Br* 2005; 87: 762. [PMID: 15911655]
11. Helm CS, Greenwald AS: The rationale and performance of modularity in total hip arthroplasty. *Orthopedics* 2005; 28: s1113. [PMID: 16190048]
12. Malhar N Kumar FRCS, Malcolm Swann FRCS, Uncemented total hip arthroplasty in young patients with juvenile chronic arthritis *Ann R Coll Surg Engl* 1998; 80: 203-209.