

Treatment of Unilateral Temporomandibular Joint Ankylosis with Silastic Interpositional Arthroplasty

M U AKHTAR A A SHAH I ABBAS*

Department of Oral & Maxillofacial surgery, de' Montmorency College of Dentistry, Lahore.

*Head of Oral Surgery Department Ayoub Medical College Abbottabad

Correspondence to Dr. Muhammad Usman Akhtar, Assistant Professor E mail: alateeb@hotmail.com

Background: Ankylosis is a very common condition developed mainly after damage to mandibular condyles or temporomandibular joint (TMJ) at a growing age. Different autogenous and alloplastic interpositional materials have been attempted after the resection of the ankylotic bone to achieve desirable results. This condition is relatively common in Pakistan. We treated TMJ ankylosis with alloplastic medical grade silicone "silastic" interpositional arthroplasty. Eight joints accompanied ipsilateral or contralateral coronoidectomy to achieve desirable results. **Method:** All patients were presented at Punjab Dental Hospital Lahore. Sixty-one joints with unilateral TMJ ankylosis were underwent surgery after careful examination and final radiographic confirmation. The preoperative CT scan was also performed in few patients. **Results:** The postoperative measurements of the interincisal opening with lateral and protrusive jaw movements were criteria for success of surgery. The lateral and protrusive jaw movements were assessed as excellent, good and poor. Less than 25 mm interincisal opening was considered as poor jaw opening. **Conclusion:** The overall success rate was 98.4 % with 84 % desirable interincisal jaw opening. Less than 5 % patients were observed with poor jaw opening. The immediate late complications were transient and were included oedema, weakness of a branch of the facial nerve on the operated side. Two implants were infected along with one wire in the first month of surgery and were removed under local anaesthesia without further complication.

Key words: Ankylosis, silastic, interpositional material, arthroplasty, coronoidectomy and jaw movements.

The "ankylosis" results in fusion and the "arthroplasty" constructs a new joint. The ankylosis of the temporomandibular joint is common condition in children following oro-facial trauma. The medical grade silicone has been used since many years in the management of different conditions in human beings. It has been successfully used as interpositional material during arthroplasty in the management of the temporomandibular joint (TMJ) ankylosis¹.

The arthroplasty results not only in adequate mouth opening but also re-establish jaw movements in the TMJ ankylosis patients. The important consideration in the management of this condition is to restore the dental occlusion along with the prevention of re-ankylosis during subsequent time. The silastic interpositional material prevents this possible subsequent relapse.^{1,3} Many authors recommended silastics as interpositional material in the management of temporomandibular joint ankylosis^{1,4,5}.

The temporomandibular joint ankylosis occurs frequently due to mismanaged childhood oro-facial trauma and less commonly due to infection to the joint and its surrounding structures. This results in inability to open mouth, impairment of speech, poor oral hygiene, dental caries, periodontal diseases and even facial deformities. The childhood facial bone trauma results in post-traumatic temporomandibular joint ankylosis and facial asymmetry in these patients.^{6,7}

The treatment of the condition is surgical and a number of surgical approaches have been attempted to reach the temporomandibular joint. The extent of the surgical intervention is directly dependent on the type of

ankylosis. The extra-capsular ankylosis (involving the coronoid process) needs usually ipsilateral and at times contralateral coronoidectomy to avoid the recurrence of ankylosis. The intra-capsular ankylosis may be bony or fibrous, depending upon the duration and age at the time of injury.^{2,8}

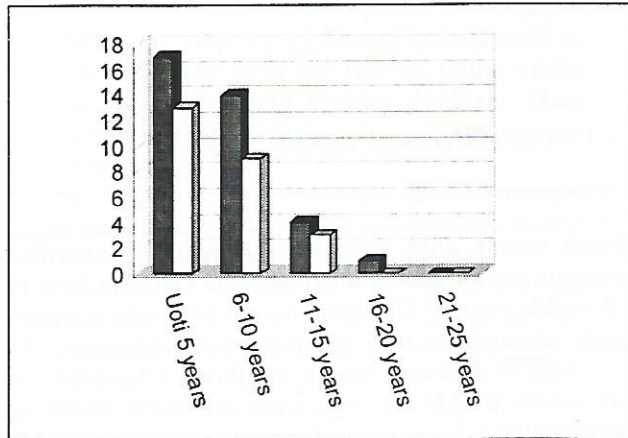
The purpose of the study is to use silastic implant as an effective and routine interpositional material in the successful treatment of TMJ ankylosis.

Materials and methods:

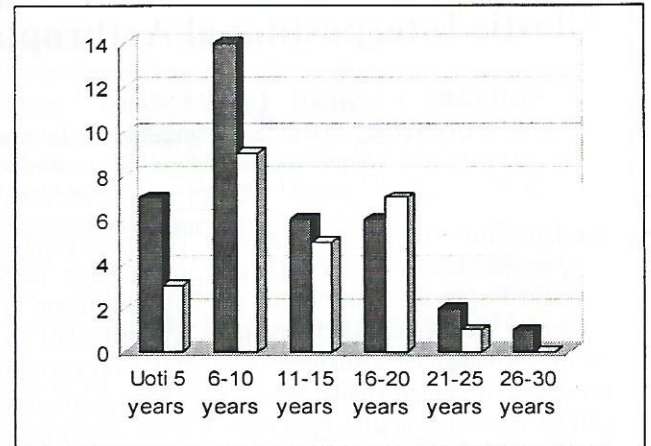
Sixty-one patients (61 joints) with unilateral TMJ ankylosis were treated over a period of three years. In eight patients (8 joints) ipsilateral and in two patients (2 joints) contralateral coronoidectomy was performed along with arthroplasty.

All patients were presented at Oral and Maxillofacial Surgery department of Punjab Dental Hospital, Lahore. The age of the patients ranged between fifteen to twenty-eight years. The etiology of the ankylosis was mostly childhood trauma. The onset of the condition and presenting age of the patients are shown in graphs I & II respectively.

The diagnosis was established on the basis of history, clinical and radiographic examination. The standard orthopantomograph (OPG) was taken for every patient and other investigations including P4 OPG, axial and coronal CT scans were additional in few patients. The vernier caliper measured the interincisal jaw opening before, during and after the arthroplasty. The photographs were also taken preoperatively, intra-operatively and postoperatively.



Graph I: Onset of the disease



Graph II: Age of presentation

The standard surgical pre-auricle incision with temporal extension of 2.5cm at about 120 degree was planned to expose the joint. The joint was released from ankylosis, creating 5mm to 8mm gap throughout. The medical grade silicon rubber (silastic) of 3mm to 4mm thickness was shaped and trimmed to secure with

surgical soft steel 25gauge wire to the lateral surface of the joint eminence, thus creating pseudo joint.

The post-operative jaw opening and closing exercises were advised, using wooden spatula along with physiotherapy for initial six months. All patients were followed-up for one year.

Table 1: Statistics Immediate and late post operative interincisal jaw opening

Interincisal opening (cm)	N		Mean	Std. Deviation
	Valid	Missing		
Immediate	61	0	2.366	0.494
Late	61	0	3.467	0.571

Immediate (cm) Interincisal Opening					Late (cm) Interincisal Opening (3 months)				
Valid	Frequency	Percent	Valid Percent	Cumulative Percent	Valid	Frequency	Percent	Valid Percent	Cumulative Percent
13	1	16	16	16	21	1	16	16	16
15	4	66	66	82	22	2	33	33	49
16	1	16	16	98	25	3	49	49	98
17	2	33	33	131	26	2	33	33	131
18	3	49	49	180	27	2	33	33	164
19	2	33	33	213	28	1	16	16	180
20	4	66	66	279	29	3	49	49	229
21	5	82	82	361	30	2	33	33	262
22	6	98	98	459	32	2	33	33	295
23	2	33	33	492	33	2	33	33	328
24	4	66	66	558	34	2	33	33	361
25	4	66	66	624	35	7	112	112	473
26	2	33	33	657	36	4	66	66	539
27	6	98	98	755	37	3	49	49	588
28	2	33	33	788	38	8	128	128	716
29	4	66	66	854	39	7	112	112	828
30	5	82	82	936	40	2	33	33	861
31	4	66	66	100	41	5	82	82	943
-	-	-	-	-	42	2	33	33	976
-	-	-	-	-	43	1	16	16	100
total	61	100	100	100	total	61	100	100	100

Results:

The interpositional arthroplasty was performed on sixty-one joints. The medical grade medium hard silicon was used as an interpositional material. The success rate was

98.4%. The postoperative interincisal jaw opening range and lateral / protrusive jaw movements were set as criteria of the surgical success. 86% patients had

adequate immediate postoperative jaw opening whereas late opening was excellent (≥ 35 mm) in 64% patients. However, only 5% patients had less than 25mm interincisal jaw opening as shown in table I.

The immediate lateral jaw movements were excellent on the normal side whereas, the movements were good on the effected side. These movements were relatively poor in contralateral or ipsilateral coronoidectomy patients but they were improved to good during follow up. The late protrusive jaw movements were excellent in all the patients.

Discussion:

TMJ ankylosis in Pakistan is exclusively because of ignored or mismanaged trauma to the joints in growing age. The socioeconomic status of the patients and unavailability of trained specialists have major role in delaying treatment or until facial disfigurement appears.

Temporomandibular joint ankylosis requires aggressive surgical intervention without compromise. Failure to alleviate the ankylosis may result in speech impairment, difficulty in mastication, poor oral hygiene, rampant caries, facial and mandibular growth disturbances in children and acute respiratory compromise⁹. The bony ankylosis is usually confined to the intracapsular condyles, glenoid fossa and articular eminence. However, the extracapsular bone formation may be extensive enough to cause ankylosis of the coronoid process, the zygomatic arch, the lateral pterygoid plates, the external auditory canal and the skull base¹⁰.

Many authors have described steps for successful management of this condition^{1, 11, 12}. The autogenous and alloplastic materials have been utilized for the successful management TMJ ankylosis. The costochondral graft, temporal fascia, temporal muscle, ear cartilage, silastic, proplast and metals have been used as the interpositional materials in TMJ arthroplasty^{3, 5, 13-18}.

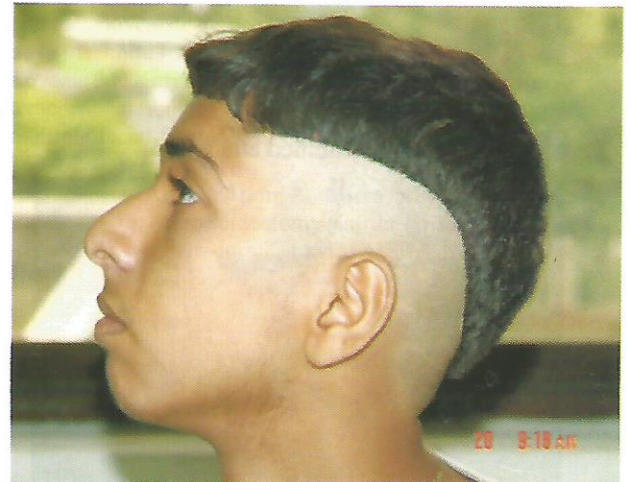
We used medical grade silicone rubber (silastic) as alloplastic interpositional material in arthroplasty patients to protect them from the most commonly occurring complication of re-ankylosis. It was observed that even after the removal of silastic implant, the fibrous capsule formed around the implant is highly elastic in nature and the jaw opening movements were not disturbed during follow up^{4, 5, 18-22}. All patients had been recommended frequent postoperative wooden spatula exercises and physiotherapy for initial 6 months.

It is recommended that the TMJ ankylosis should be dealt with aggressive surgical approach using silastic interpositional material and at times ipsilateral or contralateral coronoidectomy, followed by early mobilization of the joint. It results not only in satisfactory mouth opening and jaw function, but also ensures in reduction of subsequent re-ankylosis.

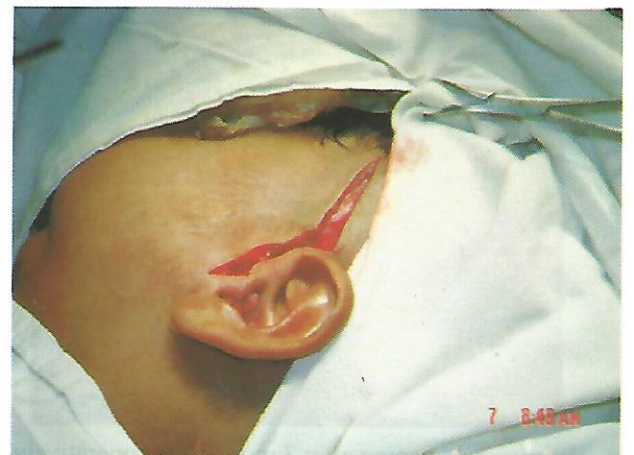The postoperative complications included transient weakness of facial nerve branches in 9 patients. Three patients developed infection during first month of surgery due to wire and silastic implant. This wire and two implants were removed under local anesthesia without subsequent reduction of jaw opening during follow-up. Only one young patient developed re-ankylosis within a year with CT scan evidence of displacement of silastic implant.

Conclusion:

Silicone material of medical grade is being frequently used in different medical specialties and dentistry. Various autogenous and alloplastic materials have been tried for the successful management of temporomandibular ankylosis. Among alloplastic materials, silicone is cheap, easy to manipulate and place as interpositional material. The success rate of this interpositional material has been found excellent during the management of TMJ ankylosis.

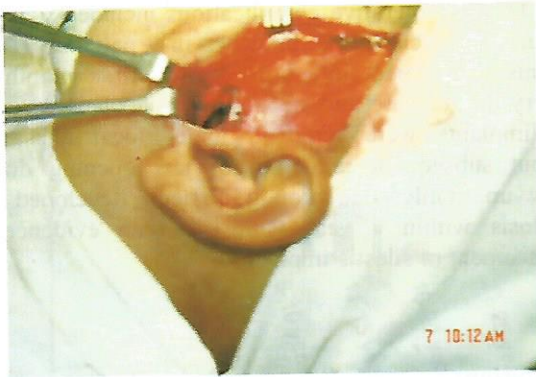


Pre-operative lateral view

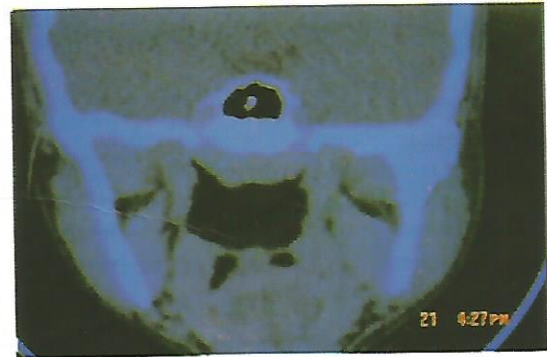

Incision design

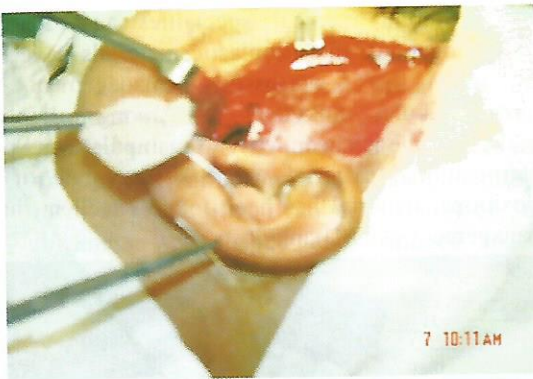
Treatment of Unilateral Temporomandibular Joint Ankylosis with Silastic Interpositional Arthroplasty



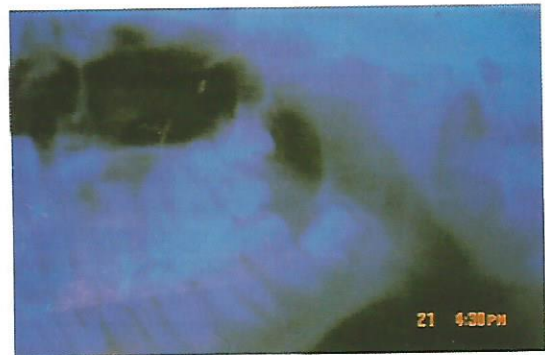
Gap created (8mm)



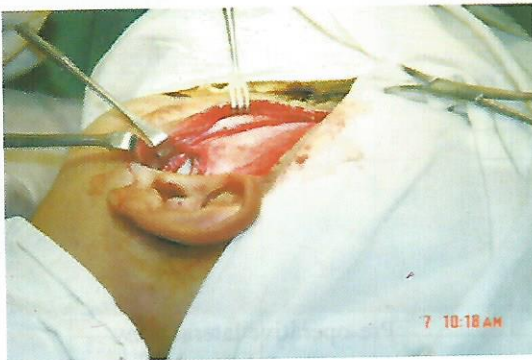CT scan of left joint ankylosis



Silastic trimmed and wired



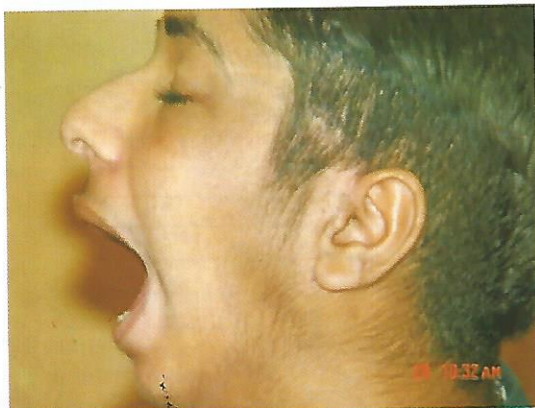OPG of left TJ joint ankylosis



Silastic wired in position



3-D CT scan of left TM joint ankylosis



Interincisal opening after 3 months post operatively



Postoperative OPG with wire and silastic in position

References:

1. Walker RV. Arthroplasty of the ankylosis temporomandibular joint. *AM Surg.* 1958; 24: (6).
2. Gallagher MD, Wolford LM. Comparison of silastic and proplast implants in the TMJ after condylectomy for osteoarthritis. *J Oral Max Fac Surgery* 1982; 40: 627-630.
3. Akhtar MU, Ali K, Arain A, Mirza YB, Chaudhry Z. Management of temporomandibular joint ankylosis: a long term comparative study. *J Phy Surg Pak* 2001; 2(11): 84-87.
4. Swanson AB. Finger joint replacement by silicone rubber implants and its concept of implant fixation by encapsulation. *Ann Rheum Dis* 1969; 28: 47-55.
5. Kreutziger KL, Mahan PE. Temporomandibular degenerative joint diseases: diagnostic procedure and comprehensive management. *J Oral Surg* 1975; 40: 297.
6. Posnick JC, Goldstein JA. Surgical management of the temporomandibular joint in pediatric population. *J Plastic Reconst Surg* 1993; 91: 5791-7.
7. Gassner R, Tuli T, Hach O, Rudisch A, Ulmer H. Craniomaxillofacial trauma: a 10 year review of 9543 cases with 21067 injuries. *J Craniomaxillofac Surg* 2003; 31(1): 51-61.
8. Iido S, Matsuya T. Pediatric maxillofacial fracture: their etiological characters and fracture patterns. *J Craniomaxillofac Surg* 2002; 30 (4):237-41.
9. Molla MR, Shrestha KR. An analytic study of surgical management of temporomandibular joint ankylosis: an experience in Bangladesh. *Banglad Med Res Coune Bull* 1996; 22: 43-50
10. Mofty EL. Ankylosis of temporomandibular joint. *J Oral Surg* 1972; 33: 650-666.
11. Jeffrey J, Mose, Henry HLO. Fibrous Ankylosis of the Temporomandibular Joint. *J Orofacial Pain* 1995; 9: 38-41.
12. Kaban LB, Perott DH, Fisher K. A Protocol for Management of Temporomandibular Joint Ankylosis. *J Oral Max Fac Surg* 1990; 48: 1145-1151.
13. Adekeye EO. Ankylosis of the mandible: analysis of 76 cases. *J Oral Maxillofac Surg* 1983; 41: 442-45.
14. Silver MCM, Motamed M, Carlotti WE. Temporomandibular joint with the use of vitallium condylar prosthesis: report of three cases. *J Oral Surg* 1977; 35: 909-11.
15. Zhou L. Auricular cartilage graft interposition after temporomandibular joint ankylosis surgery in children. *J Oral Max Fac Surg* 2002; 60: 985-87.
16. Saeed NR, Kent JN. A retrospective study of the costochondral graft in TMJ reconstruction. *Oral Max Fac Surg* 2003; 32: 606-09.
17. Loon JP, de Bont LGM, Stegenga B, Spijkervet FKL, Verkerke GJ. Groningen temporomandibular joint prosthesis: development and first clinical application. *J Oral Max Fac Surg.* 2002; 31: 44-52
18. Steinhauser EW. The treatment of ankylosis in children. *J Oral Surg* 1973; 2: 129.
19. Kiersch TA. Proplast Teflon graft for TMJ surgery. VIII international conference on oral surgery. Berlin, West Germany, June 1983.
20. Verneuil A. De la creation d'une fausse articulation par section of resection partielle de l'os maxillaire infericure, comme moyen de remedier al''nkylose vraie ou fausse de la machoire infereure. *Arch Gen Med* 1872; 284-316.
21. Toyama M, Kurita K, Koga K, Ogi N. Ankylosis of the temporomandibular joint developing shortly after multiple facial fractures. *J Oral Max Fac Surg* 2003; 32: 360-62.
22. Akhtar MU, Ali K, Arain A, Mirza YB, Chaudhry Z. Rationale for coronoidectomy in the management of temporomandibular joint ankylosis. *J Phy Surg Pak* 2001; 1(11): 12-14.