

Case Report:

Clear Cell Sarcoma (Malignant Melanoma of Soft Part): A Rare Soft Tissue Sarcoma

M ABDULLAH

THQ Hospital Bhalwal, Distt. Sargodha

Correspondence to Dr. Muhammad Abdullah, Surgical Specialist. E-mail: khokhar7@hotmail.com

Clear cell sarcoma is a rare malignant neoplasm usually presenting as soft tissue mass in foot of young adult. Ultrastructural studies reveal neuroectodermal origin with melanocytic differentiation. Thus it is considered as malignant melanoma of soft parts. Though the prognosis is apparently better as compared to the conventional melanoma, local recurrences and metastases are frequently seen. Large tumor size and extent of necrosis are factors for poor prognosis. A case of clear cell sarcoma with classical presentation is reported.

Key words: Clear cell sarcoma, soft tissue sarcoma, malignant melanoma.

Soft tissue sarcomas are a large and heterogeneous group of neoplasms. Traditionally, these tumors have been classified according to histogenic features. However, histomorphologic, immunohistochemical and experimental data suggest that most, if not all, sarcomas arise from primitive multipotential mesenchymal cells, which in the course of neoplastic transformation differentiate along one or more lines¹.

They account for approximately 0.1% of all cancers, but in children about 6% of tumors are soft tissue sarcomas². Clear cell sarcoma of tendons and aponeuroses is a rare and histologically distinctive malignant soft tissue tumour³. Many authors believe that these tumors are neuroectodermal in origin and are derived from deep melanocytic cells associated with tendons and aponeuroses⁴. The most common site is in the foot, often near the Achilles tendon or plantar aponeurosis⁵.

Case Report

A 17 year old male presented with a swelling on the medial aspect of right ankle. It was there for six months causing occasional pain and steadily increasing in size. There were no other symptoms. Examination revealed a firm, circular 3x3cm, non-tender, mobile swelling placed between the right medial malleolas and the Achilles tendon. Skin over the swelling was normal and mobile. Ankle movements were within normal range. No popliteal or inguinal lymph nodes were palpable. X-rays of foot showed no bony lesion. Excision of the swelling was carried out. Per-operatively the swelling was grayish white, present below the tributaries of saphenous vein and the deep fascia. Posteriorly it was tethered to posterior tibial vessels. Swelling was separated all around; complete excision was done with adequate skin cover [Fig.1]. Microscopic section showed a cellular tumor consisting of sheets and groups of tumor cells with moderate nuclear pleomorphism, prominent nucleoli and high N/C ratio in a background of fibrocollagenous and vascular stroma. Scattered giant cells were noted with infrequent mitosis. Focally prominent intracellular golden brown melanin like

pigment was noted. Features were consistent with malignant melanoma. The patient made an uneventful recovery. He is undergoing regular follow-up.

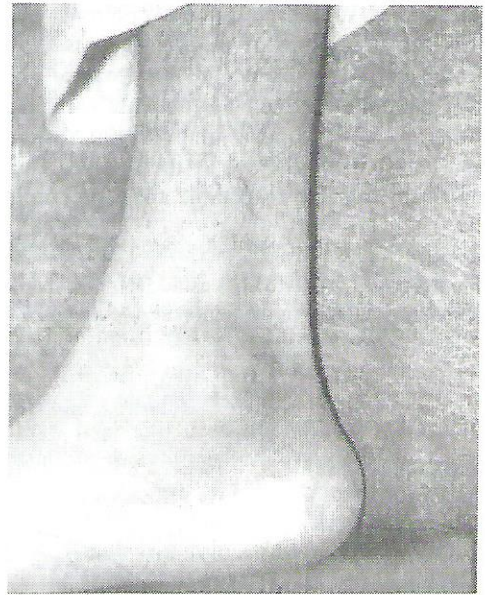


Figure 1: Post-operative photograph showing the area of lesion

Discussion

Clear cell sarcoma is a rare soft tissue neoplasm, arising most commonly in the tendons and aponeuroses of young adults⁶. Though foot is the most common site, the neoplasm has been described in ankle, knee, thigh and other sites including penis⁷. The largest study is of thirty-five cases of clear cell sarcoma, which were studied to determine the clinical or morphologic features that are important in predicting prognosis⁸. Clear cell sarcoma usually presents as painless, gradually enlarging mass in young adult as seen in our case. Grossly the tumor is usually firm, well-circumscribed, grayish white and has a

gritty sensation on cutting⁹. This sarcoma is characterized by small clusters of polygonal to spindle cells featuring clear to slightly basophilic cytoplasm and vesicular nuclei with prominent nucleoli. The clusters are separated by delicate fibrous septa. In a deletion, clear cell sarcoma has low mitotic activity, little or no necrosis and mild nuclear pleomorphism⁸. Presence of multinucleated giant cells and abundant iron deposits have been described⁹. Clear cell sarcoma of soft parts can be diagnosed readily by FNAC alone without resorting to incisional biopsy¹⁰. In many cases the tumor cells contain cytoplasmic melanin^{4,11}. The diagnosis can be made with immunocytochemical confirmation of HMB-45 or S-100 protein expression, cytogenetic demonstration of the^{12,22} translocation or electron microscopic studies demonstrating melanosomes¹². It is interesting that the same gene is also affected in Ewing's sarcoma, PNET and intra- abdominal desmoplastic small-round cell tumor⁹. The prognosis is relatively poor and local recurrences are quite frequent. Unlike most sarcomas, spread to regional lymph node is common, occurring in 30% cases⁵. Metastatic spread has been reported in around 65% of patients and large tumor size along with degree of necrosis are predictors of poor prognosis^{8,13}. Complete surgical resection represents the main stay of treatment and possibly the only treatment for patients with small tumors. Radiotherapy may control microscopic residual disease after surgery. Chemotherapy is ineffective. The prognosis is unfavorable for non-resectable and large tumors¹⁴.

References

1. Shidham VB, Acker SM, Vesole DH, Hackbarth D. Benign and malignant soft tissue tumors. *E Medicine* 2003;2
2. Burdette WJ. *Cancer: Etiology, treatment and diagnosis*. McGraw-Hill. 1998: 205.
3. Ezinger FM. Clear cell sarcoma of tendons and aponeurosis. An analysis of 21 cases. *Cancer* 1985; 18: 1163- 74.
4. Chung EB, Enzinger FM. Malignant melanoma of soft parts- A reassessment of clear cell sarcoma. *Am J Surg Pathol* 1983; 7: 405-13.
5. Hough AJ Jr. *Joints: in anderson's pathology*. 10th edition. Mosby. 1996; 2: 2643.
6. Deenik W, Mooi WJ, Rutgers EJ, Peterse JL et al. Clear cell sarcoma (malignant melanoma) of soft parts: A clinicopathologic study of 30 cases. *Cancer* 1999 Sept 15; 86 (6): 969-75.
7. Saw D, Tse Ch, Chan J. et al. Clear cell sarcoma of the penis. *Hum Pathol* 1986; 17: 423- 5.
8. Lucas DR, Nascimento Ag, Sim FH. Clear cell sarcoma of soft tissues. Mayo Clinic experience with 35 cases. *Am J Surg Pathol* 1992 Dec; 16 (12): 1197- 204.
9. Rosai Juan. *Soft tissues: in Ackerman's surgical pathology*. 8th edition. Mosby 1996; 2: 2099- 2101.
10. Tong TR, Chow TC, Chan OW. et al. Clear cell sarcoma diagnosis by fine needle aspiration: cytologic, histologic and ultrastructural features: potential pitfalls: and literature review. *Diagn Cytopathol* 2002 Mar ; 26 (3): 174- 80.
11. Bearman RM, Neo J, Kempson RL. Clear cell sarcoma with melanin pigment. *Cancer* 1975; 36: 977- 84.
12. Creager AJ, Pitman MB, Geisinger KR. Cytologic features of clear cell sarcoma (malignant melanoma) of soft parts. A study of fine needle aspirates and exfoliative specimens. *Am J Clin Pathol* 2002; 117: 217-224.
13. Sara AS, Evans HL, Benjamin RS. Malignant melanoma of soft parts (clear cell sarcoma) – A study of 17 cases with emphasis on prognostic factors. *Cancer* 1990; 65: 367-74.
14. Ferrari A, Casanova M, Bisogno G. et al. Clear cell sarcoma of tendons and aponeurosis in pediatric patients: a report from Italian and German Soft Tissue Sarcoma Cooperative Group. *Cancer* 2002 Jun 15; 94 (12): 3269- 76.

