

Morphological Changes Produced by Aminoglycoside Induced Nephrotoxicity - An Experimental Study

ZAHID M., KAMAL F., QAMAR M.Z.

BHATTI S.A., INSARI N.I.

Department of Pharmacology, King Edward Medical University, Lahore

Department of Pathology & Pharmacology, PGMI, Lahore

Correspondence: Dr. Muhammad Zahid, Assistant Professor, Department of Pharmacology, Lahore

Aminoglycosides are very commonly used antibiotics to treat life threatening infections because they display many highly desirable properties. The major limitations to their uses being their adverse effects, such as nephrotoxicity. The purpose of present study was to see and compare the morphological changes in kidneys caused by the use of aminoglycosides in animal model. The study was conducted on eighteen male local breed rabbits weighing 1 to 1.75 Kg and age ranging from 8 to 10 months for the period of 20 days. These animals were divided in three groups at random with 6 animals in each group. Two groups (G & A) were given Aminoglycosides namely Gentamicin and Amikacin in doses 10 times larger than corresponding human clinical dose to produce experimental nephrotoxicity while third group being control was injected only isotonic saline. After sacrificing the animals the histological examination of the kidneys revealed morphological changes mainly involving the renal tubules which show patchy necrosis along with hyaline and granular casts in their lumina. Dropped out tubular cells were also seen in the lumina of some of the renal tubules. The lining epithelial cells show hydropic changes with cytoplasmic vacuoles at some areas while regeneration at others. The glomerulae showed mild hypercellularity and congestion in most of the sections. The renal interstitium showed infiltration by polymorphonuclear leukocytes, lymphocytes, plasma cells and macrophages while the renal vascular changes were limited to focal congestion only but the changes were more pronounced in gentamicin treated group. It is concluded that Aminoglycosides cause nephrotoxicity by producing damaging effects on renal tubules especially at higher doses, so their administration should carefully be monitored for early detection and prevention of toxic effects.

Keywords: Aminoglycoside, Nephrotoxicity, Hypercellularity, Congestion, Regeneration, Necrosis.

Aminoglycosides continue to represent highly effective antimicrobial agents since their introduction about more than 50 years ago¹ and despite the introduction of highly potent, wide spectrum antibiotics, aminoglycosides are still considered to be very important against many life threatening infections especially against gram negative bacterial infections.²⁻⁴ They are very commonly used antibiotics world wide because of certain properties as rapid concentration dependent bactericidal effects, clinical effectiveness, a low rate of true resistance, synergism with other beta lactum antibiotics and low cost of therapy^{5,6}. However their efficacy continue to be counterbalanced by significant toxicity especially nephrotoxicity which bring about kidney damage by a direct dose dependant mechanism.^{7,8}

The purpose of present study was to examine and compare the morphological changes in kidneys caused by the use of two important aminoglycosides (gentamicin & amikacin) in animal model.

Materials and methods

The study was conducted on eighteen male local breed rabbits weighing 1 to 1.75 Kg and age ranging from 8 to 10 months. They were fed on commercial diet with free access to water. These animals were divided in three groups at random with 6 animals in each group. Two groups (G & A)

were given Aminoglycosides namely Gentamicin and Amikacin respectively in doses 10 times larger than corresponding human clinical dose to produce experimental nephrotoxicity.⁹ Group G and A were administered commercial preparation of gentamicin and amikacin, 60 and 150 mg/kg bw respectfully daily for 20 days intramuscularly in two equally divided doses while third group C (control) was given isotonic solution intramuscularly for the same study period. All animals were sacrificed within 24 hours after the last dose of the drugs. The abdomen was opened and both the kidneys were dissected out. They were examined grossly and cut sagittally, capsules were striped carefully and specimen were immersed in 10% formalin for overnight fixation. Next day three sections were taken from each kidney, including cortex and medulla, and one section was cut from pelvis. These tissues were processed in automatic tissue processor. Paraffin blocks were prepared, cut at rotary type of microtome and stained by Haematoxylin & Eosin. The slides were studied in Histopathology section of the department by ordinary light microscope. Histological findings in experimental animals were compared with control group.

Results

The histological sections of kidneys of the rabbits which were administered with heavy doses of Aminoglycosides

revealed morphological changes mainly involving the renal tubules which showed patchy necrosis along with hyaline and granular casts in their lumina. The extent of necrosis was more in gentamicin treated animals than amikacin group (microphotographs 2-5 for comparison). Dropped out tubular cells were also seen in the lumina of some of the renal tubules. The lining epithelial cells show hydropic changes with cytoplasmic vacuoles at some areas while re-

Morphological changes in gentamicin and amikacin treated groups.

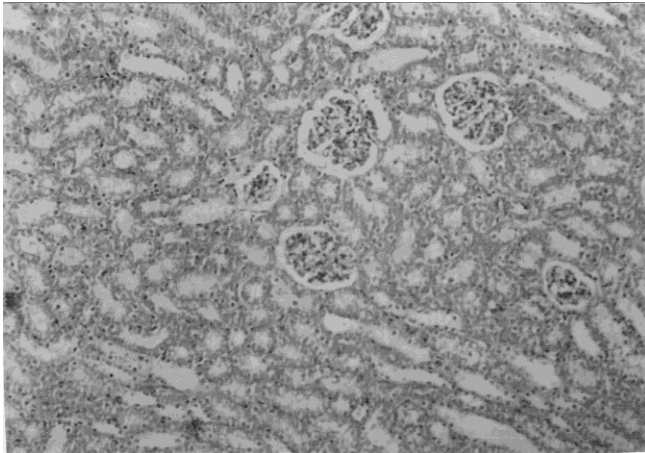


Fig. 1: (Control group). Showing normal morphology H and E 500 ×.

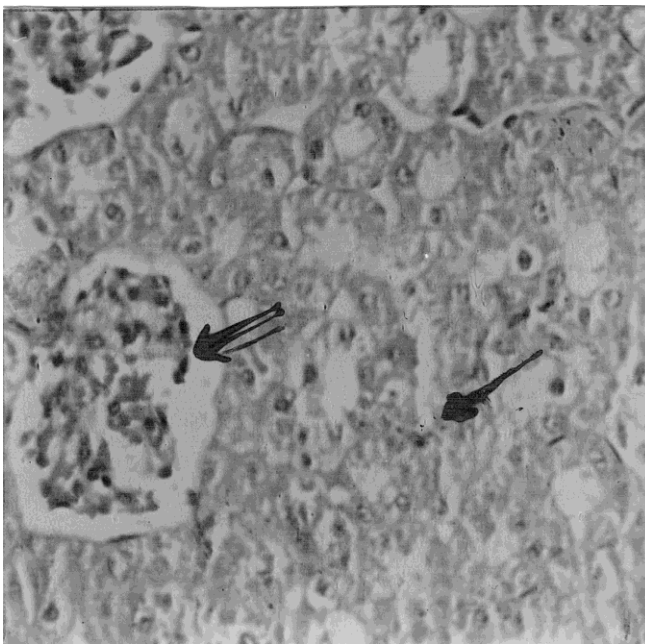


Fig. 2: (Gentamicin treated group) showing tubular necrosis and interstitial inflammation (single arrow) and congestion and hypercellularity (double arrow) H and E 500 ×.

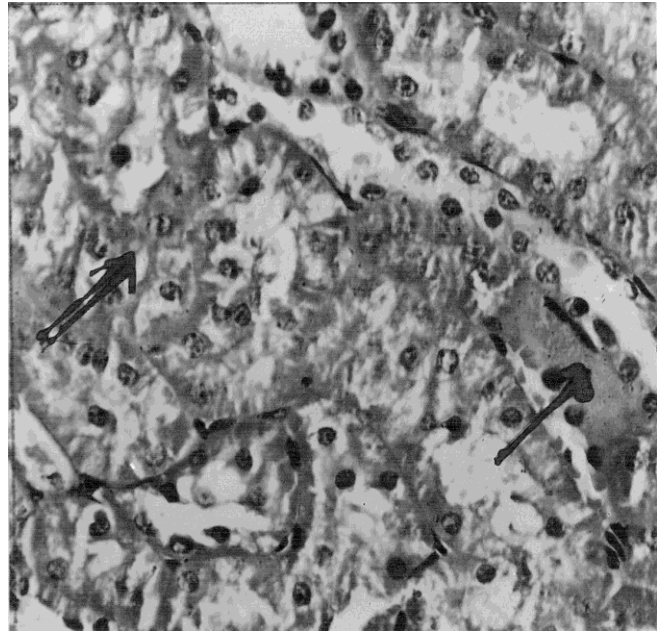


Fig. 3: (Gentamicin treated group) showing hyaline casts in dilated renal tubule (single arrow) and vascular degeneration of tubular lining epithelium (double arrow). H and E 500 ×.

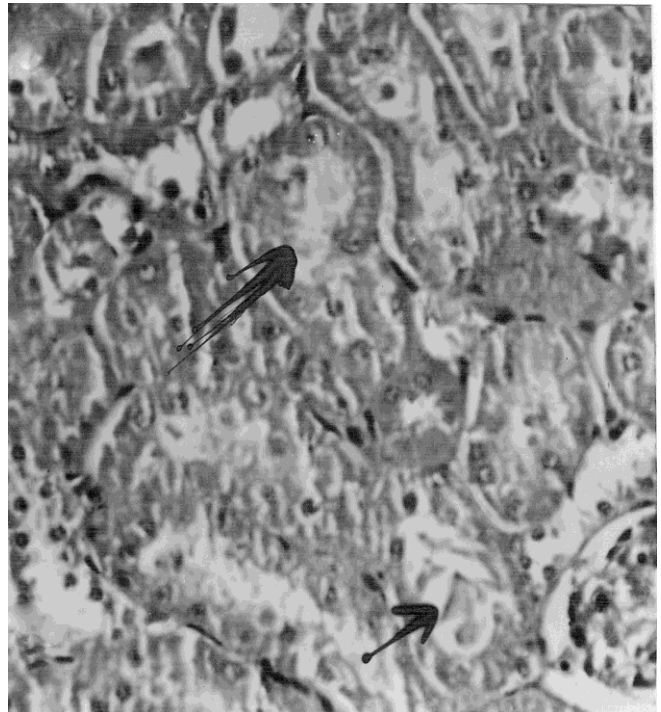


Fig. 4: (Amikacin treated group), showing similar types of changes as in gentamicin treated group but lesser in magnitude. H and E 500 ×.

generation at others. The regenerating cells were recognized by enlarged nuclei. The changes in glomerulae were not

very marked. The glomerulae showed mild hypercellularity and congestion in most of the sections. The renal interstitium showed infiltration by polymorphonuclear leukocytes, lymphocytes, plasma cells and macrophages particularly around the necrotic tubules. The renal vascular changes were limited to focal congestion only. The sections from control group showed normal morphology (microphotograph-1).

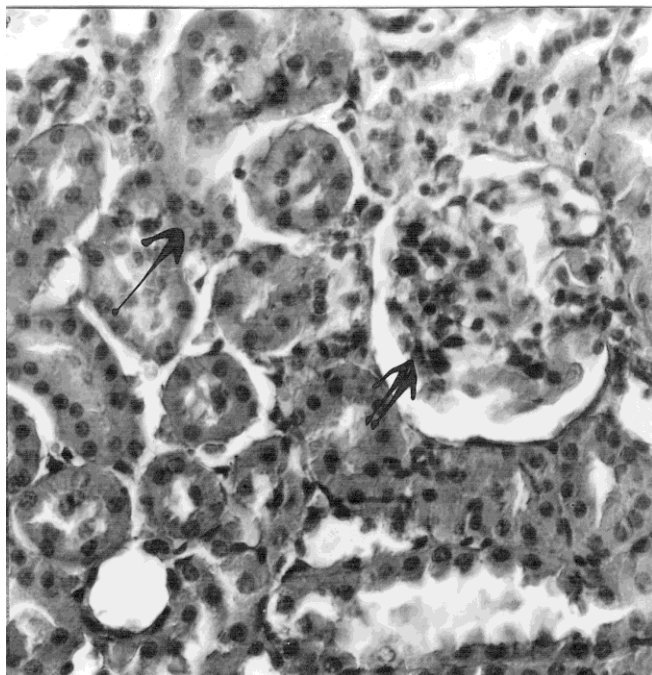


Fig. 5: (Amikacin treated group), showing similar types of changes as in gentamicin treated group but lesser in magnitude. H and E 500 \times .

Discussion

Over the years many classes of highly potent and wide spectrum antibiotics have been introduced but still aminoglycosides are mainstay to treat life threatening infections because they display many highly desirable properties, but, such an extensive and common use is still thought to be limited in the face of their usefulness; the major limitations to their uses being their adverse effects, such as nephrotoxicity, bringing about kidney damage via a direct dose dependant mechanism.^{7,10} This study was carried out to examine the morphology of kidney in experimental animals after administering the high doses of two aminoglycosides. In our study the most common morphological effects occurred on the kidney tubules showing patchy necrosis. Some of the tubules also showed hyaline and granular casts while others exhibited dropped out tubular epithelial cells in their lumina. At some sites the tubular epithelial cells also showed hydropic change with cytoplasmic vacuolization. These findings are almost consistent with many other studies.¹¹⁻¹⁴ Another change seen in some of our cases was tubular regeneration

activity recognized by enlargement of lining epithelial cell nuclei, prominent nucleoli and basophilic cytoplasm. Several other studies on renal effects of aminoglycoside reveal almost similar results.^{12,14,15,16} In our study the tubular necrosis was more marked in those administrated with gentamicin than amikcin. This attributed to the fact that toxic potential of individual aminoglycoside agents is directly related to its ability to bind and disrupt plasma membrane. Considering the glomerular changes, in our study many of the glomerulae show focal hypercellularity and congestion while no glomerular change was described in other studies as the toxic effects of aminoglycosides are mainly on tubules.^{15,16} In almost all our cases renal interstitial tissue revealed infiltration by lymphocytes, plasma cells and macrophages. Similar results were also described by Lee and Michael (1985) and Vecchi et al (1988). Our findings are also similar to the findings of Lerma et al (2006). Vascular changes in the kidneys were limited to mild congestion only while Vecchi et al described focal thrombosis of the vessels along with congestion.¹³

Conclusion

It is concluded that aminoglycosides can produce nephrotoxicity via dose dependant mechanism. The morphological changes observed with amikacin were lesser than gentamicin, so the administration of aminoglycosides should not only be carefully monitored for early detection and prevention of toxic effects but risk factors and / or concomitant administration of other nephrotoxic agents should also be avoided.

We are deeply indebted to Ministry of Health (Central Research Board) Government of Pakistan, Islamabad for its financial assistance, technical guidance and valuable suggestions.

References

1. Swan RA, Kaplan-Machlis B. Therapeutic use of vitamin E in prevention of atherosclerosis. *Altern Med Rev* 1999; 4 (6): 414-23.
2. Wersal J. Ototoxic antibiotics: a review. *Acta Otolaryngol* 1995; 519: 26-29.
3. Schact J. Aminoglycoside toxicity : Prevention in sight? *Otolaryngol Head Neck Surgery* 1998; 118 (5): 674-77.
4. Mingeot-Leclercq MP, Tulkens PM. Aminoglycoside Nephrotoxicity. *Antimicrob Agents Chemother* 1999; 43: 1003-12.
5. Begg EJ, Barclay ML. Aminoglycosides – 50 years. *Br J Clin Pharmacol* 1995; 39 (6): 597-603.
6. Edson RS, Terrel CL. The Aminoglycosides. *Mayo Clin Proc* 1999; 74: 519-28.
7. Khoory BJ, Fanos V, Dall AA, Cataldi L. Aminoglycosides, risk factors and neonatal kidney. *Pediatr Med Chir* 1996; 18: 495-99.

8. Rougier F, Claude D, Maurin M, Maire P. Aminoglycoside Nephrotoxicity. *Curr Drug Targets Infect Disord* 2004; 4: 153-62.
9. Tulken PM. Nephrotoxicity of aminoglycoside antibiotics. *Toxicol Letters* 1989; 46:107-10.
10. Henley CM, Ryback LP. Developmental ototoxicity. *Otolaryngol Clin North Am* 1993; 26 (5): 857-71.
11. Gilbert DN, Wood CA, Kohlhepp SJ. et al. Polyaspartic acid prevents Experimental Aminoglycoside nephrotoxicity. *The Journal of Infectious Diseases* 1989; 159: 945-953.
12. Beauchamp D, Leuvrent G, Abid MS, Kishore BK, Tulkens M. Protection against gentamicin induced early renal alterations (Phospholipidosis and increased DNA synthesis) by co-administration of poly-L-aspartic acid. *J Pharmacol Exp Ther* 1990; 255 (2): 858-66.
13. Vecchi ED, Lubatti L, Beretta C, et al. Protection from renal ischemia reperfusion injury by the 2-methylaminochroman U83836E. *Kidney International* 1998; 54: 857-863.
14. Lee SM and Michael UF. The protective effect of Nitrendipine on Gentamicin Acute Renal Failure in Rats. *Experimental and Molecular Pathology* 1985; 43: 107-114.
15. Lerma E, Kelly MB, and Argraharka M. Acute Tubular Necrosis. In *Medicine of Web Med Dec.* 2006.
16. Berns JS, Tokars JI. Preventing bacterial infection and antimicrobial resistance in dialysis patients. *Am J Kidney Diseases* 2002; 40 (5): 886-98.