

Clinical and Ultrasound Correlation in First Trimester Abortion

J IQBAL F NAUSHEEN A T KHAN S SHEIKH

Department of Obstetrics & Gynaecology, Jinnah Hospital/Allam Iqbal Medical College, Lahore
Correspondence to Dr. Javed Iqbal, Senior Registrar E. mail: dawood@hotmai.com

Aims and Objectives of Study: To compare the diagnostic accuracy of clinical and ultrasound evaluation in first trimester abortions and assess the impact of ultrasound on patient management.

Study Design: Non-interventional comparative study conducted on 100 patients, selected on simple random basis from Gynae Outpatient Department. **Study place:** Department of Obstetrics & Gynaecology, Allama Iqbal Medical College and Jinnah Hospital, Lahore **Materials and Methods:** All the patients with symptoms of first trimester abortion were evaluated clinically and by ultrasound to formulate a diagnostic and management plan. **Main Outcome Measures:** Both Modalities were compared for diagnostic accuracy, positive and negative correlation in different types of abortions. **Results:** 34% of the patients were at 10 weeks of gestation, 28% were unsure of dates, 17% were at 11 weeks of gestation, 13% of the patients were at 9 weeks of gestation, 5% were at 6 weeks while 3% were at 7 weeks of gestation. Clinical diagnosis was made in 42% of cases; in 39% definite diagnosis was possible with combined clinical and ultrasound evaluation while in 19% no diagnosis was established with either modality. In 89% of the cases the diagnosis was made on single ultrasound scan, while 11% required a repeat scan. Correlation between two modalities was present in 81% of the cases. Positive correlation was obtained in 59% and negative correlation was seen in 22%. The correlation was not possible in 19% of cases. **Conclusion:** Ultrasonography is an essential tool in diagnosis of early pregnancy failures especially where clinical evaluation is inconclusive.

Keywords: Abortion, ultrasonography, first-trimester pregnancy.

Miscarriage is the most common complication of pregnancy with an overall incidence of approximately 15–20% among clinically recognized pregnancies.^{1, 2} When early pregnancy loss occurs it can be due to a number of embryonic and maternal factors.

Ultrasound brought a new dimension to obstetrics and gynaecological diagnosis. Its use is widespread. It is safe, dependable, simple, non-invasive, cost effective and results are readily available. If undertaken at an appropriate time and by well-trained staff, it can provide accurate knowledge about gestational age, fetal growth and fetal normality.^{3,4}

With the advent of sensitive home pregnancy test, the early pregnancy diagnosis is now within the reach of the patients. Ultrasonographic examination can detect a viable pregnancy as early as 5 weeks of gestation. Ultrasonographic examination in the first trimester should preferably be performed with the transvaginal imaging¹.

In most cases sonographic criteria alone can distinguish viable from non-viable gestation at a single examination however, ultrasound findings are unreliable at 3-4 weeks of gestation and may need reappraisal after 3-4 days⁵.

In this study clinical evaluation was compared with ultrasonographic findings in the diagnosis of first trimester spontaneous miscarriages. We studied the impact of ultrasonography on the final diagnosis and management plan^{5,6}.

Patients and methods

One hundred patients with history of symptoms of spontaneous first trimester abortion (<13 weeks) were selected from gynae outpatient department at random. All

the patients underwent clinical as well as ultrasound evaluation for the diagnosis and management. Both modalities were compared for diagnostic accuracy, positive and negative correlation in different types of abortions. The patients with induced and/or septic abortion and in whom pregnancy was not confirmed were excluded from the study.

Information regarding age, parity, menstrual history and previous miscarriages was collected on a pre-designed proforma. After general, physical and systemic examination, all the patients underwent pelvic examination. The Sonologist made evaluation in the emergency department by transabdominal as well as transvaginal scans. In doubtful cases a repeat scan was advised after 3-4 days. Serial scans were performed in few for follow-up. In each patient, correlation was established between the two modalities of diagnosis. If the same diagnosis was obtained by two methods, it was considered to be positive correlation and if different diagnosis was obtained, it was considered to be a negative correlation.

Results

The patients selected for the study were between the age group of 17-40 years with mean age of 26.6 years. The mean duration of marriage was 6 years. The parity of the patients was from nulliparous to eight. Patients with previous history of miscarriages were also included (range 0-7) (Table I).

72% of the patients were sure about their dates and 28% were unsure. 34% of the patients were at 10 weeks of gestation, 17% at 11 weeks, 13% at 9 weeks of gestation, 5% at 6 weeks and 3% at 7 weeks of gestation (Figure I).

Main presenting symptoms were as in table II. Abdominal pain in 36%, vaginal discharge in 5% and discharge with spotting 33%.

Diagnosis was made in 42% of cases by clinical evaluation alone. In 39% of cases definite diagnosis was possible with both modalities, while in 19% of the cases no diagnosis was made. In 89% of the cases the diagnosis was made on single ultrasound scan and in 11% of the cases repeat scan was needed after a week to make a certain diagnosis (Figure II).

Correlation between two modalities was present in 81% of the cases. Positive correlation was obtained in 59% of cases and negative correlation was seen in 22% of cases. The correlation was not possible in 19% of cases as shown (Figure III).

Discussion

This was a comparative study between clinical and ultrasound findings in the first trimester. This study proved the supremacy of ultrasound in different forms of early pregnancy failures. This is consistent with the study of Berkowitz RL and Rana S conducted at Churchill Livingstone^{4,5,6,7,16,17}.

Clinical evaluation nevertheless should always precede ultrasound. This will not only act as a guide for the sonologist but also exclude unnecessary scans and wastage of resources. Similar suggestions, for the role of ultrasound in diagnosis of abnormal early pregnancy were given, by Longley^{6,8,17}.

The clinicians should apply their clinical judgment¹⁷ but there is a high rate of inaccuracy in diagnosing threatened, missed and incomplete abortions^{4,5,9,16}. Ultrasound has an established role in the detection of gestational sac as early as 4–5 weeks of gestation with β hCG level of 1000–2000 mIU and in diagnosis regarding continuation of pregnancy and its long-term management².

For early pregnancy diagnosis, vaginal ultrasound is considered superior to abdominal approach, especially where diagnosis is difficult. In most cases, transvaginal sonography alone can distinguish viable from non-viable empty gestational sac at a single scan. We suggest that transvaginal ultrasound should be preferred in cases of

early-threatened miscarriages and inevitable abortions to establish the viability of pregnancy to prevent delay in the management^{2,10,16}.

If fetal viability is not confirmed in the gestational sac, the diagnosis rests between a pregnancy of earlier gestation or blighted ovum. It is not possible on a single scan to differentiate between the two unless fetal cardiac activity is picked^{5,11}. Ultrasound by skilled sonologists can provide accurate knowledge about gestational age, fetal growth and condition and also fetal normality. When fetal cardiac activity is recognized, there are 98% of chances of satisfactory continuation of that pregnancy. Chances of abortion after 8 weeks of gestation are minimal if the beating fetal heart is seen on ultrasound^{12,13}.

Correlation between clinical and ultrasound diagnosis is different in different types of abortions. In our study, positive correlation was seen in 59% of the cases and negative correlation was seen in 22% of the cases and correlation was not possible in 19% of the cases, mainly because of inconclusive clinical and first ultrasound examination where we found repeat scan as a valuable adjunct to the clinical examination in diagnosis of abortions. This is consistent with the multiple studies conducted by Kurtz AB and Mansur MM^{14,15}.

Conclusion

Ultrasound is considered to be a necessary modality to diagnose most of the early pregnancy failures. Although, the implication of clinical judgment cannot be overlooked, however ultrasound seems mandatory in certain situations where clinical evaluation is inconclusive. When the details regarding gestational age, fetal growth and fetal normality are required, ultrasonography should be advised.

Table I Characteristics of the Study Population

Features	Range	Mean
Age (years)	17 – 40	26.6
Married (year)	04 – 22	06.2
Parity	0 – 08	02.1
Abortion (previous)	0 – 07	00.3

Table II Clinical Features (Symptoms) Analysis

Symptoms	Total %	Brown Discharge	Spotting	Mild Bleeding	Moderate Bleeding	PAIN	
Amenorrhoea	100	-	-	-	-	-	-
Vaginal bleeding severity	80	05%	33%	36%	6%	-	-
Lower abdominal pain	36	-	-	-	-	22%	09%
Fever	04	-	-	-	-	-	-
Miscellaneous *	03	-	-	-	-	-	-

* Nausea, vomiting increased frequency of Maturation and disappearance of previous Symptoms

Figure I Weeks of Gestation

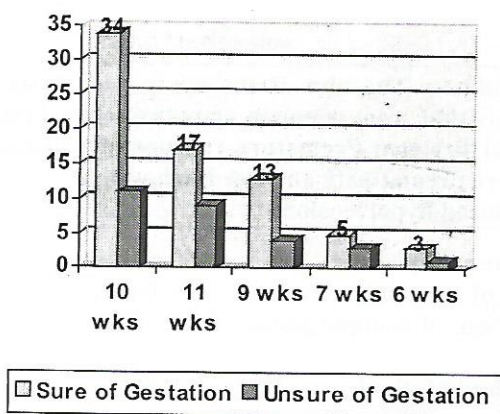


Figure II Clinical Evaluation versus Ultrasound Evaluation

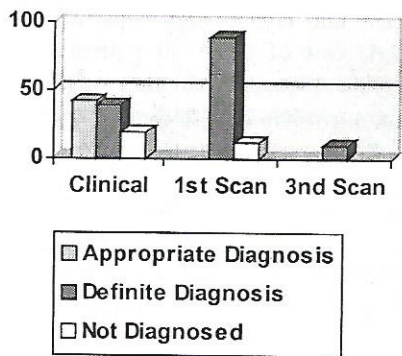
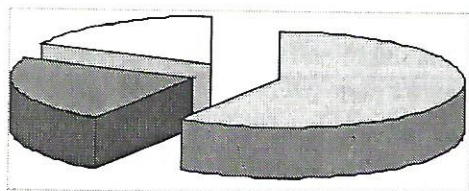



Figure III Correlation Between Two Modalities



References:

- James R. Scott MD, Ronald S. Gibbs MD Beth Y Carlan MD, Danforth's Obstetrics & Gynecology. 9th Ed; 2003: Lippincott Williams and Wilkins: 77, 145.
- Josnathen S, Berek MD, MMSc, Novak's Gynaecology. 13th Ed, Lippincott William & Wilkins Philadelphia, Baltimore, New York, London, Sydney, Tokyo, Hong Kong, Bcunos Acres: Pg: 509.
- Arshad Chohan, Fundamentals of Gynecology; Pakistan, Lahore: Mar Publisher 2002: 66.
- Johns J, Hyett J, Jauniaux E. Obstetric outcome after threatened miscarriage with and without a hematoma on ultrasound. *Obstet Gynaecol* Sept2003; 102(3): 483-7.
- Falco P, Gabrielli S, Bevini M, Pilu G, Bovicelli L. Sonography of pregnancies with first trimester bleeding and a small intrauterine gestational sac without a demonstrable embryo. *Ultrasound obstet gynaecol* Jan2003; 21(1): 62-5.
- Blohm F, Friden B, Platz - Christensen JJ, Milsom I, Nielsen S. Expectant management of miscarriage in clinical practice. *Acta Obstet Gynaecol Scand* Jul2003; 82(7): 654..
- Berkowitz RL. Bleeding in the first trimester of pregnancy. *Contemporary issues in Obstet & Gynecol* (vol. 3), Churchill Livingstone, 1988; 15.
- Longley JV, Sabbagha RE. Abnormal early pregnancy; diagnostic ultrasound applied to obstet & gynaecol. Lippin Cott; 1987: 461.
- Rana S, Rehman R, Azeem N. Abortion a diagnostic problem *Pak J, Obstet & Gynaecol*, 1990; vol 3(1): 13-21.
- Tong Song T, Wanaparik C, Srisomboon J, et al. Transvaginal utrasound in threatened a bortion w ith empty gestational sac. *Int J obstet & gynaecol*, sept1994; 46(3): 297-301.
- Bernard KG, Cooperberg PL. Sonographic differentiation between blighted ovum and early viable pregnancy. *Obstet Gynaecol survey*, 1985; (40): 675-676.
- Nazari A, Check JH, Epstien RH, Diettrich C, Farzanfar S. Relationship of small for dated sac size to crown rump length and spontaneous abortions in patients with a known date ovulation. *Obstet Gynaecol*, Sept1991; 78(3 pt 1): 369.
- Simpson JL, James L, Mills, et al. Low fetal loss rates after ultrasound proved viability in early pregnancy. *Obstet Gynaecol survey*; 1988; 43(5): 284-285.
- Kurtz AB, Shlansky Goldberg RD, Choi HY, et al. Detection of retained products of conception following spontaneous abortion in the first trimester. *J ultrasound Med*, 1991 Jul; 10(7): 387-95.
- Mansur MM. Ultrasound diagnosis of complete abortion can reduce need for curettage. *Fur J Obstet Gynaecol Repord Biol*, 1992 Mar 23; 444(1): 65-69.
- Giacobbe M, Zeferino LC, Franzin CM, Faundes A. Uteroplacental circulation during first trimester of normal and abnormal pregnancy. *Repord Biomed Online* Jan-Feb2002; 4(1): 62-7.
- Wieringa-de, Waard M, Boncel GJ, Ankum Wm, Vos J, Bindels PI. Threatened miscarriage in general practice: diagnostic value of history taking and physical examination. *Br J Gen Pract* Oct2002; 52(483): 825-9.