

# Transabdominal Sonography Comparison with Transvaginal Sonography

F NAUSHEEN J IQBAL N J FARUQI

Department of Obstetrics and Gynaecology, Jinnah Hospital, Allama Iqbal Medical College, Lahore  
Correspondence to Dr. Fauzia Nausheen, Senior Registrar, E-mail: doc\_noshi@hotmail.com

**Aims & Objectives:** Transvaginal sonography (TVS) comparison with trans-abdominal sonography (TAS) in the diagnosis of pelvic masses **Study Design:** Retrospective descriptive study conducted at Gynae clinic Jinnah Hospital Lahore with collaboration of radiology department **Materials and Methods:** Transvaginal Sonogram was compared with transabdominal sonogram in hundred women referred for evaluation of pelvic masses from gynae clinic. All the women were interviewed regarding their age, parity, duration of mass and associated symptoms. Diagnosis was based on the combination of clinical, sonographic (TVS, TAS) and surgical correlation. Both ultrasound modalities were compared for the details about the internal architecture and diagnostic information. **Results:** Most common age group with pelvic masses was between 26-35yrs. TVS was more sensitive for both uterine and adnexal masses. Sensitivity of TAS was 65% and TVS was 88%. There was a significant difference in diagnosing true positive cases by trans-vaginal approach. (P value < 0.001) Specificity of TAS was 89% and TVS 86% for both uterine and adnexal masses. Image quality was better in 87% of cases with trans-vaginal approach and 5% of cases with trans-abdominal approach and it was equivalent in 8% of cases. There was a significant difference in the image quality between two modalities (P value < 0.001). Regarding anatomical details TAS was better in 12% of cases and TVS was better in 28% of cases and both were equivalent in 60% of cases, Diagnostic information of these two modalities was almost equivalent. TAS was better in 7% of cases and TVS was better in 8% of cases and both were equivalent in 85% of cases **Conclusion:** The results suggest that TVS has considerable advantage over conventional TAS in evaluation of pelvic masses in women.

**Key words:** Transvaginal sonography, Transabdominal sonography, pelvic masses

Today, assessment and evaluation of gynecological patients with pelvic masses are rapidly moving from operation theatre and ward environment, into the out patient department because the rapid and accurate diagnosis is possible with minimum of investigations and invasive procedures. Ultrasound imaging is one the diagnostic modalities that provide an effective and rapid means of diagnosis and detection of pelvic masses. Its accessibility and high patient acceptance make it applicable as an initial means for assessing many gynecological disorders<sup>1</sup>.

Diagnostic sonography of pelvic organs can be performed using trans-abdominal sonography (TAS) approach in which uterus and adnexa are imaged through the distended urinary bladder and trans-vaginal sonography (TVS) in which probe is inserted into the vagina to image the pelvic organs.

TAS uses low frequency sound waves with deeper penetration (3-3.5MHz), and is best performed with fully distended bladder because of the problem of intervening bowel gasses and fat of anterior abdominal wall. In general TAS is best used for large masses that extend out of pelvis above the urinary bladder<sup>2</sup>. TVS uses higher frequency sound waves (5-8 MHz) with high resolution but at the sacrifice of limited penetration (10 cm)<sup>1</sup>. The higher frequency sound waves in TVS give much better definition because of the closer proximity of the transducer to the structures being imaged.

The advantages of TVS over TAS are well documented and correlates closely with subsequent operative findings<sup>3,4,5</sup>.

Though, TVS is highly sensitive method for detecting endometrial abnormalities, intra-cavity pathologies, evaluation of adnexal and uterine masses and in accurate assessment of ovarian morphology; but it has some practical problems like intolerance of probe by young, old and scarring patients and diagnostic drawbacks because of the limited depth of view.

This study was carried out to compare these two (TAS and TVS) ultrasound modalities in assessment and evaluation of patients with pelvic masses. Both were compared for the visual clarity, diagnostic details, patient convenience, their sensitivity and specificity, and correlation with final diagnosis.

## Subjects and methods:

It was a descriptive, retrospective study; sample included 100 women enrolled from Gynae outpatients department for evaluation of pelvic masses manifested on clinical examination. Patients less than 15yrs of age and more than 45yrs of age, with suspicion of malignancy and all other gynaecological emergencies requiring immediate laparotomy were excluded.

After detailed clinical assessment, all the women underwent through trans-abdominal as well as trans-vaginal ultrasound scan. The finding of the both US were recorded, analyzed and compared with the help of computer



software. The final diagnosis was made surgical in 37 patients and by a combination of sonographic and clinical correlation in the remaining patients.

**Main Outcome Measures:** Comparison of sensitivity and specificity diagnostic accuracy, anatomical details, and image quality of trans-abdominal and trans-vaginal sonography in evaluation of pelvic masses

**Results**

Most common age group with pelvic masses was between 26-35yrs (48), and 23 patients were of 15-25Yrs and 29 patients were between 36-45Yrs of age as shown in Table-I. Uterine masses were 37% and adnexal masses 63% among all age groups. At 15-25Yrs of age 74% masses were adnexal and 26% were uterine. In 26-35yrs 65% were adnexal masses and 35% were uterine. At 36-45yrs 52% were adnexal and 14% were uterine as shown in Table-I.

Table: I Different age groups of patients with pelvic masses

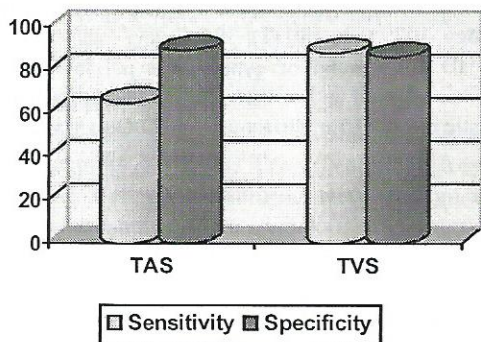
Age (Yrs)	No.	Uterine masses	Adnexal masses
15-25	23	6(26%)	17(74%)
26-35	48	17(35%)	31(65%)
36-45	29	14(48%)	15(52%)
Total	100	37	63

Table: II Correct diagnosis

	TAS	TVS
Correct Diagnosis	82%	89%
Non-Specific Information	13%	5%
Errors	5%	3%

As far as sensitivity of TAS and TVS in diagnosis of pelvic masses was concerned, TVS was more sensitive for both uterine and adnexal masses. Sensitivity of TAS was 65% and TVS was 88%. There was a significant difference in diagnosing true positive cases by trans-vaginal approach. (P value < 0.001) as shown in Fig.-I.

Fig: I Sensitivity and specificity of TAS & TVS for pelvic masses

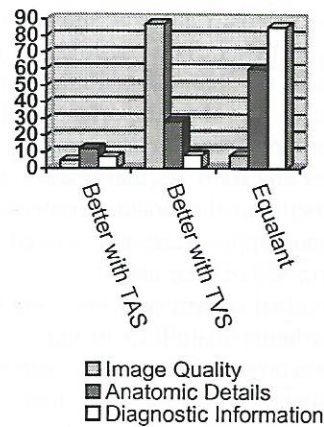


On comparison of specificity TAS was more specific than TVS for diagnosis of pelvic masses. Specificity of TAS was 89% and TVS 86% for both uterine and adnexal masses. The false negative was high with trans-vaginal

approach than with trans-abdominal approach as shown in Figure-I.

When image quality, anatomical details and diagnostic information were compared, it was noticed that image quality was better in 87% of cases with trans-vaginal approach and 5% of cases with trans-abdominal approach and it was equivalent in 8% of cases. There was a significant difference in the image quality between two modalities (P value <0.001) as shown in Fig.-II.

Fig: II Comparison between TAS & TVS for image quality, anatomic details And diagnostic information



For anatomical details TAS was better in 12% of cases and TVS was better in 28% of cases and both for equivalent in 60% of cases as shown in figure1. Diagnostic information of these two modalities was almost equivalent. TAS was better in 7% of cases and TVS was better in 8% of cases and both were equivalent in 85% of cases.

When both modalities were compared for correct diagnosis, TAS was correct in 82% of cases, non-specific information in 13% of cases and errors occurred in 5% of cases. TVS was correct in 89% of cases, and non-specific information in 8% of cases and errors occurred in 3% of cases as shown in Table-II.

**Discussion:**

In this study we compared the two modalities of ultrasound (TAS and TVS) for diagnosis of pelvic masses. Adnexal masses were more common in young age group, however the uterine masses were found more frequently in middle age group. Relationship of age and pelvic masses was almost similar in a study conducted in UK<sup>5</sup>.

Sensitivity of trans-vaginal ultrasound was found higher than the trans-abdominal approach, in this study. This is consistent with the results of the studies conducted at Duke University in Department of radiology<sup>6</sup>. This is because of more true positive cases diagnosed on trans-vaginal approach.

When specificity of both modalities was compared our results were similar with results of the study of



Radiology Department of Duke University<sup>6</sup>. Specificity of trans-abdominal ultrasound was better than trans-vaginal it was seen that rate of false negative was higher with trans-vaginal approach. We suggest that all the trans-vaginal scans for pelvic masses should be preceded by trans-abdominal scan to improve the accuracy of diagnosis.

Transvaginal image quality was better in 88% of cases and trans-abdominal was better in 5% of the cases and both techniques were equal in 14% of the cases. Similar results were concluded in a study by Department of Radiology St. Pitters berg<sup>7</sup>. Both techniques provided equivalent diagnostic information's in 60% of cases, however trans-vaginal ultrasound was particularly more informative in cases of small adnexal and uterine masses especially in obese patients. This is consistent with the study of Department of Radiology Philadelphia. They concluded that there was no important difference in diagnostic information provided by two imaging modalities in 16% of their cases and trans-vaginal images were worse in 2%. They explained that diagnostic problems posed by trans-abdominal sonography were not solved by trans-vaginal sonography in 4% of their cases<sup>8</sup>.

As far as individual organs and fine structures were concerned TVS was better than TAS in individual organs details and fine structures. Non-specific information on trans-vaginal ultrasound was less than trans-abdominal approach. Almost equal errors seen in both modalities. Non-specific pattern was most common in tubo-ovarian abscess, adenomyosis and endometrioma. Similar results were concluded in the study on accuracy of ultrasound by Walsh and Taylor<sup>9,10</sup>. However, if we combine both modalities of ultrasound than the chances of error can be minimize. For adnexal masses when TVS was compared with TAS, TVS had improved scan and yield did new information in 62% of cases examined and better visualization and 21% of the cases examine. In 15% of cases no difference was seen in the information provided by two modalities. These results were concluded in a study by Department of Radiology, Pennsylvania<sup>8</sup>.

#### Conclusion:

Ultrasonography has become an important tool in the practice of modern obstetrics. Ultrasonographic findings of different pelvic masses are highly dependable and can be

used for preoperative decision-making. Vaginal ultrasonography is an effective routine adjunct to physical examination of patients. It has diagnostic capabilities superior to those of bimanual pelvic examination and increases the accuracy of diagnosis in gynaecologic patients. We recommend using trans-vaginal ultrasound in combination of trans-abdominal ultrasound especially in cases of unclear pelvic pathology. TVS is best used when TAS is not conclusive.

#### References:

1. Tames R Scott, MD. Ronald S Gibbs, MD. Beth YK Artan, MD Arthur F. Haney, MD Danforth's Obstetrics and Gynaecology. Ninth edition, Lippincot William & Wilkins. Philadelphia, Baltimore, New York, London, Sydney, Tokyo. Hong Kong, Beunos Aeres 511,528,144,647
2. Josnathen S Berek, MD MMSc, Novak's Gyneacology. 13<sup>th</sup> edition, Lippincot William & Wilkins. Philadelphia, Baltimore, New York, London, Sydney, Tokyo. Hong Kong, Beunos Aeres pg.378.
3. Leibman AJ, Kruse B, McSweeney MB. Transvaginal sonography: comparison with trans-abdominal sonography in the diagnosis of pelvic masses. *AJR Am J Roentgenol.* 1988 Jul; 151(1): 89-92.
4. Voss SC, Lacey CG, Pupkin M, Degefu S. Ultrasound and the pelvic mass. *J Reprod Med.* 1983 Dec; 28(12): 833-7.
5. D Keith Edmonds FRCOG, FARCOG, Dew Hurts Textbook of Obstetrics and Gynaecology for postgraduates 6th Edition Oxford. Germany, Japan UK. 1999, Backwell Science, pg556.
6. Reeves RD, Drake TS, O'Brien WF1. Ultrasonographic versus clinical evaluation of a pelvic mass: *Obstet Gynecol.* 1980 May; 55 (5): 551-4.
7. Mendelson EB, Bohm-Velez M, Joseph N. Gynecologic imaging: comparison of trans-abdominal and trans-vaginal sonography. I: *Radiology.* 1988 Feb; 166(2): 321-4.
8. Coleman BG, Arger PH, Grumbach K, Menard MK, Mintz MC, Allen KS, Arenson RL, Lamon KA. Transvaginal and trans-abdominal sonography: prospective comparison. *Radiology.* 1988 Sep; 168 (3): 639-43.
9. Walsh JW, Taylor KJ, Wasson JF, Schwartz PE, Rosenfield AT. Gray-scale ultrasound in 204 proved gynecologic masses: accuracy and specific diagnostic criteria. I: *Radiology.* 1979 Feb; 130 (2): 391-7.
10. Bowie JD. Ultrasound of gynecologic pelvic masses: the indefinite uterus and other patterns associated with diagnostic error. *J Clin Ultrasound.* 1977 Oct; 5(5): 323-8.