

# Microscopic Changes Induced By Cr-VI in Spleen of Albino Mice

H NABEEL M NASIM F JAFRI

Department of Anatomy, Fatima Memorial Hospita & College of Medicine & Dentistry, Lahore.  
Correspondence to Dr. Hafsa Nabeel, Associate Professor

Chromium is believed to be an essential trace element in human nutrition. Evidence suggests that it plays an important role in normal carbohydrate metabolism. It was found that patients receiving long-term total parenteral nutrition (TPN) without chromium developed glucose intolerance, weight loss and peripheral neuropathy. Chromium is present in a normal diet at trace (but essential) levels. Occupational exposure is related to the industrial uses of chrome compounds in production and use of steels, pigments, leather tanning and wood preservation solutions, plating chemicals, and cement. Toxicity is predominantly associated with industrial exposures. Hexavalent chromium compounds appear to have greatest toxicity and almost all tissues of body are affected. To evaluate the effects on lymphoid tissue, present study was carried out. The mice of experimental group (2wks, 4wks, 6wks and 8wks) were injected Potassium dichromate ( $K_2Cr_2O_7$ ) intraperitoneally according to experimental design. The drug caused slight to marked hyperplasia of lymphoid follicles and dilatation of sinuses of red pulp depending upon duration of exposure. Aggregates of heamosidrin-laden macrophages were also seen indicating heamolytic effects on RBCs.

**Key Words:** Hexavalent Chromium, Spleen, Heamosidrin pigment

Chromium is widely distributed on earth's crust. It is found in nature principally as chromate ore. Chromium exists in several valence states, of which the trivalent and hexavalent states are the most common. Most chromium in the food supply is in the trivalent state. Hexavalent chromium compounds are recognized as toxic and are potential carcinogens. Chromium is found in many foods<sup>1</sup> typically in small amounts. Good food sources of chromium include whole grains, cereals, spices (black pepper, thyme), mushrooms and brown sugar, coffee, tea, beer, wine and meat products. Brewer's yeast is also a good source of chromium. Fruits and vegetables are generally poor sources of chromium, as are most refined foods.

Chromium is an essential element required for normal carbohydrate and lipid metabolism. Chromium has been linked to maturity onset diabetes and cardiovascular diseases<sup>2</sup>. Human exposure to these metals occurs principally in occupational settings and environmental contamination<sup>3</sup>. Both acute and chronic toxicity are caused by Hexavalent chromium<sup>4,5</sup>. Cr (VI) is known to have hepatotoxic, nephrotoxic and teratogenic effects as well<sup>6</sup>. It's also known to have effect on lymphoid tissue. Population exposed to Cr (VI) for longer periods are reported to be at high risk of developing lymphomas<sup>7</sup>.

Chromium is used in industries especially in leather tanning in Pakistan. The effluents are in general discharged in adjoining land areas. Study has been conducted on such an area in vicinity of Kasur city, containing pink colored effluent from tanneries<sup>8</sup>. The effects of Cr VI on lymphoid tissue were analyzed by observing the histological changes induced by this metal in spleen of mice.

## Materials and methods:

Forty-eight male albino mice were divided in eight groups. They were kept under constant temperature with 12 hourly

light and dark cycle. Animals were acclimatized for one week.

**Experimental Design:** A group of 24 albino mice weighing 20-40gm. were administered 0.6% aqueous solution of  $K_2Cr_2O_7$  (20mgCrVI /100ml.) at a dose of 20mg/kg of body weight intraperitoneally on alternate days. Another control group of 24 mice was administered distilled water, i.p. that is on alternate days after every two weeks six mice from each group were sacrificed and spleens were removed and prepared for histological studies as per routine.

## Results:

**General Physical Examination:** All animals of control and experimental group were found to be active and healthy on the Day of Sacrifice. However, a change in mean weight of animals was observed in experimental group, when compared with their controls. The two-week treated mice showed 13.4% increase in body weight when compared to animals of their control group. 4 week treated mice indicated increase in body weight by 2.5%. On prolonging chromium administration the body weight showed distinct decrease. In 6 week treated mice there was decrease in body weight by 17.5% whereas in 8 weeks treated group of mice body weight was not changed.

**Histological changes:** In spleens of 2weeks treated animals Fig1, mild hyperplasia of lymphoid follicles and slight dilatation of sinusoids of red pulp is observed. Scattered heamosidrin laden macrophages are present. In 4 weeks treated animals Fig 2: Congestion of red pulp with dilated sinuses and hyperplasia of white pulp is marked. Heamosidrin pigment in macrophages is also evident. In 6-8 weeks treated groups Fig 3: Splenic tissue revealed marked hyperplasia of lymphoid follicles with prominent germinal centers. Sinusoids are dilated with prominent reticuloendothelial cell lining. Dense aggregates of



heamosidrin-laden macrophages are present. Extra cellular golden brown pigment is also seen. The spleen of mice of corresponding control groups does not show any changes from normal architecture.



Fig1: Red pulp of spleen showing mild congestion with dilated sinusoids and mild hyperplasia of lymphoid follicle.

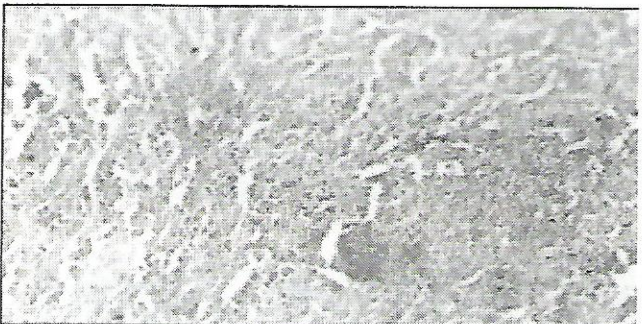

Fig: 2: Red pulp of spleen showing heamosidrin laden macrophages, dilated sinusoids with prominent reticuloendothelial cell lining and hyperplasia of lymphoid follicle.

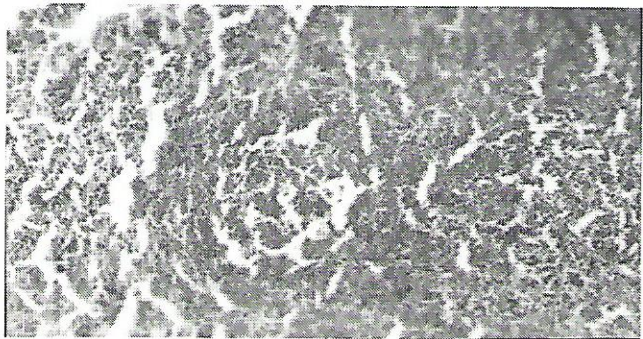


Fig: 3 Reactive hyperplasia of white pulp, along with heavy deposits of haemosidrin pigment.

#### Discussion:

Chromium is an essential trace element, having multiple valencies, Cr (III) is required for normal metabolism but its hexavalent form is used in industry and its indiscriminate use has been declared hazardous for human

health. Recently in suburbs of Lahore and Kasur district, multiple congenital anomalies in the vicinity of leather tanning industrial areas were reported in media. Keeping in mind, the present research was carried out to assess the effects of Cr (VI) on lymphoid tissue. This research reveals clearly that there is reactive hyperplasia of white pulp in the spleen in response to prolong exposure of Cr (VI). Associated congestion with hemorrhages is also present which is represented by presence of heamosidrin laden macrophages Das Neves et al. have also observed depletion of red pulp cells, accompanied by increase in macrophages<sup>9</sup>.

Hemolytic effects on RBCs (RBCs damaging effect) are also a possibility for the presence of increased amount of golden brown (heamosidrin) pigment within the spleen.

#### Conclusion:

Histological findings of present research have clearly revealed a time dependency effect of Cr (VI) on spleen. Its prolonged use causes adverse effects on spleen, indicating that other lymphoid organs can also be involved, ultimately affecting the immunity. This can be avoided if Cr (VI) used by various industries is not dumped unprocessed. In the line of these observations guidelines could be formulated for the industrial use of this metal.

#### References:

1. Shupack S I. The chemistry of chromium and some resulting analytical problems Environ. Hlth. Perspect. 1991, 92: 7-11
2. Anderson A R. Chromium metabolism and its role in disease processes in mass Clin. Biochem. 1986, 4(1): 31-41
3. Thomann R V, Synden C A and Squibb K S. the importance of incorporating long term storage compartment. Toxicol. Appl. Pharmacol. 1994; 128: 189-198.
4. Baruthio F. Toxic effects of Chromium and its compounds. Biol. trace Elem. Res. 1992; 32: 145-153.
5. Katz S A and Salem H. the toxicology of Chromium with respect to its Chemical .Speciation; A review. Appl. Txicol. 1993; 13(3): 217-224
6. Mikalsen A, Alexander J, Anderson R A and Sundberg M I. Effect of in vivo chromate, acetone and combined treatment on rat liver in vitro microsomal Chromium(VI) produce activity on cytochrome P450 expression. Pharmacol. Toxicol. 1991; 68: 456-463
7. Bick R L, Girardi T V, Lack WJ, Costa M and Titelbaum D. Hodgkin's disease in association with hexavalent chromium exposure. Int. J. Hematol. 1996; 64: 257-262.
8. Qazi J I, Sheikh S I, Haq R and Shakoori A R. Cultivation of chromium tolerant ciliate protozoan from industrial effluents of tanneries. Pakistan J. Zool. 1997; 29(4): 405-409.
9. Das N, Santos T M, DePereira M L and Jesus J P. Chromium (VI) induced alterations in mouse spleen cells: a short term essay. Cytobios. 2001; 106: 27-34.