

Case Report

Malignant Melanoma: Presentation as a Primary Retroperitoneal Tumor

F FAHIM M F AFZAL M AYYAZ S FAHIM

Department of Surgery, King Edward Medical College/Mayo Hospital, Lahore

Correspondence to Dr. Fraz Fahim, Senior Registrar, E. mail: frazfahim@hotmail.com

This is a case report of an extremely rare primary malignant melanoma presenting in the retroperitoneum of a 30 years old female. She was operated in a District General Hospital with a presumptive diagnosis of hydatid cyst of right lobe of liver. The patient bled profusely on exploration and the surgeon packed the abdomen and referred her to our emergency, where she was received in shock. After resuscitation she was operated on the next available list and was found to have a very vascular, pigmented, retroperitoneal mass measuring 10-x 12-cm lying in front of the infrarenal IVC pushing the duodenum towards the midline. It was completely excised. Histopathology showed it to be a malignant melanoma. Upon subsequent examination and extensive workup, no evidence of a primary malignant melanoma was found. There was no past history of a melanoma which may have regressed spontaneously or excised. After extensive search of literature we could not find another report of a primary retroperitoneal melanoma.

Key words: Malignant melanoma; retroperitoneal tumor

The incidence of skin cancer is increasing faster than that of any other cancer in the United States: with the exception of lung cancer in women¹. Malignant melanoma is a skin tumor that is showing a rapid increase in incidence at a rate of 5% per annum¹. The annual incidence in United States is approximately 40,300 with approximately 7,300 deaths². It occurs 40 times more frequently among the fair skinned people¹. Case fatality rate however has fallen over the years because of early detection and treatment².

Factors predisposing towards a malignant melanoma are divided into four categories. 1) Exposure to ultraviolet radiation, i.e. psoriatic patients on PUVA therapy. 2) Familial factors include blue eyes, fair or red hair, pale complexion, freckles and a strong propensity to sunburn in childhood. It also includes familial predisposition for cancer and Atypical Mole Syndrome/ Dysplastic Naevi. 3) Genetic factors are as yet under investigation but may be autosomal dominant with incomplete penetrance or polygenic. Atypical Mole Syndrome is associated with 9p. 4) Psychosocial factors are an attitude of stress, depression and helplessness¹. Malignant melanoma has been associated with HPV type 16 (human papilloma virus type 16)³

90% of malignant melanomas are cutaneous. Some uncommon cutaneous sites are scrotal skin⁴ and external auditory canal⁵. Extra-cutaneous sites include the eye⁶ (conjunctiva, choroid), oral mucosa⁷, chest wall⁸, breast⁹, lungs¹⁰, ovary¹¹, Jejunum¹², Ileum¹⁰, anorectum¹² and other abdominal manifestations.

We report a case of a malignant melanoma in the retroperitoneum without any history of a cutaneous melanoma anywhere on the body. On performing extensive search in the literature, we could find no report of a primary malignant melanoma in the retroperitoneum.

We therefore presume that this is the first report of such a case.

CASE REPORT:

A thirty-year-old female from Gujrat District of Kashmiri descent, presented to our emergency on 8th August 2000 a day after her exploratory laparotomy in the periphery. She had presented to the District General Hospital with a complaint of dull constant ache in the right hypochondrium, a feeling of fullness and low-grade fever off and on for the last 8 months. There was a history of anorexia and weight loss but no specific gastrointestinal symptoms. The laparotomy was done with the presumptive diagnosis of a hydatid cyst right lobe of liver in the posterior aspect following their ultrasonologist's report. A large retroperitoneal mass in the right hypochondrium extending to epigastrium and right lumbic quadrant. On attempting resection the surgeon found it to be a very vascular tumor and closed the abdomen after packing. The patient was rushed to Mayo Hospital.

We received the patient in shock with a P 120/min; BP 90/60 mmHg and T 103 F on first post op day. She was extremely pale. We resuscitated the patient and built her up with multiple transfusions and by restoring the electrolyte balance. An ultrasound and a CT with double contrast was planned but could not be carried out since the patient continued to be in shock and was reopened on the first available list on the third day of her first laparotomy. A 10 x 12 cm spongy retroperitoneal mass (Figure 1) with bluish pigmentation was found in the right hypochondrium in front of the infrarenal IVC pushing the duodenum towards the midline. It was separate from the right kidney, IVC, abdominal aorta and pancreas. A complete resection of the mass was achieved.

Upon histopathology (Figure 2) it showed nests of pleomorphic cells with vesicular nuclei and prominent

nucleoli. There was abundant melanin pigment. And the diagnosis was malignant melanoma

She was kept in ICU for two days but remained hemodynamically stable and afebrile with good urine output. On 5th post op day (7th post op day after her first laparotomy), she was discharge with instructions for follow up. She has since then turned up for regular follow up and is doing well six months after the excision of tumor with no signs of recurrence on serial ultrasonography. She has however refused any further treatment.



Figure 1: Gross Appearance

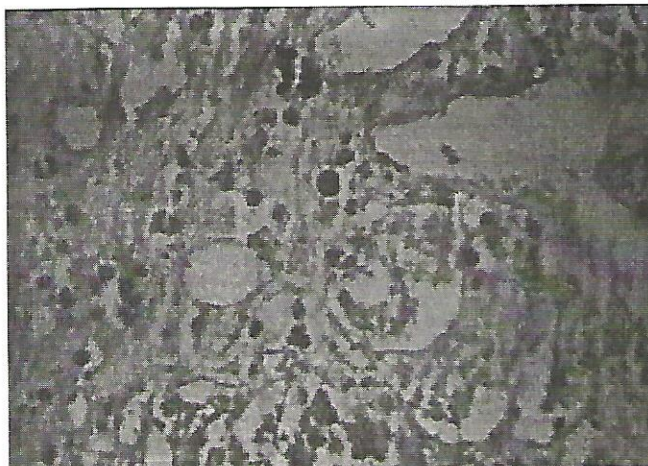


Figure 2: Histopathology

Discussion:

Melanoma arises from transformed melanocytes and therefore can arise anywhere that melanocytes have migrated during embryogenesis¹³. Primarily however it is a cutaneous tumor since it is most often linked to exposure to sunlight.

A Malignant Melanoma is usually diagnosed on a clinical suspicion upon examining a suspicious lesion followed by an excision biopsy. Histopathology usually reveals nests of pleomorphic cells with vesicular nuclei of large size and irregular contour and prominent nucleoli and abundant melanin pigment. These cells grow as poorly

formed nests or as individual cells at all levels of underlying tissues.

We re-operated with the suspicion of a retroperitoneal tumor and the object of achieving either a resection or at least hemostasis. On laparotomy we found a highly vascular, pigmented tumor. We were able to achieve resection. On retrospective history, the patient did not give any history of a cutaneous lesion in the back or elsewhere, except for a few naevi, present since birth and had shown no change whatsoever indicating neoplastic change. And we could find no evidence of a dysplastic naevus or any other suspicious lesion despite a careful search. The patient herself was from fair colored Kashmiri race, but had a well-pigmented skin. Although primaries have been known to regress, but in the absence of such a history, we presume that this is a first report of a primary retroperitoneal malignant melanoma.

Pertinent of this discussion are two studies from Australia, which have reviewed the pattern of lymphatic drainage from skin of the back using routine lymphoscintigraphy with 99mTc Antimony Sulphide colloid. In a series of 542 patients; 2.58% have been found to have lymphatic drainage directly from posterior body wall to sentinel nodes in the retroperitoneal and paravertebral regions. In fact one case reports this pattern of lymphatic drainage to be the only channel without any drainage of the skin of the back to axillary, inguinal or triangular intermuscular space fields^{14,15}.

Regarding the treatment, the first line therapy is a wide excision. Lesions, both cutaneous and extra-cutaneous, are resected with a wide margin. Thin melanomas with a depth of less than 1mm need a 1cm margin while deeper ones need a 2cm margin¹⁶. There is a controversy about regional lymph node dissections. Opponents of elective lymph node dissection (ELND) for clinically negative nodes believe that because 80% of patients with clinical Stage I disease have histologically negative nodes at the time of resection of the primary tumor, prophylactic excision of the regional nodes is unnecessary. ELND is now recommended based on the identification of metastatic cells within the sentinel lymph node in all patients with primary melanomas with a thickness of at least 1.0 mm¹⁸. In view of the unstable condition of the patient we could not offer her any retroperitoneal lymphadenectomy.

For failed primary treatment and for advanced disease chemotherapy and chemiotherapy regimen are being used with variable effect. Various therapeutic agents used are¹³ Paclitaxal, Tmozolomide, IL 2 and α Interferon. Many others are being tried.

The chemiotherapies have shown efficacy and response comparable to chemotherapy alone with the advantage of decreased toxicity resulting in a better albeit more expensive treatment modality. Once however, there is evidence of systemic involvement in malignant melanoma, treatment options become severely limited and

the disease is virtually incurable¹⁴. Overall younger women (less than 45 years) tend to have superior survival rates compared with older women and men of any age¹⁵.

Some other modalities for regionally advanced disease are isolated hyperthermic limb perfusion, which has been found to prevent recurrent metastatic disease in melanomas of extremities¹⁶.

The newer trend has been toward developing a vaccine for use in endemic areas and discovering effective tumor markers for evaluating the prognosis of the disease. TA90¹³, Mitf¹³ and S100¹⁷ may be effective markers for therapy monitoring and disease progression.

We have stressed that this is an extremely rare presentation. However patients presenting with cutaneous melanomas especially in the lumbar region and those at high risk for malignant melanoma need to be examined with the possibility of extra-cutaneous melanomas, with an index of suspicion for any abdominal primary or secondary.

References:

1. McEldowney S. Malignant Melanoma: Familial, Genetic, and Psychosocial Risk factors. *Clinician Reviews* 1997 7(7):65-68, 73-76, 81-82
2. Lowney JK Lairmore TC Eberlein TJ Washington Manual of Surgery Second Ed. 1999 pp.454
3. Takamiyagi A; Asato T; Nakashima Y; Nonaka S Association of human papillomavirus type 16 with malignant melanoma *Am J Dermatopathol* 1998 Feb;20(1):69-73
4. Primary scrotal malignant melanoma. Report of 2 cases and review of the literature *J Exp Clin Cancer Res* 1998 Mar;17(1):91-3
5. Berkmen F; Tandogdu R; Ardjocoglu A. Malignant melanoma of the external auditory canal *Am J Clin Oncol* 1998 Feb;21(1):28-30
6. Milbrath MM; Campbell BH; Madieto G; Janjan NA. Double choroidal malignant melanoma in an eye with apparent clinical regression *Surv Ophthalmol* 1998 Mar-Apr;42(5):441-8.
7. Holck DE; Dutton JJ; Pendergast SD; Klintworth G. Differential giant cell epulis diagnosis—malignant melanoma of the mouth mucosa *Mund Kiefer Gesichtschir* 1998 May;2(3):160-2
8. Koch A; Boldt C; Hilge G; Schuttrumpf U. Malignant melanoma of the chest wall with an unknown primary lesion *Jpn J Thorac Cardiovasc Surg* 1998 May;46(5):399-401
9. Yotsumoto G; Shimokawa S; Yamaoka A; Watanabe S; Matsushita Y; Taira A. Malignant melanoma metastatic to the breast: a report of seven cases diagnosed by fine-needle aspiration cytology. *Cancer* 1998 Jun 25;84(3):160-2
10. Cangiarella J; Symmans WF; Cohen JM; Goldenberg A. Diagnostic: metastases ileale, retroperitoneale et pulmonaire d'un melanome malin. *J Radiol* 1999 Dec;80(12):1716-7.
11. Merran S. Piura B; Kedar I; Ariad S; Meirovitz M; Yanai-Inbar I Malignant melanoma metastatic to the ovary *Gynecol Oncol* 1998 Feb;68(2):201-
12. Bobic-Radovanovic A; Latkovic Z; Marinkovic J; Radovanovic Z Predictors of survival in malignant melanoma of the conjunctiva: a clinico-pathological and follow-up study *Eur J Ophthalmol* 1998 Jan-Mar;8(1):4-7
13. Jeffrey Weber Diagnostic Assays and Chemobiotherapy Program and abstracts of the American Society of Clinical Oncology 36th Annual Meeting; May 20-23, 2000; New Orleans, Louisiana
14. Mota A, Deisseroth A Systemic treatment of malignant melanoma *Clin Plast Surg* 2000 Jul;27(3):463-74
15. Kemeny MM; Busch E; Stewart AK; Menck HR Superior survival of young women with malignant melanoma *Am J Surg* 1998 Jun;175(6):437-44; discussion 444-5
16. Ma D, Ariyan S The use of isolated limb perfusion to manage recurrent malignant melanoma *Clin Plast Surg* 2000 Jul;27(3):441-50, ix
17. Djukanovic D, Hofmann U, Sucker A, Rittgen W, Schadendorf D Comparison of S100 protein and MIA protein as serum marker for malignant melanoma *Anticancer Res* 2000 May-Jun;20(3B):2203-7