

Case Report

Solitary Fibrous Tumour Arising from the Omentum

A SALEM M MADDEN, P BATESON

Departments of Surgery and Histopathology, Altnagelvin Area Hospital, Londonderry BT47 6SB, N/Ireland, UK
Correspondence to Mr. A. Salem, E mail: tasalem10@aol.com

Introduction

Solitary fibrous tumours (SFT) are uncommon spindle cell neoplasms generally associated with serosal surfaces especially the pleura. Recently, these tumours have been documented in a number of extra pleural sites^{1,2,3,4,6}. Extra-serosal examples are becoming recognized⁵. In this report the case of a solitary fibrous tumour arising from omentum is described. The diagnosis of SFT was not made until the excised tumour subjected to histopathology and immunohistochemistry.

Case report

History: A 60-year old man presented with a one week history of intermittent periumbilical pain and no past history of similar pain. He had weight loss of half a stone over 6 weeks and abdominal distension for 2 weeks, there was no loss of appetite or other systemic complaint. General examination revealed bilateral Dupuytren's contracture and grade 4 finger clubbing. Abdominal palpation revealed a very large non tender mass, The Liver and spleen were difficult to assess because of the size of the mass. Rectal examination was normal. An abdominal Ultrasound showed a central abdominal mass of mixed echogenicity. CT scan showed a large lobulated mass with overlying serpiginous vessels with a clear plane posteriorly separating it from the retro-peritoneum (Fig. 1). Liver, spleen and pancreas showed no abnormality. CT scan of the chest showed no abnormality. Core biopsy under ultrasound guidance revealed features consistent with a solitary fibrous tumor, haemangiopericytoma or angiosarcoma.

The patient underwent a midline laparotomy. The huge mass was attached to the greater omentum by a pedicle (Fig. 2) with minimal adhesions to the lateral peritoneum. It was excised completely. The post-operative course was uneventful. Gross pathological findings macroscopically revealed the mass measuring 24x19x10 cm, weighing 3870 grams and on section it was a fleshy lobulated tumour with a few cystic areas. There was some attenuated fat on part of the surface. Histologically, the architecture was pattern-less with prominent stromal hyalinization, varying cellularity (mainly spindle and ovoid cells) and branching (haemangiopericytoma-like) vessels. Elsewhere the tumour cells are more atypical and showed a high mitotic rate (up to 25mitosis/High Power Field). Mitotic activity >4 mitosis /High Power Field has been used to discriminate between benign and malignant forms at thoracic and extra thoracic sites. Immuno-

histochemistry was strongly positive for CD34 and CD99 while SMA, desmin, S-100 protein and C-kit were all negative.

At four-month follow up the patient remains free of any symptoms and was disease-free on CT scan.

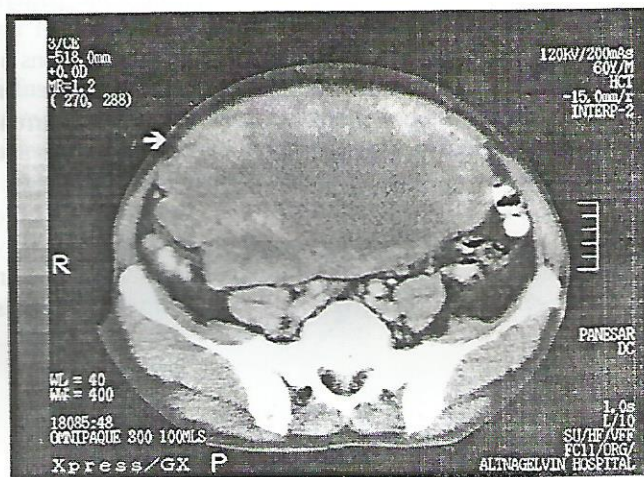


Fig. 1: CT showing the huge tumour burden. Note the plane of cleavage at the extreme posterior.

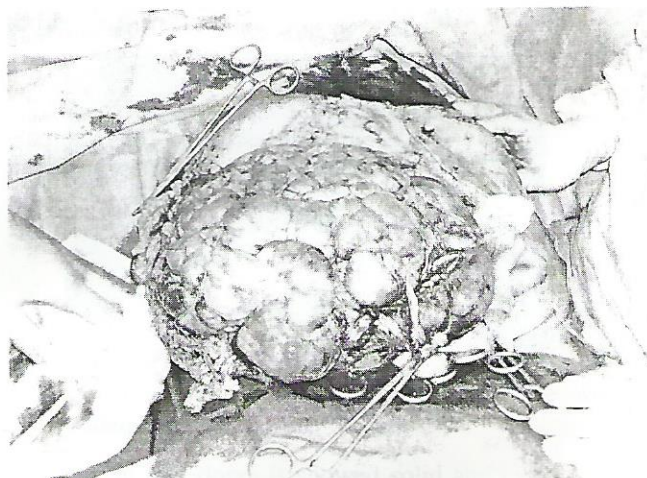


Fig. 2: Giant lobulated tumour mobilized – the leading clamp defines the greater omentum, the tissue of origin.

Discussion

The term solitary fibrous tumour refers to a neoplasm which was originally described in the pleura with several synonyms including localized or fibrous mesothelioma⁵.

Solitary Fibrous Tumour Arising from the Omentum

Identical tumours have since been described in other locations^{1,2,3,4,5,6}. This is the first report of a solitary fibrous tumour involving omentum.

Solitary fibrous tumours clinically have symptoms either related to the site or systemic symptoms (hyperglycemia, arthralgia, osteoarthropathy and clubbing fingers) all resolve with the tumour excision¹. SFT is a tumour with unknown etiology usually involving serosal surfaces but without evidence of mesothelial differentiation, the result of recent immunohistochemical studies strongly suggest mesenchymal origin^{1,2}. This tumour must be distinguished from hemangiopericytoma in which vascular pattern is seen throughout and from fibrocytoma which has a prominent herring-bone pattern and lacks vascular architecture⁵. Clinical awareness of the lesion is important, because benign and malignant forms of the tumour occur. The malignant form pursue an aggressive course manifested by local invasion, recurrent growth or metastasis⁴. Recurrence is likely with larger and histological aggressive tumours (increased cellularity, pleomorphism and mitosis >4/HPF)¹. Local excision is the initial treatment of choice. Long term follow up is very important as SFT may recur locally^{5,6}. Rare location of an uncommon lesion often gives rise to difficulty in diagnosis

or to misdiagnosis². Clinical awareness of solitary fibrous tumour as a rare cause of intraperitoneal abdominal masses should be emphasized.

References

1. Vallat-Decouvelaera V, Dry SM, Fletcher CDM. Atypical and malignant solitary fibrous tumours in extra thoracic locations. Evidence of their comparability to intra-thoracic tumours. *Am J Surg Pathol* 1998 22(12):1501-1511.
2. Gangopadhyay K, Taibah K, Manohar MB, Kfoury H. Solitary fibrous tumour of the para-pharyngeal space; A case report and review of the literature. *Ear Nose Throat J* 1996 75:681-684.
3. Gunhan O, Yildiz FR, Celasun B, Onder T, Finci R. Solitary fibrous tumour arising from sublingual gland; Report of a case. *J Laryngol Otol* 1994 108:998-1000.
4. Ramdial PK, Nadvi S. An unusual cause of proptosis; orbital solitary fibrous tumour; Case report. *Neurosurgery* 1996 38:1040-1043.
5. Fisher C, Bisceglia M. Solitary fibrous tumour of the spermatic cord. *Br J Urol* 1994 74:798-799.
6. DeBacker CM, Bodker F, Putterman AM, Beckman E. Solitary fibrous tumour of the orbit. *Am J Ophthalmol* 1996 121:447-449.