

Anterior (Corneal) Trabeculectomy for Neovascular Glaucoma

I A SAHAF

*Institute of Ophthalmology King Edward Medical College & Mayo Hospital Lahore
Correspondence to Dr. Inwan Akram Sahaf, Associate Professor*

The control of IOP in patients with neovascular glaucoma has always been difficult and results are frustrating. This study presents a modification to original technique of trabeculectomy with Mitomycin C by dissecting further into clear cornea and avoiding fibrovascular tissue in the angle. This helps to decrease the chances of trabeculectomy failure. In this study 22 eyes of twenty two patients with neovascular glaucoma were treated with this modification. Almost all the patients were symptom free. Closure of created fistula was seen only in one patient. The complications seen were minimal. This technique has a good potential for further applications as well.

Key words: Nasovascular glaucoma, anterior trabeculectomy

Neovascular glaucoma presents one of the most challenging problems an ophthalmologist has to face. New vessels accompanied by connective tissue sweep across the surface of trabecular meshwork thereby physically blocking the drainage of aqueous. Later the shrinkage of the fibrous membrane results in the forward pulling of the iris against the peripheral cornea (PAS), thereby resulting in angle closure glaucoma.

Neovascularization of iris (rubeosis irides) result from a multitude of diseases, the most important being CRVO and diabetic retinopathy. Chronic uveitis, intraocular tumours, chronic systemic venous stasis, radiotherapy, chronic carotid occlusion² and ophthalmic artery steal syndrome³ are some of the other causes.

Vasogenic factors produced in response to ischemia and inflammation have been thought to be the cause of the process.

Once the fibrovascular process has involved the angle and pressure has risen, it becomes nearly impossible to control the intraocular pressure even with the maximum medical treatment. Different drainage⁴ and destructive procedures⁵ have been tried with inconsistent results.

A new approach to this difficult problem has been devised viterctomy⁶ and endo lasers⁷ have been tried, whereby the filtration pathway bypasses the neovascular proliferation in the angle hence the closure of the filtration is prevented. This is achieved by creating filtration fistula in the cornea away from the limbus and angle. This fistula is covered by the conjunctiva pulled down onto the cornea from the fornix to create a filtration bleb.

Materials and methods

Patients Recruitment and Screening

All the adult patients both males and females with uncontrolled neovascular glaucoma on topical medications with painful blind eyes were included in the study. The patients who have had previous surgeries were excluded. Similarly one patient with intraocular tumour was excluded. Patients with uveitis and with still active disease were not included.

Preoperative assessment of the patients was made. Patients had their systemic problems like diabetes, hypertension etc controlled by a physician.

Intraocular pressure was noted with and without treatment. A preoperative level of less than 15 mm of Hg was aimed at the time of the surgery with maximum medical therapy including Diamox, beta blockers, with steroids and atropine to reduce inflammation. Other intraocular diseases like active uveitis and intraocular tumours were excluded. Local anaesthesia was used in all the patients.

Operative Procedure

1. A fornix based conjunctival flap was raised. Limbal incision was made from 10'O clock to 4'O clock position. Conjunctiva along with Tenons capsule was raised up to about 10 mm away from the limbus. This was needed to provide laxity for the conjunctiva to be able to be pulled onto the cornea later in the surgery.
2. Corneal epithelium was removed in a semicircle of radius 4 mm centred at 12'O clock of the limbus. This was achieved by Barde Parker knife.
3. The area under the conjunctival flap and denuded cornea were treated with Mitomycin C up to five minutes.
4. A partial thickness scleral flap was raised starting from 2-3 mm away from the limbus. This was extended across the limbus into the corneal substance up to 3.5 mm.
5. The area under the conjunctiva, scleral flap and denuded cornea were all treated with Mitomycin C⁸ for 5 minutes followed by thorough irrigation with normal saline.
6. A paracentesis at 8'O clock in right eye and 5'O clock in left eye was secured. The eye was filled with methylcellulose. Full thickness corneal button 1mm into 2 mm was removed from the bed of sclerocorneal flap 2.5 mm away from the limbus. No bleeding was encountered with maneuver. No cauterization of angular vessels was needed. Fluid was injected through paracentesis incision and patency of fistula

Anterior (Corneal) Trabeculectomy for Neovascular Glaucoma

was confirmed. No peripheral iridectomy was performed.

7. The conjunctiva was then pulled up across the limbus. The edge was stitched to the corneal stroma at the edge of area denuded of epithelium. Interrupted stitches from the margin of Tenons capsule to the corneal stroma were passed and knots buried under the conjunctiva. (See Key Diagram).
8. Methylcellulose was aspirated through the paracentesis incision and fluid was injected till it filled the bleb.

Post operative care and Follow-up

Post operative patients were put on intensive topical steroids as well as atropine eye drops three times a day. All anti glaucoma treatment was discontinued. Patients were discharged on 5th postoperative day after noting intraocular pressure and activity in the anterior chamber.

Patients were then monitored twice a week for two weeks and then fortnightly for three months followed by six monthly visits.

Results.

Shallow AC was noted in all patients on post Op-day

Blebs: -Large blebs upto 8x8 mm were noted which gradually reduced to 5x5 mm.

Pain:- two patients reported eye pain treated with short term analgesics.

Hyphaema:- two patients one needed evacuation.

Pressures:- mean post Op 8-12mm at 6 months.

Pressures rise one year to mean 16 mm.

Two had a rise to 23 mm

One had a fistula closure (43 mm)

Pressure rise has attributed to persistent leakage from new vessals on iris.

As all patients were blind a visual progress was not on the cards.

All patients except one were comfortable post op & were relieved of high pressure symptoms like pain.

Discussion

Neovascular glaucoma is very refractory to conventional surgeries. Heroic procedures like Vitreoretinal surgeries,⁹ cyclocryoblation¹⁰ cyclophotocoagulation¹¹ and valvular implants¹² have all been tried. The main reason for failure of surgery in rubeotic glaucoma has been the vessel & fibrous tissue proliferation in angle following surgery⁹. Any insult to the angle increases vascular proliferation and may lead to hyphaema as well and Uveitis. Both result in closure of fistula.

The study carried out at NMC Multan and Institute of Ophthalmology, Mayo Hospital Lahore has given very encouraging results. Almost all patients had relief of symptoms. All pressures were controlled very well. Complications were minimal.

Advantages have been simplicity of procedure requiring no additional instruments. All surgeons doing trabeculectomy

can adapt to new procedure. Other applications include all filtration procedures where we want to avoid the angle or the preipheral iridectomy e.g. Ch Uveitis, congenital glaucoma, plateau iris syndrome, aphakic glaucoma etc.

Conclusion

In the end we conclude that the new procedure is a safe & effective way of dealing with neovascular glaucoma which can be adopted by any eye surgeon without special training & equipment. There is large potential of additional applications of the procedures which can be worked up. A multi centric study is needed for long term and better conclusions.

Age Distribution

Age in years	n=	%age
20-4-	3	13.6
40-60	14	63.63
60-up	5	22.75
Total	22	100

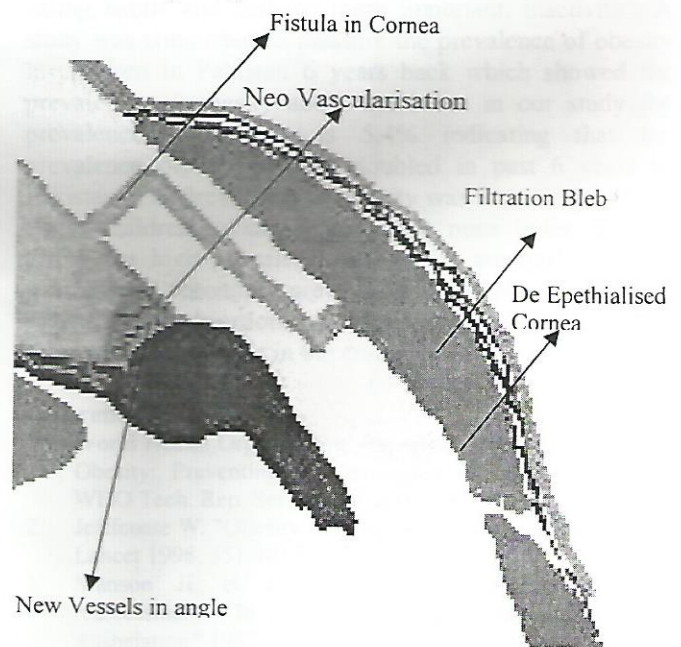
Pre operative untreated IOP levels

IOP Level mm Hg	n=	%age
20-30	7	31.8
30-40	9	40.9
40-50	6	27.27
50-up	0	0

Post operative IOP Level at six months

IOP Level mm Hg	n=	%age
< 10	4	18%
10-15	13	59%
15-20	2	9 %
>20	3	13.6%

Figure: Anterior Chamber Trabeculectomy Key Diagram



References

1. D'Hermies F, Meyer A, Morel X, Lumbroso L, Levy C, Desjardins L, Frau E, Halhal M, Elmaleh C, Berges O, Gauthier JB, Ferrand R, Delacroix S, Schlienger P, Schwarz I, Habrand JL, Mazon A, Renard G. [Neovascular glaucoma following proton-bean therapy]. *J Fr Ophthalmol* 2001 Jan;24(1):95-101 Quevas-Lestienne C, Chiquet C, Zech J, Burillon C, Trepsat C, Denis P. [Neovascular glaucoma diagnosed following carotid endarterectomy]. *J Fr Ophthalmol* 2000 Jun;23(6):599-602
2. Milea D, Cassoux N, Lehoang P, Gerber S, Marsault C, Piette JC, Amoura Z, Kieffer E, Lehoang P. Neovascular glaucoma after bypass surgery in Takayasu's disease. *Eye* 1999 Dec;13 (Pt 6):786-9
3. Scott IU, Alexandrakis G, Flynn HW Jr, Simdddy WE, Murray TG, Schiffman J, Gedde SJ, Budenz DL, fantes F, Parrish RK. Combined pars plana vitrectomy and glaucoma drainage implant placement for refractory glaucoma. *Am J Ophthalmol* 2000 Mar;129(3):334-41
4. Bartz-Schmidt KU, Thumann G, Psichias A, Krieglstein GK, Heimann K. Pars plana vitrectomy, endolaser coagulation of the retina and the ciliary body combined with silicone oil endotamponade in the treatment of uncontrolled neovascular glaucoma. *Graefes Arch Clin Exp Ophthalmol* 1999 Dec;237(12):969-75
5. Kirshhof B. The contribution of Vitreoretinal surgery to the management of refractory glaucomas. *Curr Opin Ophthalmol* 1999 Apr;10(2):117-20
6. Pischias A, Bartz-Schmidt KU, Thumann G, Krieglstein GK, Heimann K. Vitreoretinal surgery in the treatment of neovascular glaucoma. *Kin Monatsbl Augenheilkd* 1999 Feb;214(2):61-70
7. Mietz h, Raschka B, Krieglstein GK. Risk factors for failures of trabeculectomies performed without antimetabolites. *Br J Ophthalmol* 1999 Jul;83(7):814-21
8. Lee SC, Kim GO, Kim DH, Kim SH, Kwon OW. Endoscopic laser photocoagulation for management of neovascular glaucoma. *Yonsei Med J* 2000 Aug;41(4):445-9
9. Nicaeus T, Derse M, Schlote T, Erb C, Rihrbach JM, Thiel HJ. Cyclocryocoagulation in treatment of therapy refractory glaucoma: a retrospective analysis of 185 cryocoagulation procedures. *Kin Monatsbl Augenheilkd* 1999 Apr;214(4):224-30
10. Detry-Morel M, Gilon B. Treatment of refractory glaucoma with transscleral cyclo-photocoagulation using a Diode laser. *Bull Soc Belge Ophthalmol* 1999;272:45-52
11. Englert JA, Freedman SF, Cox TA. Contact transscleral diode cyclophotocoagulation for refractory glaucoma. *J Glaucoma* 1999 Feb;8(1):3-7