

Surgical Management of Massive Nasal Polyps

Ullah N.,¹ Malik T.L.² and Pal M.B.³

Address for Correspondence: Dr. Mansoor Basir Pal, Department of Otorhinolaryngology Head & Neck Surgery, King Edward Medical University Unit II / Mayo Hospital Lahore

Objective: To assess the different surgical procedures used for management of bilateral massive nasal polyps.

Design: Descriptive Study.

Place and duration of Study: Study was conducted in Otorhinolaryngology Department Unit-II King Edward Medical University and Mayo Hospital Lahore, from January 2009 till January 2010.

Patients and Methods: Patients with massive bilateral nasal polyps were studied. Of these 60 patients were included in the study, irrespective of age and gender. Data including age, gender, socioeconomic status, signs, symptoms, and imaging studies (Computed Tomography and / or Magnetic Resonance Imaging) were noted for the study. Pre and postoperative medical treatment, surgery performed, follow-up; residual / recurrence disease and revised surgery performed were also recorded.

Results: In the series bilateral nasal polyposis disease of middle age group, with more male patients (60%) Allergic Rhinitis (100%), nasal obstruction (100%) nasal discharge (98%) post nasal drip (98%), Sinusitis (100%) were the commonest presenting features. Surgical management was preferred in all cases as medical management had failed. Endoscopic Sinus Surgery in all cases was done. Recurrence / Residual disease was same in only 11 percent cases.

Conclusion: Bilateral nasal polyposis is disease of middle age people, males are affected slightly more. Sinusitis and allergic rhinitis are associated symptoms. Medical management with steroid nasal spray is the first line of treatment, if the symptoms and signs persists then surgery is the main treatment. Functional endoscopic surgery with or without powered devices is the surgical method of choice in NP.

Key Words: Allergic rhinitis, Bilateral Nasal Polyposis, Endoscopic Surgery (FESS).

Introduction

Nasal Polyposis is a chronic disease with symptoms similar to that of rhinitis. Nasal obstruction is the most frequent complaint, together with an olfactory impairment.¹

Although the aetiology of Nasal Polyposis remains unknown, many aspects of the disease, its risk factors, and associated diseases have been extensively studied.²

The management of patients with nasal polyps has to be done frequently by otorhinolaryngologists, who are more interested in rhinology.

The reported prevalence seems to vary between 2.5 per cent and 4.3 per cent of the population in Pakistan,³ Larsen and Tos estimated an incidence of 0.627 per thousand per year in Denmark and 2.11 percent in France.⁴ There is general agreement that the incidence rises with age and that there is a male predominance.⁵

The reported prevalence of nasal polyps in asthmatic patients varies between 6.7 per cent and 13 per cent while the prevalence of asthma in patients with nasal polyps has been reported to be as high as 45 per cent.⁶

In 1968 Samter described the clinical triad of asthma, aspirin sensitivity and nasal polyposis. (ASA triad).⁷

The association of nasal polyposis in cystic fibrosis is well documented. Hadfield *et al.* studied 211 adults with cystic fibrosis and found nasal polyps in 37 percent.⁸

Allergy has been known to be the underlying cause of nasal polyps. The presence of eosinophilia, mast cell degranulation, and high levels of IgE suggest an allergic bases for nasal polyposis. This has been challenged by a number of clinically based studies.⁹

The syndrome of nasal polyposis combined with positive Aspergillus cultures was recognized by Safirstein in 1976.¹⁰

Due to many aetiological factors and its association with other diseases medical treatment usually doesn't work in bilateral nasal polyps. Surgery is only option to get relief of the symptoms.

This paper aims to summarize the present state of knowledge relating to nasal polyps with regard to the surgical treatment.

Patients and Methods

Patients who had polypectomy done by FESS (Functional Endoscopic Sinus Surgery) and also the new patients with bilateral massive nasal polyps who were operated by FESS were seen. 60 of the patients who completed the follow up plan were selected. The study conducted from January 2009 till January 2010, irrespective of age, gender, socioeconomic status and geographical origin. Patients who could not complete the follow up plan were dropped.

Non-probability sampling technique was adopted in this Descriptive type of study.

Study was conducted in Department of Otorhinolaryngology and Head and Neck Surgery in KING EDWARD MEDICAL COLLEGE and MAYO HOSPITAL LAHORE. Data including name, age, gender, address, socioeconomic Status, signs and symptoms and imaging studies(CT and/or MRI) were recorded on performa.

Surgery performed, pre-operative and postoperative treatment, follow up (after one week then one month and later three monthly for at least 8 months), residual disease (within 6 months of surgery), recurrence of disease (after 6 months of surgery) and revision surgery for residual / recurrent disease was also recorded. Statistical software SPSS – 10.0 was used for data analysis. Ratio (M:F) for gender distribution and mean + SD for age distribution.

Results

60 patients with Bilateral massive nasal polyps were evaluated, 80% were between 21 years and 60 years of life (Table 1). Maximum age was 70 years and minimum 16 years. Mean age was 35.5 years and median age was 32.4 years. Male (60%) to Female (40%).

Table 1: Characteristics.

Characteristics	Numbers	%
Age Groups		
10 to 20 years	8	13.3
21 to 40 years	27	45
41 to 60 years	21	35
> 60 years	4	6.7
Sex		
Male	36	60
Female	24	40

On CT Scan bilateral involvement of Ethmoids and Nasal cavities was seen in 90% of cases, while orbital involvement was noted in 10% of cases and intracranial extension in 2 cases (3.3%). MRI was done in only 2 cases (3.3%) having intracranial involvement (Table 2).

Nasal obstruction was the most common feature seen in all cases (100%) while nasal discharge (98%) and post-nasal drip (98%) the next most common findings (Table 3).

Hyposmia / anosmia seen in 100%.

Among the extranasal involvement proptosis (3 cases). Rhinitis was found in all cases (100%).

All cases were managed surgically, treated with FESS (Function Endoscopic Sinus Surgery) and in only 2 cases having intracranial involvement needed neurosurgical assistance.

Recurrence / Residual disease was seen in 11% cases in 8 months follow up and Functional Endoscopic Sinus Surgery was performed again in the recurrent cases.

Table 2: CT Scan Findings.

	Numbers	%
Unilateral involvement of nasal cavity	6	10
Bilateral involvement of nasal cavity	54	90
Orbital involvement via lamina paparycea	6	10
Intracranial extension via cribriform plate	2	3.3

Table 3: Clinical features.

Clinical Features / Treatment	Numbers	%
Nasal Signs / Symptoms		
Nasal Obstruction	60	100
Nasal discharge	59	98
Post-nasal drip	59	98
Hyposmia / anosmia	60	100
Extranasal and Paranasal Sinuses Sings / Symptoms		
Facial pain	52	87
Proptosis	3	5
Headache due to Intracranial involvement	2	3.3

Table 4: Treatment.

	Numbers	%
Pre-operative Nasal Steroids	48	80
Functional endoscopic sinus surgery	60	100
Postoperative medical treatment	60	100
Residual / recurrent disease	7	11
Revised functional endoscopic sinus surgery	7	11

Discussion

Nasal Polyposis is a common condition of the upper airway, the cause remains unknown. It seems likely that nasal poly-
 ps is result of number of pathological processes.¹¹

This study describes the frequency of condition and highlighted the surgical management of NP to minimize the complications and recurrence.

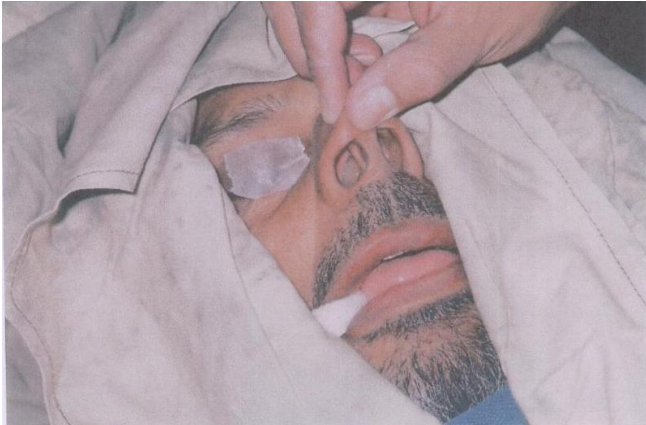


Fig. 1:

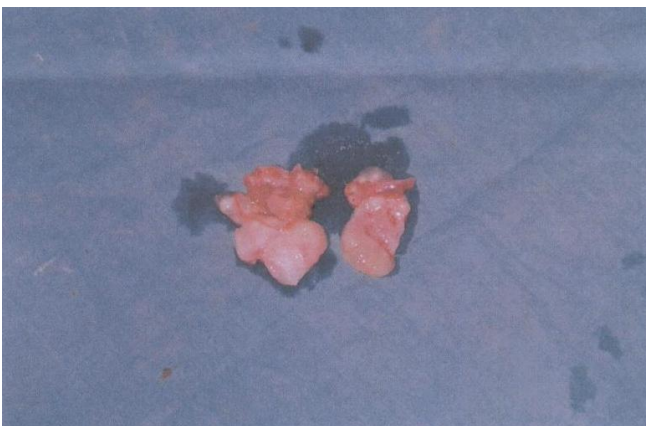

Fig. 2:

Medical treatment with corticosteroids is effective in most patients.¹² This is most appropriate regime, steroids should be the first line treatment in the majority of patients.¹³ Recurrence after surgery remain problematic and repeated procedures are not uncommon. There are different surgical techniques. Despite this, endoscopic surgery is the choice of many surgeons as the visualization facilities accurate removal of polyps with the preservation of vital landmarks.^{14,15}

In this study majority of patients were middle aged with mean age 35.5 years which is similar to study reported in International Literature.

Male preponderance general distribution in one study is 3:2 comparable with most local studies.^{16,17}

The CT Scan suggested bilateral involvement of Ethmoidal Sinus in 90% cases comparable to other studies.¹⁸ The surgical procedure involved nasal and Ethmoidal clearance of disease in all cases. Recurrence is the main problem in surgical management of bilateral nasal polyps with routine procedure. Current surgical technique FESS is developed to control this high recurrence rate.¹⁹

Successful management of this condition is an understanding of the inflammation occurring at a mucosal level

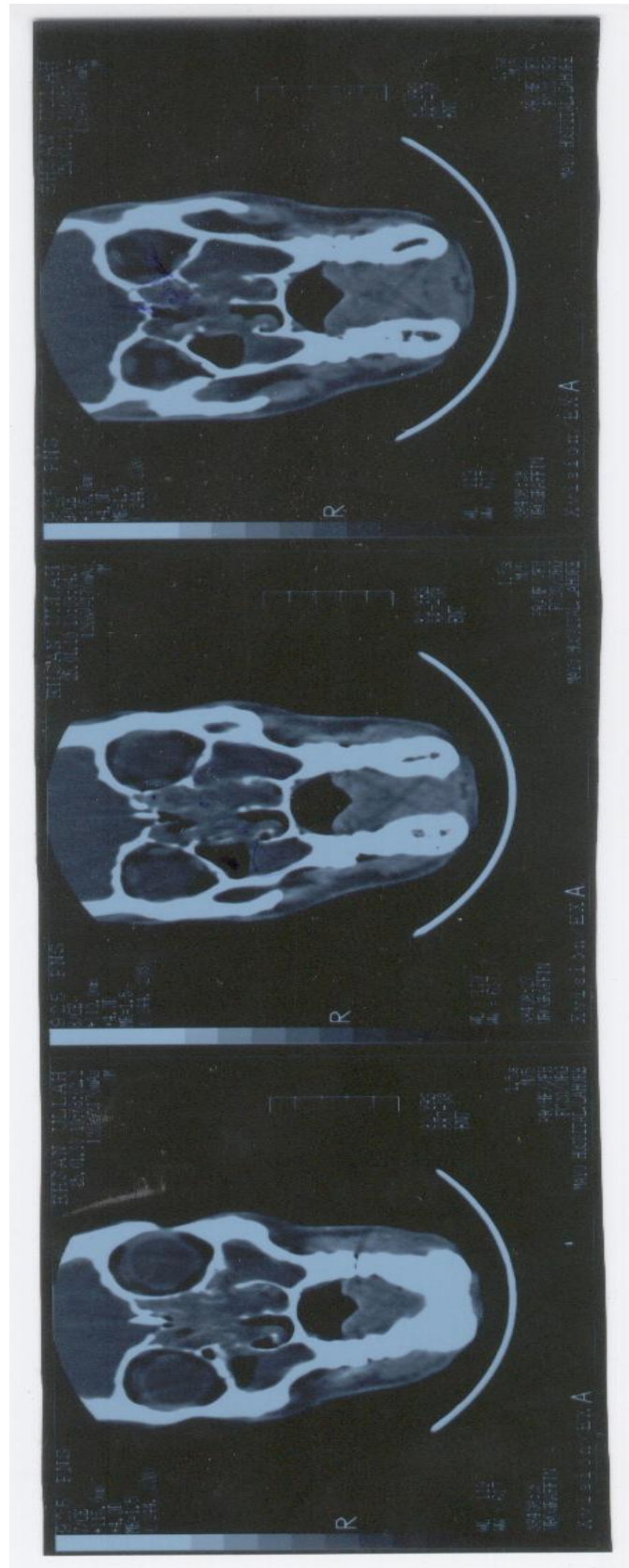

Fig. 3:

and the genetic control of that process. Medical treatment that can reverse this process will make surgical Nasal polypectomy redundant. With the current state of knowledge this is likely to be some years in the future.

Till now nasal polypectomy surgery with endoscope assistance (FESS) and use of powered (Debrider, Laser) tools is treatment of choice in massive nasal polyps.

FESS has its merits and demerits but over all results show considerable improvement in reducing the recurrence rate.²⁰

In the traditional surgery with head light and simple polypectomy the recurrence is as high as 30-40%. Functional Endoscopic Sinus Surgery with or without Debrider / Laser has reduced the recurrence of nasal polyps to 7 – 10%, which is clear improvement in the results.

In our study the recurrence rate in 8 months follow up was as low as 11%, which is comparable to the other studies.²¹

Conclusion

Bilateral Nasal Polyps were seen in middle aged males presenting with nasal obstruction, nasal discharge and post nasal drip. Use of Local Nasal Steroid Sprays has limited value in Massive Nasal Polyps. Routine Surgery with head light has very high recurrence rate.

Functional Endoscopic Sinus Surgery proved to be the most important surgical modality of treatment. Topical Steroid Pre and Post Operatively Control the Recurrence.

References

- Bonfils P, Jankowski R, Werner A. Smell dysfunction in nasal and paranasal sinus disease: a review of the literature (I). *Ann Otolaryngol Chir Cervicofac* 2001; 118: 131–42.
- Keith P, Dolovich J. Allergy and nasal polyposis. In: Mygind N, Lildholdt T, eds. *Nasal Polyposis. An inflammatory Disease and its Treatment*. Copenhagen: Munksgaard, 1997; 68–77.
- Lamblin C, Gosset P, Salez F, Vandezande LM, Perez T, Darras J, et al. Eosinophilic airway inflammation in nasal polyposis. *J Allergy Clin Immunol* 1999; 104: 85–92.
- Radenne F, Lamblin C, Vandezande LM, Tillie-Leblond I, Darras J, Tonnel AB, et al. Quality of life in nasal polyposis. *J Allergy Clin Immunol* 1999; 104: 79–84.
- Larsen K, Tos M. The estimated incidence of symptomatic nasal polyps. *Acta Otolaryngol* 2002; 122: 179–82.
- Ragina M, Serrano E, Klossek JM, Crampette L, Stoll D, nasal polyposis in France : the ORLI group experience. *Rhinology* 2002; 40: 75–9.
- Samter M, Beers RF. Intolerance to aspirin. Clinical studies and consideration of its pathogenesis. *Ann Intern Med* 1968; 104: 5–13.
- Hadfield PJ, Rowe Jones JM, Mackay IS. The prevalence of nasal polyps in adults with cystic fibrosis. *Clin Otol* 2000; 25: 19–22.
- Settipane GA, Chaffe FN. Nasal polyps in asthma and rhinitis: a review of 6037 patients. *J Allergy Clin Immunol* 1976; 50: 126–32.
- Millar JW, Johnston A, Lamb D. Allergic aspergillosis of the maxillary sinuses. *Thorax* 1981; 36: 710.
- Kin MY, Nahm DH, Suh KS, Park HS, IgE production from the nasal polyp tissue: comparison between atopic and non-atopic subject. *Korean J Int Med* 1998; 13: 83–8.
- Dingsor G, Kramer J, Olshot R, Soderstrom T. Flunisolide nasal spray in the prophylactic treatment of nasal polyposis after polypectomy. A randomized, double blind, parallel placebo controlled study. *Rhinology* 1985; 23: 49–58.
- Mian MY, Kamal SA, Senthilkumaran G, Abdullah A, Pirani M. Allergic fungal rhinosinusitis: current status. *Pak J Otolaryngol* 2002; 18: 36–40.
- Akhtar MR, Ishaque M, Saadat Ullah. Aetiology of nasal polyp: a study of 200 cases at Combined Military Hospital, Rawalpindi. *Pak J Otolaryngol* 2004; 20: 9–11.
- Klossek JM, Peloquin L, Friedman WH, Ferrier JC, Fontanel JP, diffuse nasal polyposis: postoperative long-term results after endoscopic sinus surgery and frontal irrigation. *Otolaryngology–Head Neck Surg.* 1997; 117: 355–61.
- Kalimullah Thahim, Mahboob Afzal jwaid and M. Saleem Marfani. Presentation and Management of Allergic Fungal Sinusitis. JCPSP 2007, Vol. 17 (1); 23–27.
- Schuybert MS. Allergic fungal sinusitis. *Otolaryngol Clin North Am* 2004; 37: 301–26.
- Vento SI, Ertama LO, Hytonen ML, Wolff CH, Malmberg CH. Nasal polyposis: clinical course during 20 years. *Ann Allergy Asthma Immunol* 2000; 85: 209–14.
- Hosemann W. Surgical treatment of nasal polyposis in patients with nasal polyposis with aspirin intolerance. *Thorax* 2000; 55 (suppl 2): S87–90.
- Lund VJ. Health related quality of life in sinonasal disease. *Rhino-Laryngol* 2001; 39: 182–6.
- Jacobsen J, Svendstrup F. Functional endoscopic sinus surgery in chronic sinusitis – a series of 237 consecutively operated patients. *Acta Oto-Laryngologica* 2000; (suppl 543): 158–61.