

# Surgical Treatment of Arthritis of First Carpometacarpal-Joint (CMC)

W A KHAN S M H JAFRI M PERVAIZ A GHAFAR S RAZIQ

Hand Upper Limb Surgery Centre, Lahore

Correspondence to: Lt. Col. S.M. Hassan Jafri (e.mail: hand\_arm\_surgery@hotmail.com)

A study of nine cases suffering from osteoarthritis of 1<sup>st</sup> carpometacarpal (trapeziometacarpal h joint) joint was done. Due to disabling pain and failure of non-surgical treatment these patients underwent surgery. Post-surgical evaluation to see the results as regard to pain, movement and strength was done. To the best of our knowledge this is the first study in Pakistan as regard to study of surgery on 1<sup>st</sup> carpo-metacarpal joint arthritis.

**Key words:** Arthritis, first carpometacarpal joint, arthroplasty

Wrist pain is a common problem in the old population. However, post-traumatic wrist pain is also common in young people. Wrist pain can be due to problems of soft tissue or osseous problems. These causes can be subdivided into static and dynamic causes. Among dynamic causes wrist instabilities are important. One of the common causes of radial sided wrist pain is osteoarthritis of 1<sup>st</sup> CMC joint.

## Methods and material

In all patients plain x-rays of 1<sup>st</sup> CMC joint, especially Bette's view, showed osteoarthritis of the joint. All the patients were having pain in the joint, which increased on axial compression of joint. All the patients were having weakness in pinch. Before reporting to us patients had undergone non-operative management including use of non-steroidal anti-inflammatory drugs, intra-articular steroid injections, splintage of joint, wax bath fomentation etc. Among nine patients, two patients had arthrosis due to post-fracture effects of fracture of base of 1<sup>st</sup> metacarpal. In both cases fractures were producing intra-articular incongruity of base of first metacarpal. Two cases were suffering from rheumatoid arthritis. Remaining five cases were due to primary osteoarthritis of 1<sup>st</sup> CMC joint. Six cases were of dominant thumb. Three were females while six were male. The average age at the time of surgery ranged from 40 years to 70 years. Among five cases of primary arthrosis, three were strenuous workers (farmer/labourer) while two were sedentary workers (house wife/office worker). Surgical technique involved excision of trapezium and use of flexor carpi-radialis tendon for ligament reconstruction and interposition arthroplasty. No discrepancy was noted in wrist flexion after flexor carpi-radialis tendon usage.

## Results

The follow up ranges from 2-4 years. Mobility in all thumbs improved. Preoperatively all the thumbs could not touch the base of the little fingers due to restriction of movement at 1<sup>st</sup> CMC joint. After surgery thumbs of eight patients could reach the base of the little finger while one could reach the crease of the proximal interphalangeal joint. Postoperatively the index-thumb metacarpal web angle increased to 41°-45°. Preoperatively grip strength

ranges from 10 to 16 kilograms. Postoperatively it increases from 18 to 25 kilograms. Preoperative pinch strength ranges from 2Kg to 2.8 Kg. It increased postoperatively from 3.5kilograms to 5kgs. On examination, no patient had hypersensitivity of scar. All patients except one had complete relief of pain. Only on patients complained of mild discomfort on strong pinch compression. All patients were satisfied as far as common daily routine work is concerned especially combining of hair, writing, eating, opening jars and doors etc. Only one patient suffered from mild reflex sympathetic dystrophy. However, this patient recovered fully after a supervised extensive hand physiotherapy program. There was no scapho-metacarpal impingement

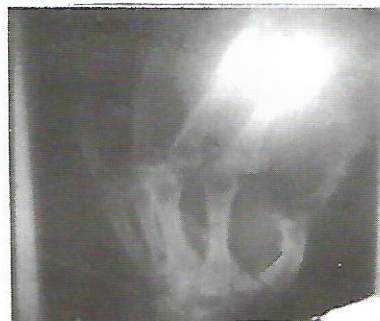

Fig 1: Preoperative x-ray showing severe arthritis of 1<sup>st</sup> CMC joint with subluxation of joint

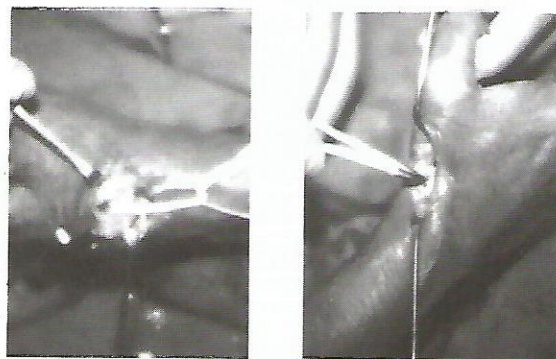


Fig 2: Operative pictures showing tendon for ligament reconstruction and inter position in the space created by excision of trapezium.

### Discussion

Painful arthritis of first carpometacarpal joint is a disabling problem. Since this joint supports the thumb mobility hence disability of the joint affects the movements of thumb. Most of the patients spend their time with conservative management without any advantage. In severe cases, even the routine daily function like writing, holding spoon etc., are also affected badly. Surgery is indicated in such cases when pain could not be relieved with conservative management including splintage and intraarticular steroid injections. Our results show that surgery gives good results. Both the soft tissues and artificial implants are being used. Recognition of silicone particulate synovitis has favoured the trend more towards soft tissue arthroplasty procedures. The bony geometry of the joint does not provide full stability to the joint. Maximum stability is provided by the soft ligamentous structures of the joint. Our technique involves removal of the diseased bony articular structures with ligamentous support to the joint without restriction of joint mobility. In our surgical technique we have modified Burton and Pellegrini method.

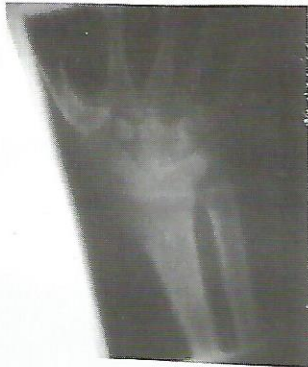

Fig. 3. Postoperative x-ray showing excision of trapezium.

To obtain success in arthroplasty in addition to resection of articular surfaces reduction of dorsolateral subluxation is mandatory. This subluxation is secondary to capsular

laxity and attenuation of joint ligaments. The subluxation is further aggravated by pull of abductor pollicis longus. This subluxation gives rise to compensatory adduction of metacarpal and hyperextension of MP joint. To control this deformity axial stabilization is needed. In our method of passing half of FCR through medullary canal of metacarpal then out of a readily drilled hole and at the end by knotting it to rest half of tendon produces an ulnarward force on the base of metacarpal. This reduces the dorsolateral subluxation of metacarpal base. When the subluxation is reduced all deforming forces vanish and hence swan neck deformity of thumb disappears. Our method of knotting of two halves of FCR also gives stability to metacarpal base during pinch function of thumb the passage of FCR tendon through medullary canal (i.e., axial axis) of metacarpal and then through the radial hole gives stability to the new joint without intervening with the multidirectional movements of this joint.

On conclusion surgical technique involving reconstruction of ligament with interpositional arthroplasty provides excellent pain relief, sufficient motion and strength for arthritis of 1<sup>st</sup> carpometacarpal joint which does not respond to conservative management.

### References

1. Caryer PR, Bentouli B, Dysert PA. Silicon carpal rubber implants. A Study of the incidence of late osseous complications. *J Hand Surg.* 1986; 11A: 639-44.
2. Cooney WP III, Chad Eys. Biochemical analysis of static fonts in the thumb doing tonetion. *J Bone Joint Surgery* 1977; 59A: 27-36.
3. Buryon RI, Pellegrini VD JR. Surgical management of basal joint arthritis of the thumb Part II ligament reconstruction with tendon interpositional arthroplasty. *J Hand Surgery* 114: 324-32.
4. Fromsen AL. Tension arthroplasty of the trapeziometacarpal joint. *Clin Orthop* 1970; 70: 191-99.
5. Sigfusson R, Lundborg G. Abductor pollicis longus tendon arthroplasty for treatment of arthritis in the first carpometacarpal joint. *Scand J Plast Reconstr Hand Surg* 1991; 25: 73-77.