

# Operative Experience using KTP-532 Laser for Acoustic Neuromas

K MAHMOOD F NATH

*Department of Neurosurgery General Hospital Middlesbrough, England*

*Correspondence: Dr Khalid Mahmood Assistant Prof. Neurosurgery King Edward Medical College Lahore*

The idea of study was to demonstrate the use, safety and advantage of Laser dissection in surgical treatment of acoustic neuromas. The authors experience of 10 patients in whom laser surgery was used in acoustic neuromas is presented, with emphasis on surgical technique employed. Tumour size varied from 1.5 cm to 4cm. Cystic tumours and < 1.5cm tumours were excluded. Assessment was done according to haemostasis, operating time and morbidity. The KTP laser had good vaporizing ability with limited charring or smoke. Bleeding was significantly reduced during debulking compared to conventional methods of tumour excision. There was no evidence to suggest late complications due to vascular damage or nerve deficit.

**Key Words:-KTP Laser, Acoustic neuroma, Haemostasis**

There are different techniques of excising cerebellopontine angle acoustic neuromas. Conventional methods include microsurgical techniques using sucker, cavitron ultrasonic surgical aspirator, bipolar and monopolar diathermy with cutting loops, microdissection and excision.

Large tumours have to be debulked, before finally excising the capsule. If tumor consistency is soft, it can be sucked. Cavitron ultrasonic surgical aspirator works only for soft and firm tumours. Loops with cutting monopolar diathermy can be used for hard tumours but it can cause damage to surrounding structures from spread of current and is not recommended near brain stem. All conventional methods of debulking cause bleeding/ ooze from tumour bed. This has to be dealt with immediately, before more debulking can be performed.

Laser means light amplification by stimulated emission of radiation. The waves of electromagnetic energy released are identical in length (monochromatic) and synchronous in time and space (coherent). When light energy impacts on biological tissues, one of three energy transformations may occur. These are to chemical energy, mechanical energy or to heat. The biophysical interaction that is most often desired at laser-tissue interface is transformation of light to heat energy. The practically instantaneous elevation of intracellular water temperature to boiling point produces vaporization and explosion of the cell, with obliteration of extracellular space. Experimentally, it has been shown that the degree of thermal trauma, in terms of cell viability is less with laser than with conventional methods of hemstatic tissue incision such as monopolar or bipolar cautery. Similarly, the degree of mechanical disruption using highly focused laser for incision has been shown to be less than with conventional means of tissue incision using steel blade. It appears therefore, that laser offers a more contained method for incision and coagulation of biological tissues than has heretofore been available.

## Material and methods

This retrospective study was carried out at department of Neurosurgery, General hospital Middlesbrough, England.

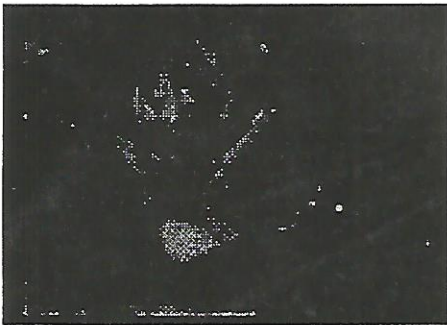
Ten patients with acoustic neuromas were operated on from May 96 to July 97 using KTP Laser. There were 4 female and 6 male patients. Age ranged from 35 to 60 years with mean of 43.7 years. Tumour size was measured by radiologist from CT and MRI scans and ranged from 1.5 cm to 4 cm with mean of 3.2cm. There were 4 moderate size (1.5-2.4cm) tumours while 6 were large size (> 2.5 cm). Only one patient had 1.5 cm tumour remaining 9 had >2cm. Cystic tumours and <1.5 cm were excluded. Anesthetist recorded operating time. All patients were followed up for one year. Assessment was done regarding haemostasis, operating time and morbidity. House and Brackmann grading scale was used to assess post operative facial nerve function. Results were compared with previously operated cases of same size acoustic neuromas by 2nd author without laser.

## Surgical technique

After general anesthesia, electrodes for facial monitor (Neurosign) are placed on the face. Patient is put on operating table in park bench position with tumour side up. Head is fixed using 3-pin Mayfield clamp. Head shave is done in retromastoid area. After usual cleansing and draping, retromastoid craniectomy is done using Hudson brace, Leksell rongeur and Kerrison punch. After opening dura in cruciate manner, cerebellum is retracted medially and is held in place with Yasargil self retaining retractor system. Microscope is brought in and tumour is located in cerebellopontine angle. After defining upper and lower poles of tumour, arachnoid dissection is done using microscissors and micro-dissector. KTP laser apparatus is brought forward. Laser probe along with sterile handle is advanced towards tumour center. Foot control for laser delivery remains under control of operating surgeon. All the operating room personnel are asked to wear protective glasses and nobody is allowed to enter theatre while laser is in use. Surgeon while working under eyepiece of microscope is automatically protected and needs not to wear protective glasses. Surgeon holds laser probe near tumour and presses the delivery foot pedal. Tumour capsule is first incised, and then tumour is exposed to

laser. It starts getting vaporized. There is some charring and smoke, which can be sucked simultaneously with left-hand sucker. Laser probe is moved to and fro and distance from tumour is increased or decreased to incorporate more and less debulking area respectively. To avoid diffraction, structures surrounding tumour are covered with wet linteen strips. After debulking, tumour capsule is mobilized and laser probe is touched to actually cut it. Laser use does not interfere with continuous facial monitoring (While bipolar and monopolar diathermy does). After tumour excision, layered closure of dura and scalp is done in routine fashion.

Laser being used to debulk tumour



Laser being used to cut tumour capsule



## Results

The KTP laser had good vaporizing ability with limited charring or smoke. Bleeding was significantly reduced during debulking compared to conventional methods of tumour excision. The facial nerve function outcome, assessed by House-Brackman grading system revealed that 85% of moderate size tumours (1.5-2.5cm) and 70% of large size tumours (2.5-4cm) achieved satisfactory (grade 1&2) functional outcome. There was no evidence to suggest late complications due to stroke or other nerve deficits. Average operating time was 4 hours for moderate size tumors without laser and 4.25 h if laser was used. Similarly, it was 5h for large size tumours without laser and 5.3h if laser was used. So there was no significant

increase in operating time with use of laser. The results compare favorably with literature describing non-laser-dissecting techniques.

## Discussion

The use of instrument in surgical practice capitalizes on its precision with minimization of trauma, both thermal and mechanical, to surrounding structures. In no surgical

Specialty is this more highly desired, than in the incision, coagulation, and removal of tissue in and around the central nervous system. Precision of incision is exploited in those situations in which nervous tissue must be violated in order to effect a physiologic result (myelotomy, cordotomy)<sup>9</sup> or to arrive at deeper pathologic structures (Tumour, cyst). Precision of vaporization is desirable when removing tissue adjacent to sensitive neural or vascular structures with minimization of thermal or mechanical damage to those elements. Precision of coagulation is essential in directing the thermal energy to those areas in which it is required while protecting the adjacent micro and macro vasculature.

CO<sub>2</sub> laser was first to be introduced in Neurosurgery. It provides cutting and vaporization but poor coagulation because of its immediate energy absorption by fluid. Argon laser is a better coagulator but is power limited. YAG laser exhibits unacceptable deep coagulation and late necrosis. An ideal laser should provide combination of vaporization and coagulation, cause superficial depth of burn and work without charring or smoke. Unfortunately no single laser is ideal. KTP-532 (Potassium titanyl phosphate) <sup>3</sup> laser was introduced in late 90s. It provides effective haemostatic cutting and vaporization. It is better coagulator than CO<sub>2</sub> laser. It causes only 2mm depth of penetration and is well suited to endoscopic procedures as well. KTP Laser with its angled, low profile, light weight hand piece, is especially useful in anatomically confined locations, where laser beam directed from an attachment, operated with a joystick mounted on operating microscope would prove awkward.

The basic laser actions of incision, coagulation, and vaporization are a function of amount of energy delivered to the tissue (radiant exposure) measured in terms of watts over surface area times time, and the reaction of that particular tissue to this quantum of energy of a certain wavelength. Although in normal tissues such as skin, muscle, dura and central nervous tissue, the response is fairly predictable, in tumour the tremendous range of variation in consistency, water content, and vascularity make each experience unique. In any event, the radiant energy is manipulated by altering the variables of power output, length of exposure and surface area at impact site. It is best to begin with low power and proceed higher as situation dictates in order to prevent excessive depth of penetration and damage to deep structures. The surface area for laser action can be increased by increasing distance between probe and target and decreased by

decreasing that distance. As surface area is increased, power density is diminished, resulting in more uniform spread of heat with less depth of penetration. Although power density can be effectively regulated by the two previously mentioned maneuvers, heat build up at impact site is more a function of length of exposure. By moving beam rapidly or slowly over tissue, thermal effects are altered.

Limitation of mechanical and thermal trauma, with minimization of surrounding edema appears to be single most important feature. In addition neurophysiologic parameters such as somatosensory and brainstem evoked potentials (facial monitoring in acoustic neuromas) can be done during tissue removal without electrical interference which happens during monopolar bipolar use. Laser probe does not cause visual impediment in limited operative field. KTP laser has greater haemostatic properties and field is clear. This is far more readily appreciated in dealing with bleeding from tumour bed.

The major disadvantage of use of laser in neurosurgery is loss of tactile input from tissue to surgeon through intermediary of instrumentation. The ability to manipulate power, surface area and exposure time enables competent surgeon to overcome this handicap and, in fact, enjoy a previously unheard degree of precision and gentleness of surgery of central nervous system.

#### Conclusion

The observations and results reported in the article demonstrate safety of KTP-532 laser in surgery of acoustic

neuromas. Easy handling, haemostasis, only 2mm depth of penetration and uninterrupted facial nerve monitoring offer a great advantage to surgical armamentarium of Neurosurgeon.

#### References:

1. Cerullo LJ, Mkrdichian EH: Acoustic nerve tumour surgery before and since the Laser: Comparison of results. *Laser surg Med.* 1987; 7(3):224-8
2. Eras J, Alberdi J: Laser Co2 in surgery of acoustic neuroma. *Neurochirurgie.* 1993; 39(1) 16-21
3. Gamache FW Jr, Patterson RH Jr: The use of the KTP Laser in Neurosurgery. 1990 June; 26(6): 1010-3; discussion 1013-4
4. Glasscock ME 3<sup>rd</sup>, Jackson CG: The Argon Laser in acoustic tumour surgery. *Laryngoscope* 1981 sep; 91 1405-16
5. Hutman S. New approaches to acoustic neuroma surgery. *J clin Laser Med Surg* 1991 Jun; 9(3): 168-75
6. Kavic MS: Lasers in surgery: a return to reason. *JSLS.* 1997 Jul-Sep; 1(3): 209-11
7. Martin C, Prades JM, Berthlon P: Significance of Lasers in surgery of cerebellopontineangle tumours *Rev Laryngol Otol Rhinol (Bord).* 1998;119(3):163-5.French
8. Nissen AJ, Sikand A : Use of KTP-532 Laser in acoustic neuroma surgery. *Laryngoscope.* 1997 Jan; 107(1): 118-21
9. Saunders ML, Young HF, Becker DP, et al. The use of Laser in Neurological surgery. *Surg Neurol* 1980; 14:1-10
10. Yung MW : A study of the intraoperative effect of Argon & KTP Laser in stapes surgery. *Clin Otolaryngol.* 2002 Aug; 27(4): 279-82