

A Study About Wafer's Distal Ulnar Resection Procedure in Post Traumatic Ulnar Positive Variant

S M H JAFRI H RAFIQ S AHMAD A GHAFAR F RAFIQ

Hand UpperLimb Surgery Centre, Pak Army, Lahore Cantt.

Correspondence to Lt. Col.SM Hassan Jafri

Ulnar positive variant produced by upward axial displacement of radius after colle's fracture can produce ulnocarpal abutment syndrome. Small ulnar positive variant (2-4mm) can be dealt with simple "wafer" procedure. The purpose of this study is to see the effects of this procedure in patients with symptomatic ulnar abutment syndrome. To the best of our knowledge this is the first study in Pakistan as regard to wafer's osteotomy effects in symptomatic ulnar-positive variant patients.

Key words: Triangular fibrocartilage, wafer osteotomy

Ulnar impaction is an important cause of pain in malunited colle's fracture. In such cases stress in ulnar deviation produces pain near ulnar head (Fig.1). Different procedures like Sauve Kapandji, ulnar head excision (Darrach), Milch shortening osteotomy (with its variations) are in practice. However, for small ulnar positive variation, a new technique for unloading the ulnar head was introduced by Felon and colleagues. This procedure, called wafer" osteomy , involves resection of 2mm-4mm thick wafer of cartilage with subchondral bone from the dome of ulnar head without effects on the ulnar collateral ligaments and radio ulnar joint relationship (Fig2,3,4).

Material and method

Wafer's ostoeotmy was carried in six patients. The follow up time range was between 6 months to one year. The main aspect of study was about pain relief and effects on pronation/supination range of movements.

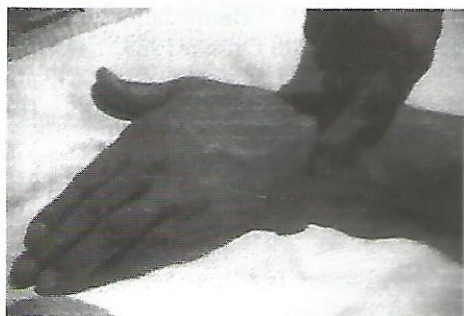

Fig. 1

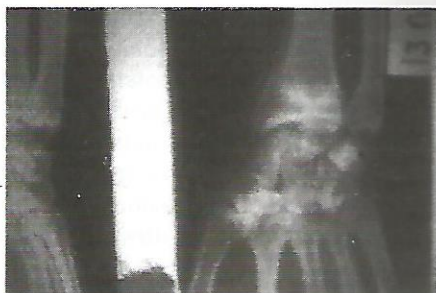

Fig.2. Ulnar +ve variant after colle's fracture union

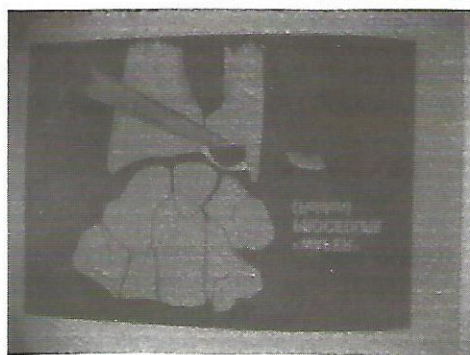


Fig.3 Wafer's osteotomy

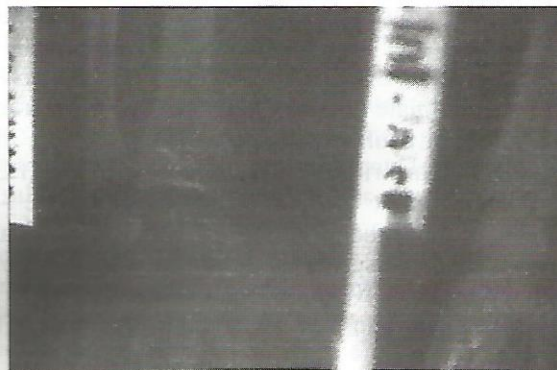


Fig. 4. X-ray after Wafer's osteotomy




Fig.5 Wafer's osteotomy

Table 1.

Case	Sex	Age (Years)	Measurement of ulnar variant in mm pre/post operative	Pain in ulnar impaction test pre/post op	Pronation Pre/Post	Supination Pre/Post
1.	M	25	3mm	+++/-	90/90	85/85
2.	M	30	2.5mm	+++/-	90/90	90/90
3.	M	32	2mm	++/-	90/85	85/85
4.	F	35	3mm	++/-	90/80	80/90
5.	F	22	3.5mm	+++/-	90/90	85/85
6.	M	40	2mm	++++/+	90/70	80/60

Results

As is evident from the Table 1 pain relief occurred in all patients except one in whom pain reduced significantly but did not disappear completely. In the same patient effects on the range of pronation and supination were bad. This patient post operatively escaped early active physiotherapy and hence may be resulting in intracapsular adhesions.

Discussion

Ulnar positive variant causes ulnar impaction. Continuous loading of triangular fibro cartilage (TFC) by ulnar head causes progressive erosion of TFC. A compression loading on TFC between carpus and long ulna wears out its central portion. Hence ulnocarpal abutment syndrome needs aggressive treatment as non as the diagnosis is made. Small variant upto 2mm-4mm can be treated satisfactorily by wafer's resection of pole of distal ulna as described by Felon, Belsky and colleagues. (Fig.2-5). This procedure has the advantage of simplicity, being an excision and an early rehabilitation as compared to other procedures like osteotomies and plate or screw fixation. This procedure is contra indication if ulnar positive variation is more than 4mm, radioulnar arthritis and in inadequency of the TFCC. There is an inherent problem with this procedure – a bleeding cancellous bone surface is exposed by wafer resection. This predisposes to intra-capsular adhesions. However this problem can be tackled satisfactorily by early mobilisation and rehabilitation programme. This

technique is effective in shifting compression load from the medial column of wrist. In cadaver experiment, Palmes and colleagues noted that normal load distribution was 84% on radius and 16% on ulnar pole through TFC. This study represents normal load on compression. Experimented shortening of ulna by 2mm changes the load to 96% on the radius and 4% on the TFC. In summary patient with definitive ulnocarpal abutment syndrome, will get relief of symptoms if the compression load on TFC through ulnar head is shifted radially by an ulnar shortening procedure.

References

1. Feldon P, Terrono AL, Belsky MR. Wafer distal ulna resection for TFC tears and/or ulna impaction syndrome. J Hand Surgery MA 1992: 731.
2. Feldon P, Terrono AL, Belsky MR. The wafer procedure partial distal ulnar resection Clin Orthop 1992; 275: 124.
3. Darrow JC Jr., Linscheid RL, Dobyns JH et al. Distal ulnar recession for disorders of the distal radio-ulnar joint. J Hand Surgery 1985; 10A: 482.
4. AK, Werner FW. Biomedamics of the distal radioulnar joint. Clin Orthop 1984; 187: 26,.
5. MiKic ZD. Detailed anatomy of the articular disk of the distal radioulnar joint,. Clin Orthop 1989; 245: 123.