

Treatment of Age Related Macular Degeneration--A trial with dietary supplement of Vitamins and Minerals

NAEEMULLAH N H BUTT M M SHAFIQUE H KLANI A A QANDEEL

Department of Ophthalmology, Fatima Jinnah Medical College, Lahore

Correspondence to Dr. Naeem Ullah, Associate Professor

To find percentage of AMD and its types among the patients visiting Eye Department of Sir Ganga Ram Hospital. and to assess the efficacy and long term implications of dietary supplement in terms of vision in AMD patients. This prospective study was started in December 2000 and up till this date 157 patients have been treated with combination of Vit-C 500 mg, Vit-E 400 i.u., Beta Carotene 15mg, Zinc Oxide 80mg, and Cupric Oxide 2 mg. It is an on going study which will last for ten years to note long term effects and defects. Both male and female patients between 41 and 89 years of age, with either wet or dry form of AMD were included. Out of 157 cases 114 had Exudative (Wet) form of AMD-Group I. Forty three cases had Non-exudative type of AMD- Group II. FFA was done to evaluate and document the type, nature and location of the disease. Dietary supplement therapy was instituted and the patients were followed every 4 weeks for six months. Therapy was abandoned after 4 months and FFA was repeated after 6 months. Later follow-up of such qualified patients was done every 4 months. Improvement in the disease and vision was better in Group-I. Ninety Three percent (93%) patients either had visual improvements by two lines with Snellen's Acuity (27%) or vision did not deteriorate (66%). But in Group II, 83% showed deterioration of vision. Only 2.4 % had visual improvement by one Snellen's line and rest 14.6% had stable vision. The modalities to treat AMD are Laser, Radiotherapy, PDT, Sub macular Surgery, Translocation of Macula and many more. Their success rate is variable. It has been reported in literature that vision may further deteriorate from complication, which they may produce in some of the eyes. The dietary supplement therapy is a safe and useful method of treating AMD and visual results are quite promising.

Key words: Macular degeneration, vitamins and minerals

Age Related Macular Degeneration (AMD) is a serious blinding disease, which usually affects the people after 40 years of age. In western world it is one of the leading causes of blindness¹. In Pakistan no statistical data is available up till now. We have started a study at Sir Ganga Ram Hospital Lahore, to find out the percentage of AMD and its types in our population. Simultaneously a trial has also been started to treat AMD with dietary supplements of Vitamins and Minerals.

Only about 30 years ago AMD was thought to be incurable disease. With the advent of Argon Laser the people used this modality to treat extrafoveal AMD of neovascular type. The success rate, although, was variable; However it was a breakthrough². The other modalities used were radiotherapy and surgical removal of Choroidal neovascular membrane from underneath the macula. In recent past Photodynamic therapy (PDT) and Transpupillary Thermotherapy (TTT) have also been included in the list. Juxtasclear injection of Anecortave acetate 15 mg is also under trial these days in USA. With dietary supplements of Vitamins and Mineral, PDT, TTT and Injection Anecortave acetate, foveal AMD can be treated.

Methods

Study of AMD was started in Department of Ophthalmology FJMC and SGRH Lahore in December 2000. Patients attending the eye out patient department were screened for AMD. It is an ongoing study that will continue till 2010. It has two aspects. One is to find the

percentage of AMD and its types and the other is to assess to the efficacy of dietary supplements for treatment of AMD in this part of world.

The patients who visited eye department had fundus examination and the patients with AMD were registered. They had a detailed evaluation of the visual function, associated ocular or systemic diseases; and had to undergo Amsler grid examination and Fundus Fluorescein Angiography (FFA) to be aware of the base line parameters. Total number of AMD patients was 157 in two years time. Group 1 was exudative variety and had 114 patients. Grade 2 dry type and had 43 patients. Dietary supplements with Vitamins and Minerals were instituted to all AMD patients. The recommended dose for the treatment of AMD³ is as follows

Vitamin C	500mg
Vitamin E	400 I.U.
β-Carotene	15 mg
Zinc Oxide	80 mg
Cupric Oxide	2mg

Only prescribing Tablet Oculovit Extra fulfills the requirement of the recommended daily dose twice a day. This supplement was advised for a period of four months to all types of AMD dry or exudative, CNV occult or classic (Fig 1), and to all AMD locations (Fig 2). The same preparation is being used in USA for treating this disease³. The patients were examined every six weeks for measurement of visual acuity, Amsler's Test and Fundus Examination. FFA was repeated after six months.

Fig. 1. Percentage of Types of AMD in Dietary Supplement Study Sir Ganga Ram Hospital Chapter (DSS- SGRH Ch)



Fig. 2 Location of AMD


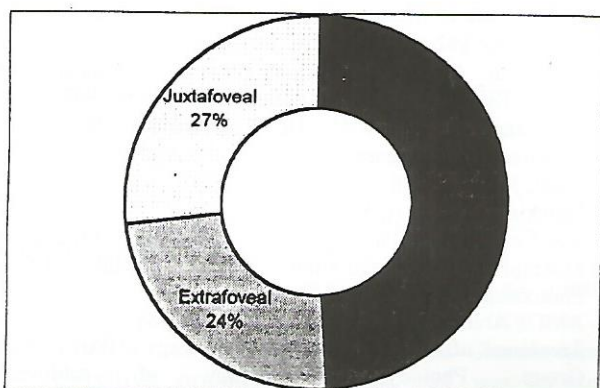


Fig. 3 Percentage of blindness with AMD in different age groups

Results

The percentage of types of AMD in Dietary Supplement Study- Sir Ganga Ram Hospital Chapter (DSS- SGRH Ch.) has been depicted in Fig 1. Percentage of blindness in

DSS- SGRH Ch. has been given and compared with the figures of American Academy of Ophthalmology in Fig 3.

Visual results, six months after the onset of Dietary supplement therapy (DST) have been shown in Table 1 and 2. Success in the treatment means either cessation in progression of disease or improvement in visual acuity. The results were better in neovascular type of AMD than non-neovascular type. Visual improvement by 2 lines of Snellen's acuity was noted in 27% of neovascular AMD patients and 1 line improvement in vision was observed in 2.4% of non neovascular AMD patients. Remaining exudative AMD patients had stable vision i.e.; progression of disease was stopped. It is hypothesized that check in disease process or visual improvement could be due to halt in degenerative chemical chains and resorption of oedema fluid⁴. It is not difficult to appreciate this hypothesis in neovascular form, but in dry AMD it is probably the pre-existent partial integrity of foveal center that disease was checked but only in 17% after resolution of oedema fluid.

Table 1. (n=157)

Group	Type of AMD	No. of eyes	Success achieved	%age
I	Exudative (wet)	114	105	93
II	Non-exudative (Dry)	43	7	17

Table 2. Break up of success

Type of AMD	Success rate	Visual improvement	Stable visual acuity
Exudative (Wet)	93%	27%	66%
Non-exudative (Dry)	17%	2.4%	14.6%

Discussion

Age related Eye diseases Study (AREDS) in USA concluded after 10 years of research that dietary supplement has no effect on any degenerative eye disease except AMD. AREDS group claims visual improvement of 19% in neovascular AMD patients³. Our results are comparable. It is a known fact now that all degenerative processes in the human body are hallmarked by free radical formation. Under the effect of nutritional deficiency, ultraviolet light, blue light and inflammatory diseases, free radicals are formed by the loss of electrons or pair of electrons from orbit of molecules. To get stabilized the molecules steal electrons from other molecules, which in turn become free radicals. Thus a chain develops which causes cellular and tissue damage (photoreceptors and retinal pigment epithelial cells). Therefore it becomes important to check the process of free radical formation. Vitamin C and E are antioxidants and donate electrons to the molecules, which had become free radicals. These molecules thus become stabilized after receiving electrons and chain of degenerative chemical processes comes to a stop⁵. Neovascular membranes leak

blood and ooze fluid, which induces inflammatory process and ultimate fibrosis of chorioretinal complex. The DST retards the degenerative mechanisms and therefore the oedema fluid and blood gradually absorbs and pressure on photoreceptors and pigment epithelial cells is released. Zinc and Copper are important elements for most of the chemical reactions⁶

It is suggested that during DST close liaison with internist should be maintained as β -Carotein increase the risk of Carcinoma of lung in smokers; high Zinc level can cause genitourinary problems and sometimes Zinc supplements may cause copper deficiency. Following suggestions may be helpful in preventing the disease and probably for the treatment as well.

1. Protect the eye from ultraviolet and blue light.
2. Take a balanced diet
3. Avoid smoking
4. Take Vitamins and Minerals after the age of 40 years
5. Annual fundus examination after the age of 60 years⁷
6. Patients with hypertension and Ischaemic heart disease and smokers should have the annual examination after the age of 50 years^{8,9}

Conclusion

DST has been found to be effective in all forms of AMD and in all AMD locations. It does not have destructive effect on retina, while damage and visual acuity drop has been documented in other treatment modalities like PDT, Argon Laser¹⁰, TTT¹¹. It is an ongoing study, which will last for another eight years to look into its long lasting effects in AMD. In the next two years step, control group will also be added to previous group. Third two years step would be to find the cause of failure of treatment. Fourth two years step is to evaluate the risk factors i.e. what diseases can directly or indirectly effect the eye to lead to

AMD and why?. Fifth would be final and collaborative step.

References

1. "Age related Macular Degeneration, in Basic & Clinical Sciences Course"; Retina and Vitreous, AAO 1994-1995; section 12: P 26
2. "Age related Macular Degeneration, in Basic & Clinical Sciences Course"; Retina and Vitreous, AAO 1994-1995; section 12: P 33
3. Wests S, Vitale S, Hallfrisch J, et al "Are Antioxidants or supplements protective for Age related Macular Degeneration?" Arch Ophthalmol, 1994; 112 :222-227
4. "Eye diseases case control study group. Antioxidant status and Neovascular AMD." Arch Ophthalmol, 1993; 111: 104-109
5. Bressler MN, Bressler SB, Fine SL, "Age related Macular Degeneration?" Surv Ophthalmol, 1988; 32 :375-413
6. Newsome DA, Swirtz M, Leone MC, Elaston RC, Miller E, "Oral Zinc in Macular Degeneration", Arch Ophthalmol, 1988; 106: 192-198
7. American Academy of Ophthalmology: Frequency of Ocular Examination, 1990; Policy Statement No 808
8. Hayman L, Schechet AP, Hc R, Leske MC: Hypertion, cardiovascular diseases and AMD. , Arch Ophthalmol, 2000; 118: 351-358
9. Hawkin BS, Bird A, Klein R, West SK., "Epidemiology of Age Related Macular Degeneration. Mol Vis 1999; 5: 26
10. Macular Photocoagulation study Group: Laser Photocoagulation of subfoveal neovascular lesions of AMD., Arch Ophthalmol, 1990; 108 :825-831
11. Treatment of AMD Photodynamic Therapy (TAP) study Group. Photodynamic therapy of subfoveal neovascularization in AMD with Vertipofin. One year results of 2 randomized clinical trials - TAP Report, Arch Ophthalmol, 2001; 119 :198-207