

## Case Report

# Analysis of Four Free Vascularized Fibular Graft (VFG)

S JAFRI H RAFIQ S AHMAD A GHAFAR F RAFIQ

Hand UpperLimb Surgery Centre, Pak Army, Lahore Cantt.

Correspondence to Dr. Salman, Hand Upper Limb Surgery Centre Pak Army

A study of four free VFG is presented. The age range was 18 to 45 years. The patients remained under treatment in civil hospitals before referring to our centre. In all cases end to side anastomosis of vessels were done. Due to high cost of angiography, only one patient underwent this test, while others were subjected to bone scan of transferred. VFG uptake was 100%.

**Key words:** Vascularized fibular graft, VGG

In free tissue transfer, the tissue is removed from one site with its blood supply and transferred to new site, where its nutrient vessels are anastomosed with recipient vessels. Huntington<sup>1,2</sup> recognized the advantage of using a bone graft with its nutrient blood supply intact in 1905<sup>3,4,5,6</sup>. Taylor reported the first clinically successful free bone graft with microvascular anastomoses in which a fibular segment was transferred from the contralateral leg to reconstruct a large tibia defect. We have done four successful free vascularized fibular grafts in near past. Due to high patency rates, end-to-side anastomosis technique was used at recipient site.

### Case 1

An eighteen year old girl presented with giant cell tumour of lower end to radius. Diagnosis was done on radiographs. Excision of tumour with margins of healthy bone was planned. Tumour was removed and free FVG was successfully implanted (Fig 1,2,3,4). Radial artery and cephalic vein of recipient area were used.

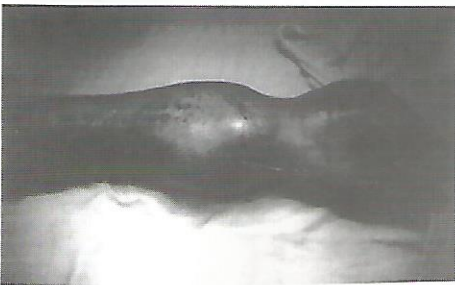


Fig.1 Giant cell tumour

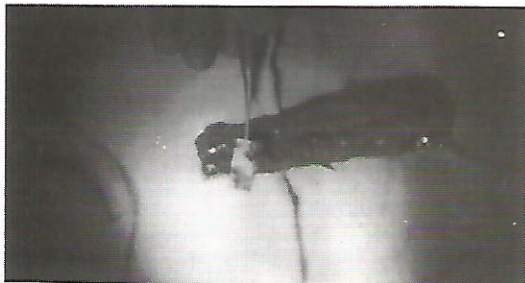

Fig. 2. Free fibular graft with nutrient vessels

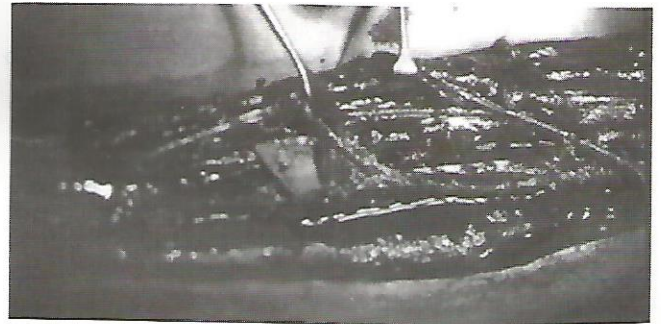


Fig. 3 anastomosis of fibular vessels with recipient vessel

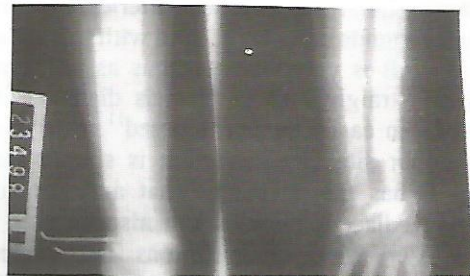


Fig. 4. VFG in place

### Case 2

A case of giant cell tumour of upper end of humerus was referred to HULS centre. He was treated with curettage and cementing of cavity in a civil hospital. Recurrence occurred. At HULS Centre excision of upper end of humerus with surrounding soft tissue was done and free fibular graft (VFG) implanted. End-to-side anastomosis done with brachial artery and its venae comitantes (Fig.5).

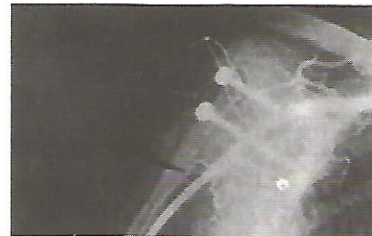

Fig. 5. VFG replacing humerus angiography

## Analysis of Four Free Vascularized Fibular Graft (VFG)

### Case 3

A young man presented with history of chronic osteomyelitis of ulna for the last 10 years. Infected portion of 15cm of ulna was excised. V.F.G. was applied for bridging the bony defect. Ulnar artery and subcutaneous vein was used as feeding vessels.

### Case 4

A 20 years old male presented with history of old traumatic segmental loss of radius (20cm). Segmental loss of radius was replaced with VFG. Radial artery and a subcutaneous vein (tributary of cephalic vein) used as feeding vessels.

### Results

All the VFG survived without any complication. No morbidity at donor site noted.

### Discussion

Free vascularized fibular bone grafts have been used for variety of conditions however history of irradiation or infection must be carefully weighted because recipient vessels may have been damaged<sup>7,8,9</sup>. There is no age limit. Children have more capacity to accept revascularized portion of bone graft. Arteriograph of donor site is mandatory because anomalies associated with anterior tibial, posterior tibial and peroneal arteries are common. Hand Doppler sounds can also be used with less reliability. Free fibular graft is very advantageous as one can have upto 25cm of straight bone<sup>10</sup>. Vessels diameter is very adequate and can easily be anastomosed<sup>11</sup>. It is relatively superficial donor site and dissection is simple but time consuming. It has the advantage that articular surface, epiphysis and adjacent muscles can also be used along with bone. Very few complications are present as compared to other vascularized bone grafts. Free fibular grafts can be fixed both externally with fixator and internally with plates. Post op management does not differ significantly from conventional bone grafting techniques.

Anticoagulation is not used in routine. Aspirin is used 75-150mg daily. During surgery solution containing normal saline heparin and lignocain is used for keep in the vessels wet. A small island of skin can be taken for visual perfusion monitor, but it is not used routinely. Free fibular bone graft is a good technique for bridging huge bone defects. Moreover donor site does not suffer from any disability. The only requirement is expertise with mcirosurgical instruments and operating microscope.

### References

1. Huntington TW. Case of bone transference. *Ann Surg* 1905; 41: 249-56.
2. Hutchinson J. The fate of experimental bone autografts and homografts. *Br J Surg* 1952; 39: 552-61.
3. Taylor GI. Microvascular free bone transfer. A clinical technique. *Orthop Clin North Am* 1977; 8: 425-47.
4. Taylor GI. The current status of free vascularized bone grafts. *Clin Plast Surg* 1983; 10: 185-209.
5. Taylor GI, Daniel RK. The free flap: Composite tissue transfer by vascular anastomosis. *Aust NAJ Surg* 1973; 43: 1-3.
6. Taylor GI, Miller GDH, HAM FJ. The free vascularized bone graft. A clinical extension of microvascular techniques. *Plast Re Constr Surg* 1975;55: 533-44.
7. Berggren A, Weiland AJ, Ostrup LT. Bone scintigraphy in evaluating the viability of composite bone grafts revascularized by microvascular anastomosis, conventional autogenous bone grafts and free nonrevascularized periosteal grafts. *J Bone Joint Surg* 1982; 64A: 799-809.
8. Berggren A, Weiland AJ, Ostrup LT. The effects of storage media and perfusion on osteoblast and osteocyte survival in free composite bone grafts. *J Microsur* 1981; 2: 273-82.
9. Berggren A, Weiland AJ, Ostrup LT, Dorfman HD. Microvascular free bone transfer with revascularization of the medullary and periosteal circulation of the periosteal circulation alone. *J Bone Joint Surg* 1982; 64A: 73-87.
10. Gilbert A. Vascularized transfer of the fibular shaft. *Int J Microsurg* 1979; 1(2): 100-102.
11. Trueta J, Caladiaz AX. A study of the blood supply of the long bones. *Surg Gynecol Obstet* 1964; 118: 485-98.