

Intercoronary Communication Between the Circumflex and Right Coronary Arteries: A Very Rare Coronary Anomaly

Noeman A.,¹ Banna H.U.,² Shakoor T.³

Address for Correspondence: Dr. Ahmad Noeman, Assistant Professor, Cardiology Department, Punjab Institute of Cardiology, Lahore.

Here we present a case of 45 years old patient with atypical chest pain and having a rare congenital anomaly i.e. inter-coronary artery communication.

Key words: angiography, coronary anomaly, coronary artery.

Introduction

Intercoronary communication is an extremely rare condition in which there is an open – ended circulation with bidirectional blood flow between two coronary arteries. This anomaly is usually seen between the right coronary artery and circumflex artery. Intercoronary communications in the absence of obstructive coronary artery disease is extremely rare with a reported incidence of less than 0.02%. Congenital coronary artery anomalies are rare. They have been reported in approximately 1% of cardiac catheterization cases in different series.^{1,2} In most cases patients are asymptomatic and they are discovered as incidental findings during cardiac

catheterization or autopsy. Large communications between coronary arteries in the absence of obstructive coronary artery disease are extremely rare. We report the case of a patient with large intercoronary communications in the absence of obstructive coronary artery disease.

Case Report

A 45 – year – old man presented with atypical chest pain. Physical examination was normal, with arterial blood pressure of 120/80 mmHg and a regular heart rate of 84/min. His Echocardiography and resting electrocardiography (ECG) were within normal limits. Exercise ECG (ETT—Exercise

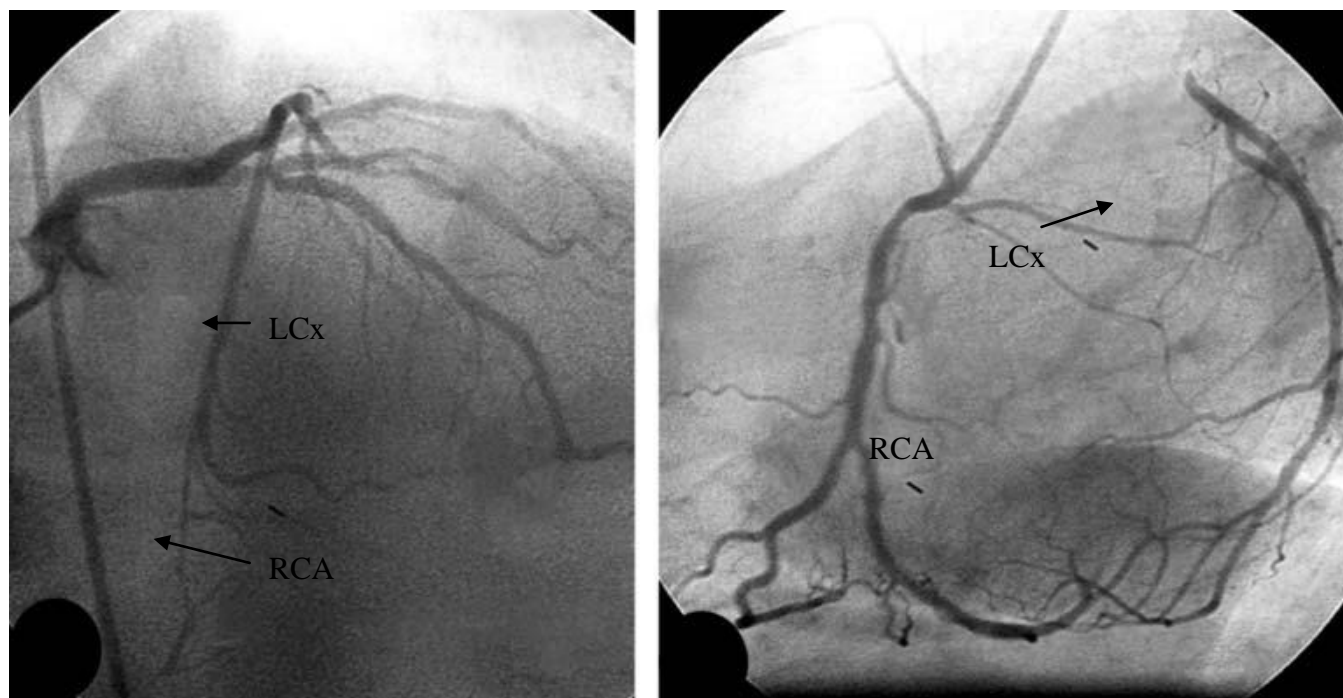


Fig. 1: A. Injection of the left coronary artery showed a connection between the circumflex artery and the distal part of the right coronary artery. In this angiographic view, it is not clear whether the connection is an intercoronary communication or retrograde filling of an occluded right coronary artery by collaterals. B. Selective injection of the right coronary artery showed retrograde filling of the circumflex artery via the communication. Note the absence of critical lesions involving right coronary (RCA) and circumflex (LCx) arteries.

tolerance test) revealed 1 mm horizontal ST depression in the inferior leads. The patient underwent coronary angiography and ventriculography using the Judkins method via the right femoral artery using 6 Fr arterial sheath and catheters (JL₄ and JR₄). Left ventriculography revealed preserved LV function with wall motion abnormalities. Left coronary injection showed retrograde filling of the Right coronary artery from the distal left circumflex artery (Figure 1). And Right coronary injection showed retrograde filling of left circumflex artery from distal right coronary artery. No stenosis or angiographic lesions were observed in the right coronary artery or the circumflex artery.

Discussion

Interarterial intercommunications can be found in some regions of the human arterial system: 1) the superficial volar arch of the hand, with communication between the ulnar and radial arteries; 2) the circle of Willis; 3) the intestinal branches of the superior mesenteric artery that form multiple arches; 4) the gastric artery that extends from the right to the left gastroepiploic artery.¹ Intercommunication is very rare in the human coronary system. The first case regarding coronary intercommunication was presented nearly 30 years ago and only a few cases have been reported since then. The first documented case was reported by Cheng in 1973.^{3,4} Since then, only a total of 11 cases of intercoronary communications in the absence of obstructive coronary artery disease have been reported in the literature.²⁻⁶ Intercoronary communications are usually found between the right coronary artery and the circumflex artery, as in our case, but they may also be found between the right coronary and left anterior descending arteries.⁷

Two types of intercoronary communication have been defined:

- (1) between anterior and posterior interventricular arteries in the distal portion of the posterior interventricular groove; and
- (2) between the distal right coronary artery and circumflex arteries in the posterior atrioventricular groove, as described in our case.

Anatomically and angiographically, collateral vessels and intercoronary communication appear to be different. Those collaterals that develop in the presence of obstructive coronary artery disease are usually less than 1 mm in diameter and appear tortuous and twisted with a corkscrew shape, whereas intercoronary anastomosis in the absence of obstructive lesions tend to be straight or gently curved.⁸ Histologically they also appear to be different: collaterals that develop in the presence of obstructive coronary artery disease are composed of endothelium supported by poorly organized collagen, muscle, and elastic fibers, whereas intercoronary communications are similar to an epicardial vessel with a well defined muscular layer⁹ so that persistence of the foetal coronary circulation has been suggested as the underlying mechanism.

To the best of our knowledge, all of the reported inter-

coronary communications between the right coronary and circumflex arteries are bidirectional, in that both coronary arteries fill via communications when contrast media is given to the other one. These communications have been found in the absence of coronary artery disease, although myocardial perfusion scans occasionally were abnormal at the connecting site.^{10,11} This anomaly may be misinterpreted as indicative of a functioning collateral vessel for unrecognized severe proximal coronary artery obstruction. A large collateral vessel, as opposed to a true intercoronary communication, is the likely case if there is a severe stenosis or total occlusion in any coronary artery.

Moreover, the real intercommunication in the coronary system is benign and may serve as a collateral source in the event that a coronary artery obstruction develops.^{12,13}

Conclusions

Intercoronary communications in the absence of obstructive coronary artery disease are exceedingly uncommon. The clinical significance of intercoronary communications is uncertain. It is probably a benign anomaly and may actually have a protective role if obstructive coronary artery lesions develop in any of the involved vessels, serving as a large collateral to minimize myocardial ischemia. These cases also illustrate the interventional cardiologist should recognize that congenital intercoronary communications although very rare can be present in patients with angiographically "normal" coronary arteries.

Acknowledgements

I am highly grateful to my parents and family for their support and prayers.

References

1. Yamanaka O, Hobbs RE. Coronary Artery Anomalies in 126, 595 patients undergoing coronary angiography. *Catheterization and Cardiovascular Diagnosis* 1990; 21: 28-40(s).
2. Wilkins CE, Betancourt B, Mathur VS, et al. Coronary Artery Anomalies: a review of more than 10,000 patients from The Clayton Cardiovascular Laboratories. *Texas Heart Institute Journal* 1988; 15: 166-173(s).
3. Greenberg MA, Fish BG, Spindola-Franco H. Congenital anomalies of the coronary arteries. *Radiol Clinics N Amer* 1989; 27: 1127-1146.
4. Cheng TO. Arteriographic demonstration of intercoronary arterial anastomosis in a living man without coronary artery disease. *Angiology* 1972; 23: 76-88.
5. Dubel HP, Glied V, Rutsch W. Communication between nonstenotic coronary arteries. *Z Kardiol* 2003; 92: 273-275.
6. Atak R, Guray U, Akin Y. Images in cardiology: Intercoronary communication between the circumflex and right coronary arteries distinct from coronary collaterals. *Heart* 2002; 88: 29.

7. Carangal VP and Dehmer GJ. Intercoronary communication between the circumflex and right coronary arteries. *Clin Cardiol* 2000; 23: 125–126.
8. Meireles GC and Abreu Filho LM. Intercoronary connection with bidirectional blood flow and concentric left ventricular hypertrophy. *Rev Paul Med* 1994; 112: 654–657.
9. Panayiotou H, Perry JM, Norris JW. Intercoronary connection and apical left ventricular hypertrophy: Case report and review of the literature. *Cathet Cardiovasc Diagn* 1991; 24: 55–57.
10. Yamanaka O and Hobbs RE. Coronary artery anomalies in 126,595 patients undergoing coronary arteriography. *Cathet Cardiovasc Diagn* 1990; 21: 28–40.
11. Esente P, Gensini GG, Biambarolmei A, Bernstein D. Bidirectional blood flow in angiographic normal coronary arteries. *Am J Cardiol* 1983; 51: 1237–1238.
12. Androulakis A, Chrysohoou C, Barbetseas J, et al. Arteriovenous connection between the aorta and the coronary sinus through a giant fistulous right coronary artery. *Hellenic J Cardiol*. 2008; 49: 48-51.
13. Gur M, Yilmaz R, Demirbag R. Unidirectional communication between the circumflex and right coronary arteries : a very rare coronary anomaly and cause of ischemia. *Int J Cardiovasc Imaging*. 2006; 22: 339-342.