

## Research Article



# Faisal's Technique to Closely Manage Volar Barton's Fracture: A Pilot Study

Faisal Masood\*<sup>1</sup>, Ranjit Kumar Sah<sup>2</sup> and Ahmad Humayun Sarfaraz<sup>3</sup>

<sup>1</sup>Associate Professor of Orthopaedic Surgery, KEMU/ Mayo Hospital, Lahore; <sup>2</sup>Post Graduate Resident, Department of Orthopaedic Surgery, KEMU/ Mayo Hospital, Lahore; <sup>3</sup>Senior Registrar, Department of Orthopaedic Surgery, KEMU/ Mayo Hospital, Lahore Pakistan.

**Abstract** | This study was conducted to establish the efficacy of closed reduction and percutaneous pinning (CRPCP) in management of volar Barton's fracture by Faisal Technique.

**Methods:** A total of 10 cases of volar Barton's fracture fulfilling our inclusion and exclusion criteria were included in our study from August 2015 to August 2016. These cases, presented at our department, were managed with closed reduction under image intensifier by dorsiflexing the wrist and reducing the fragment by ligamentotaxis and percutaneous pinning in anti-glide fashion from dorsal proximal (intact cortex) aspect of distal radius and engaging the volar fragment aiming the subchondral cortex and were supplemented with short arm cast application in volar flexion. The outcome was evaluated using Pattee and Thompson functional criteria at 6 month. Also the percentage of union and time to union were evaluated.

**Results:** The mean age of total ten patients was  $29.8 \pm 3.20$  years (25-35 years). We achieved union in 100% of the patient at mean time of  $8.20 \pm 0.92$  weeks (7-10 weeks). There were 20% (n=2) cases with excellent and 80% (n=8) cases with good outcome according to Pattee and Thompson criteria. We had two cases (20%) with pin-tract infection that were managed with dressing and oral antibiotics according to culture and sensitivity. There were no loss of reduction

**Conclusion:** Our pilot study demonstrates good result with CRPCP (Faisal's Technique) in volar Barton's fracture and warrants further randomized control trial study to establish its efficacy in such cases.

Received | September 20, 2017; Accepted | January 15, 2018; Published | March 18, 2018

\*Correspondence | Dr. Faisal Masood, Associate Professor of Orthopaedic Surgery, KEMU/ Mayo Hospital, Lahore; Email: drfaisalortho@gmail.com

Citation | Masood, F., R.K. Sah and A.H. Sarfaraz. 2018. Faisal's technique to closely manage Volar Barton's fracture: A pilot study. *Annals of King Edward Medical University*, 24(1): 679-683

DOI | <http://dx.doi.org/10.21649/journal.akemu/2018/24.1.679-683>

Keywords | Volar barton, Mehara classification, Pattee and Thompson

## Introduction

Distal radius fracture comprises of 8-15 % of all the fracture encountered in emergency and approximately 60% of them are the intra-articular fracture<sup>(1-3)</sup>. Volar Barton's fracture is the displaced intra-articular coronal plane fracture-subluxation of volar lip of the distal radius with displacement of carpus with the fragment. This fracture pattern is usually

seen in young active adults and is indicative of high energy trauma.<sup>(4)</sup>

Different forms of treatment options are suggested for this type of fracture. Different author advocates the advantage of treatment option used by them. Initially the treatment of volar Barton fracture was with closed reduction but now the treatment is shifting towards open reduction and internal fixation with early

mobilization of these periarticular fracture <sup>(5,6)</sup>.

We have conducted this pilot study to assess the efficacy of our new Faisal's technique in treating such fracture. With this technique, all the patients escapes a major surgery with no incision and scar. This method is very cost effective as it save time, money and resources.

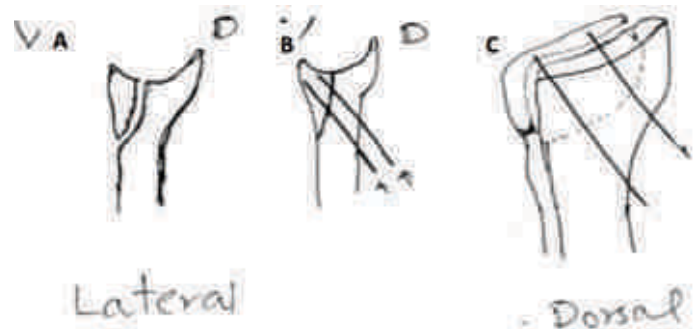
## Materials and Methods

This Quasi experimental study was conducted in Department of Orthopaedic Surgery and Traumatology, Unit-I, King Edward Medical University from August 2015 to August 2016. All patients presented to accident and emergency or outdoor of Mayo Hospital, Lahore, Pakistan, within a week of volar Barton fracture with no co-morbid condition were included in this study. A pilot study on 10 patients were conducted to show the efficacy of this new Faisal technique before subjecting all the volar Barton fracture presenting to us to this treatment. The efficacy was regarded as the capability of this new technique to provide functional outcome at least similar to the proposed open reduction and internal fixation. All the cases were operated by the primary surgeon and were followed up in outdoor at 2, 4, 8 and 12 weeks and 6 month. Range of motion of metacarpophalangeal and interphalangeal joint were encouraged the very next postoperative day as tolerated. The cast was removed at 8 weeks after sign of callus was seen and were subjected to rehabilitation with active range of motion (ROM) wrist, which was progressed to passive ROM over time. The outcome was monitored with variables: presence of union, time to union, Pattee and Thompson functional criteria and complications. The ROM of the involved wrist was measured to compare it with normal contralateral wrist and note the difference between the two. K-wire of 1.5-2.0 mm of stainless steel was used.

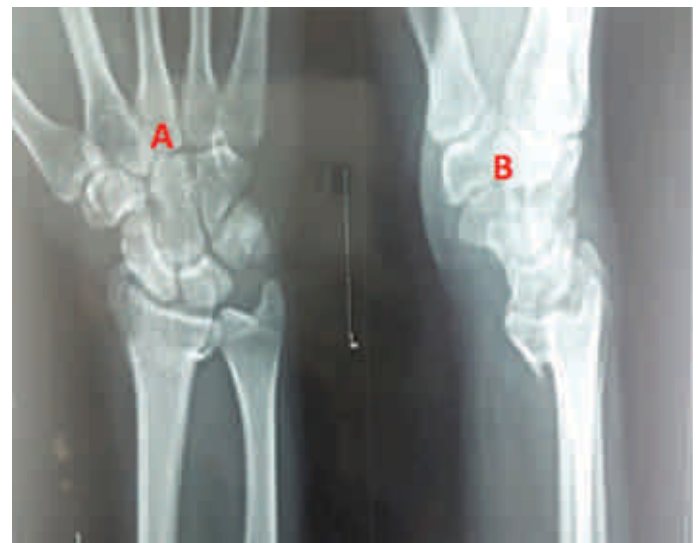The primary author based on the concept of better outcome both functionally and cosmetically in managing intra-articular fracture closely designed this new technique of treatment. The fracture were reduced closely by dorsiflexing the wrist and reducing the fragment by ligamentotaxis and percutaneous pinning in anti-glide fashion from dorsal proximal (intact cortex) aspect of distal radius and engaging the volar fragment aiming the subchondral cortex under image intensifier (Figure 1). Sometimes additional

cross K-wires were added to enhance the stability of the fixation. Short arm cast in volar flexion supplemented the fixation. An articular step-off of less than 2 mm were acceptable.

An example of a case fixed by this technique is shown in Figure 2 and 3.



**Figure 1:** Illustration of fixation of volar Barton's fracture using Faisal's technique. Volar Barton fracture in lateral view; **A.** Reduction and stabilization of volar Barton fracture with K-wire from proximal dorsal to distal volar aiming the sub-chondral region of volar lip (Faisal's Technique), **B** and **C.** V= volar and D= Dorsal



**Figure 2:** Preoperative X-ray of a case of Mehara type I Volar Barton fracture of left distal radius; **A.** AP view and **B.** lateral view

## Results

We had 80% (8) male and 20% (2) female patients in our study. The mean age of the patient was  $29.80 \pm 3.20$  years (25-35 years). Union was achieved in 100% of the cases at an average time of  $8.20 \pm 0.92$  weeks (7-10 weeks). We had 80% (8) Mehara type I and 20% (2) Mehara type II fracture (Table 3).

**Table 1:** Mehara classification of Volar Barton Fracture <sup>(6)</sup>

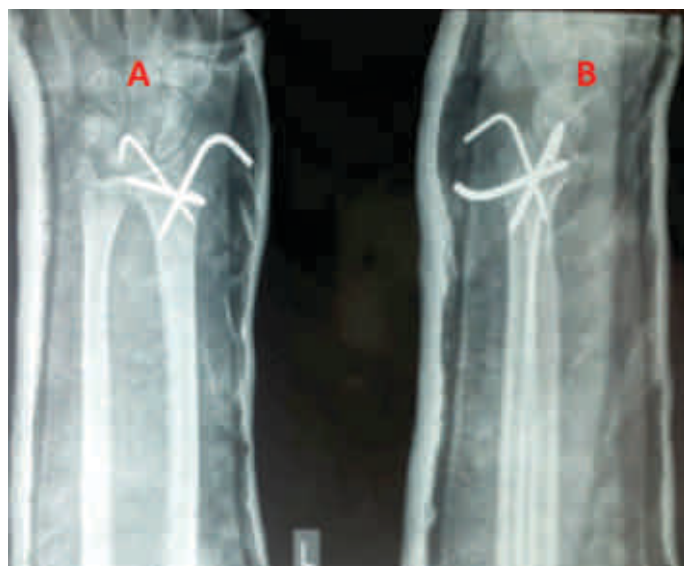Mehara Type I	A large single displaced fragment
Mehara Type II	A comminuted and displaced fracture with large or small fragment
Mehara Type III	Large displaced fragment with an additional small cortical fragment lying beneath the displaced fragment

**Table 2:** Pattee and Thompson criteria for outcome of wrist <sup>(6)</sup>

SN	Pattee and Thompson criteria	Description
1	Excellent	No pain, no disability, less than 5° loss of wrist flexion or extension, no evidence of post-traumatic arthritis and a very satisfied patient.
2	Good	Occasional mild pain, no disability, 15° or less loss of wrist flexion or extension, no evidence of post-traumatic arthritis and a satisfied patient.
3	Fair	Mild to moderate pain, modification of certain activities, 25° or less loss of wrist flexion or extension, some evidence of post-traumatic arthritis and patient not satisfied about his condition.
4	Poor	Severe pain requiring change of occupation, deformity of wrist, loss of more than 25° of wrist flexion or extension, radiological evidence of post-traumatic arthritis and an unhappy patient.

**Table 3:** Outcome of volar Barton fracture in different Mehara type

Mehara Type	Number of patients N (%)	Outcome according to Pattee and Thompson criteria			
		Excellent N (%)	Good N (%)	Fair N (%)	Poor N (%)
Type I	8 (80)	1 (12.5)	7 (87.5)	0	0
Type II	2 (20)	1 (50)	1 (50%)	0	0

**Figure 3:** Postoperative X-ray of the same case fixed with Faisal Technique and augmented by cross K-wires and short arm cast. A: AP view and B: lateral view

There was 12.5% <sup>(1)</sup> case with excellent and 87.5% <sup>(7)</sup> with good result in Mehara type I fracture while 50% <sup>(1)</sup> had excellent and 50% <sup>(1)</sup> had good result in type II fracture. Overall, we had 20% <sup>(2)</sup> cases with excellent

and 80% <sup>(8)</sup> cases with good combined outcome according to Pattee and Thompson criteria (Table 3).

We had two cases (20%) with pin-tract infection that were managed with dressing and oral antibiotics according to culture and sensitivity. There were no Loss of reduction in any case.

## Discussion

Volar Barton fracture is not a common fracture pattern in distal radius fracture. It is smith type III, AO type B3 fracture. It has an incidence of 1.3% of distal radius fracture. <sup>(5)</sup> Fall on outstretched hand with extreme of dorsiflexion, the taut ligament can cause volar lip failure in tension leading to unstable radiocarpal joint. <sup>(7,8)</sup> This makes it the fracture of necessity.

Different forms of treatment are available for such fracture. The aim of all the treatment option is to maintain the reduction until union occurs with early mobilization of the wrist. Different forms of treatment option include conservative treatment by non-operative method <sup>(9)</sup>, closed reduction and k-wire and external fixation <sup>(10)</sup> and open reduction and internal fixation. <sup>(11,12)</sup>

Our new technique provides buttress to the fracture fragment after achieving reduction and neutralizing the shear force causing the deformity. Avoidance of use of external fixator in this technique reduces the risk of development of hand stiffness. <sup>(13)</sup>



There are different advantage and disadvantage of different treatment modality in such fracture. Closed reduction with short arm cast immobilization carries a risk of loss of reduction and arthrosis but had advantage of no risk of infection and neurovascular injury. Similarly, closed reduction and pin fixation carries the risk of pin-tract infection and loosening but with added advantage of early union, more economical and better cosmetic value in comparison to open reduction and buttress plating. Open reduction and internal fixation has the risk of neurovascular injury and superficial and deep infection but allows for early rehabilitation thus decreasing the risk of arthrosis.

No study has been conducted that uses this novel idea of buttressing the fragment by percutaneous pinning through dorsal intact cortex of distal radius to Volar Fracture fragment in a dorsal proximal to volar distal aspect.

In a study by Mehara et. al.<sup>(6)</sup>, he treated Mehara type I and II fracture with closed reduction and short arm cast and type III fracture with Open reduction and internal fixation. They achieved satisfactory result (excellent and good combined) in 56.67%, fair in 30% and poor in 13.33% of case in type I fracture. They had satisfactory result in 44.44%, fair result in 44.44% and poor result in 11.11% in type II fracture. They had satisfactory result in 83.33% and fair result in 16.67% in type III fracture. We had eight type I and two type II fracture. We achieved 100% satisfactory result in both type I and II fracture. We achieved 100% union in  $8.20 \pm 0.92$  weeks.

This short-term follow-up study signifies the effect of this new technique in volar Barton fracture and thus warrants larger study with longer follow-up to establish its efficacy. We believe that this technique saves the patient from major surgery with no incision, scar and the method is very cost effective as it save time, money and resources and all the patients had a sound recovery.

## Conclusion

Our pilot study demonstrates encouraging result with CRPCP (Faisal's Technique) in volar Barton's fracture and warrants further randomized control trial study to establish its efficacy in such cases.

## References

1. Cooney 3rd W, Linscheid RL, Dobyns JH. External pin fixation for unstable Colles' fractures. *JBJS*. 1979;61(6):840-5. <https://doi.org/10.2106/00004623-197961060-00006>
2. Leung K, Shen W, Tsang H, Chiu K, Leung P, Hung L. An effective treatment of comminuted fractures of the distal radius. *The Journal of hand surgery*. 1990;15(1):11-7. [https://doi.org/10.1016/S0363-5023\(09\)91098-X](https://doi.org/10.1016/S0363-5023(09)91098-X)
3. Pogue DJ, Viegas SF, Patterson RM, Peterson PD, Jenkins DK, Sweo TD, et al. Effects of distal radius fracture malunion on wrist joint mechanics. *The Journal of hand surgery*. 1990;15(5):721-7. [https://doi.org/10.1016/0363-5023\(90\)90143-F](https://doi.org/10.1016/0363-5023(90)90143-F)
4. Meena S, Sharma P, Sambharia AK, Dawar A. Fractures of distal radius: an overview. *Journal of family medicine and primary care*. 2014;3(4):325 <https://doi.org/10.4103/2249-4863.148101>
5. Pattee GA, Thompson GH. Anterior and Posterior Marginal Fracture-Dislocations of the Distal Radius: An Analysis of the Results of Treatment. *Clinical orthopaedics and related research*. 1988;231:183-95. <https://doi.org/10.1097/00003086-198806000-00025>
6. Mehara A, Rastogi S, Bhan S, Dave P. Classification and treatment of volar Barton fractures. *Injury*. 1993;24(1):55-9. [https://doi.org/10.1016/0020-1383\(93\)90085-K](https://doi.org/10.1016/0020-1383(93)90085-K)
7. Johnson RP. The acutely injured wrist and its residuals. *Clinical Orthopaedics and Related Research*. 1980;149:33-44. <https://doi.org/10.1097/00003086-198006000-00005>
8. Fernandez DL JJ. *Epidemiology, Mechanism, Classification*. Second ed: Springer-Verlag; 1996. 399 p. [https://doi.org/10.1007/978-1-4684-0478-4\\_2](https://doi.org/10.1007/978-1-4684-0478-4_2)
9. Tang WJ, Wang MY, Gong XY, An GS. [Clinical investigation of conservative treatment for volar Barton fracture]. *Zhongguo gu shang = China journal of orthopaedics and traumatology*. 2008;21(5):383-5.
10. Dai MH, Wu CC, Liu HT, Wang IC, Yu CM, Wang KC, et al. Treatment of volar Barton's fractures: comparison between two common surgical techniques. *Chang Gung medical journal*.

- 
- 2006;29(4):388-94.
11. Nydick JA, Streufert BD, Stone JD. Intraarticular Distal Radius Fracture Open Reduction Internal Fixation. *Journal of Orthopaedic Trauma*. 2017;31:S45-S6. <https://doi.org/10.1097/BOT.0000000000000907>
12. Moirangthem V, Bharat KR, Vijayanand R, Narayana RM. Volar plating of distal radius fracture: A retrospective analysis. *Journal of Evolution of Medical and Dental Sciences*. 2015;4(52):9094-103. <https://doi.org/10.14260/jemds/2015/1318>
13. Sridhar D, Raghavendra T, Mahida JR. Comparative study between percutaneous pinning and ligamentotaxis using external fixator in the management of distal end radius fracture in adults: a prospective study. *International Journal of Research in Orthopaedics*. 2017;3(2):235-41. <https://doi.org/10.18203/issn.2455-4510.Int-JResOrthop20170780>