

# Recurrence of Pterygium in Patients Having Conjunctival Autograft and Bare Sclera Surgery

Rasool A.U.,<sup>1</sup> Ahmed C.N.,<sup>2</sup> Khan A.A.<sup>3</sup>

*Address for Correspondence: Dr. Ata-ur-Rasool, Institute of Ophthalmology Unit – III, Mayo Hospital, Lahore.*

**Introduction:** Pterygium is one of the commonest disorders in a tropical country like Pakistan. It can occur on either side of the cornea but the nasal limbus is involved much more commonly. Pterygia are reported to occur in males twice as frequently as in females. Exposure to ultraviolet light is presumed to be the most important risk factor. A wide range of surgical procedures for removal of pterygium have been used, including, bare sclera resection and pterygium excision with conjunctival autograft placement.

**Objectives:** To assess the recurrence of pterygium in patients having conjunctival autograft and patients undergoing bare sclera surgery.

**Study Design:** This was an analytical study.

**Place of Study:** This study was carried out in Unit – I, Institute of Ophthalmology, Mayo Hospital, Lahore.

**Duration of Study:** March 1, 2005 to February 28, 2006.

**Subjects:** One hundred patients were selected randomly from the out patients department of Ophthalmology, Mayo Hospital, Lahore. Fifty patients were operated with bare sclera technique and 50 patients operated with conjunctival autograft technique.

**Methods:** Before surgery, detailed history and complete ocular examination was done. Moreover, investigations blood complete examination, blood glucose level was also done.

**Surgical Techniques:** (i) bare sclera (ii) conjunctival autograft.

**Results:** It was found that there was low recurrence (10%) with conjunctival autograft and (60%) in bare sclera technique.

**Conclusion:** It was concluded that there was low recurrence insignificant complications, rapid surface healing and restoration of cosmetically acceptable appearance following conjunctival autograft.

**Keywords:** Pterygium surgery, conjunctival autograft, bare sclera excision.

## Introduction

Allah created human beings from a clot of blood. He bestowed upon human being the sense of hearing and vision. (Al Quran).<sup>1</sup> Hence loss of vision or blindness has been a problem for humanity since its creation.

Pterygium is a wing shaped fibrovascular overgrowth of bulbar conjunctiva onto the cornea.<sup>2,3</sup> It can vary from small, atrophic quiescent lesion to large aggressive rapidly growing fibrovascular lesion. It consists of a head i.e. the part which rests on the cornea, a neck and a body. It is uncommon in areas with temperate and cold climates but occurs frequently in tropical and subtropical areas.<sup>4</sup> It can occur on either side of the cornea but the nasal limbus is involved much more commonly.<sup>5,6</sup>

Pterygia are reported to occur in males twice as frequently as in females. It is uncommon for patients to present with pterygia prior to age 20 years. Patients older than 40 years have the highest prevalence of pterygia while patients aged 20 – 40 years are reported to have the highest incidence of pterygia.<sup>7</sup>

It affects the visual acuity either by directly affecting the visual axis or by producing changes in the corneal cur-

vature.<sup>8</sup> It results in unsightly, uncomfortable lump on the ocular surface and also disturbs the cosmetics of individuals. It may be resource of frequent episodes of congestion and grittiness.<sup>9</sup>

There is a considerable scientific evidence to support the theory that ultraviolet light is the principal etiological factor in pterygium formation.<sup>10,11</sup> The pathophysiology of pterygia is characterized by elastic degeneration of collagen and fibrovascular proliferation with an overlying covering of epithelium. Histopathology of abnormal collagen in the area of elastic degeneration shows basophilia with hematoxylin and eosin stain.<sup>12,13</sup>

Corneal epithelial stem cells are believed to be located in the basal cell layer of the periphery of the cornea, the transition zone between the corneal and conjunctival epithelium. Corneal epithelium is regenerated from stem cells situated at the limbus. Corneal stem cells are essential to maintain the epithelial organization by undergoing continuous turnover throughout adult life.<sup>14-16</sup>

Stem cells are susceptible to noxious stimuli such as ultraviolet radiations, dry, dusty, windy and sandy environmental conditions.<sup>17</sup> The concept that limbal stem cells

dysfunction includes conjunctivalization was first proved by Teseng et al.<sup>18</sup> In serial experimental studies and has been further confirmed by impression cytology.<sup>19</sup> In a recent report, corneal stem cell dysfunction leads to corneal epithelial cell dysfunction. Conjunctival cell invasion leads to decrease in visual acuity by extending onto the cornea across the limbus creating a thin and irregular fibrovascular growth over the cornea.

Surgical treatment remains the treatment of choice once the pterygium is found to be progressive in nature. A number of surgical techniques have been described as methods for pterygium treatment including bare sclera resection<sup>20</sup> and pterygium excision plus conjunctival autograft placement.<sup>21-24</sup> The main difference between bare sclera resection and conjunctival autograft placement is that a free conjunctival graft usually from the superior bulbar conjunctiva is sutured over the denuded sclera following the pterygium resection.<sup>25-27</sup>

## Materials and Methods

### (a) Setting

This study was conducted at Institute of Ophthalmology, Mayo Hospital, Lahore attached with King Edward Medical College, Lahore.

### (b) Samples Size

One hundred patients.

### (c) Sample Technique

Patients were selected by randomization process and divided into two groups of equal size.

### Group – I

It included fifty patients, who were operated with bare sclera technique.

### Group – II

It included fifty patients who were operated with conjunctival autograft technique.

## Patients Selection

Patients were selected with the following criteria.

### Inclusion Criteria

- ▶ Vascularized pterygium encroaching over the cornea for 2 – 3 mm.
- ▶ Both sexes.
- ▶ Age between 21 – 60 years.

### Exclusion Criteria

- ▶ Atrophic and non progressive type of pterygium.
- ▶ Pseudo pterygium.
- ▶ Conjunctival intra epithelial neoplasia.

## Study Design

This was an analytical study.

## Preoperative Evaluation

It included a detailed history and a thorough ocular examination only those patients were included in this study who met the inclusion criteria.

## History

Patients were asked about their occupation (labourers, farmers, welders etc.), duration of exposure, onset of pterygium, ocular symptoms (redness irritation etc), of the disease, use of turbans or sunglasses, history of any surgery or trauma, history of glaucoma, diabetes and hypertension.

## Examination

A detailed ocular examination of the patient was done including visual acuity and intraocular pressure (IOP) were checked. Slit lamp examination was done to check the nature and the extent of the pterygium any fluorescein staining of the cornea, tear film abnormality, cornea scarring and anterior segment inflammation. Fundus examination was done to look for any vision threatening lesion, in particular to exclude glaucomatous patients to avoid sacrificing conjunctiva in the useful area (superior limbul region) which may be required later on for filtration surgery in these patients. Anterior segment, photographs were taken preoperatively and on follow up visits postoperatively.

## Investigations

These included:

- ▶ Blood complete examination.
- ▶ Urine complete examination.
- ▶ Blood sugar.

## Preparation of Patients

Intravenous line was maintained to allow immediate access in case of any emergency. The patients were divided into two groups, fifty patients in each group.

### Group – I

Operated with bare sclera technique.

### Group – II

Operated with conjunctival autograft technique. All patients were operated upon under the microscope. Complete sterilization and aseptic measures were observed during surgery. All cases were operated under local anaesthesia using 2% Xylocain with adrenaline (1 : 100000).

## Technique

### Group – I

Bare sclera technique; lids were opened using a rigid speculum, 0.2 – 0.3 ml injection of 2% xylocain was given at the site of the pterygium to raise it upto its attachment to the cornea. Using No. 15 blade the pterygium was shaved off the cornea starting 0.5 mm in front of its head. The pterygium attached with the conjunctiva was separated from the scleral surface and excised leaving about 3 – 4 mm area of

the sclera bare. This area was further scraped removing all episcleral tissue with very light cauterization of bleeding vessels. After instillation of antibiotic ointment the eye was padded.

**Group – II**

“Conjunctival autograft technique”.

All the steps of operation are same as in bare sclera technique. After scrapping the episcleral tissue, the area of bare sclera was measured. A free conjunctival autograft was taken from the superior limbal region approximately 1 mm larger than the recipient site.

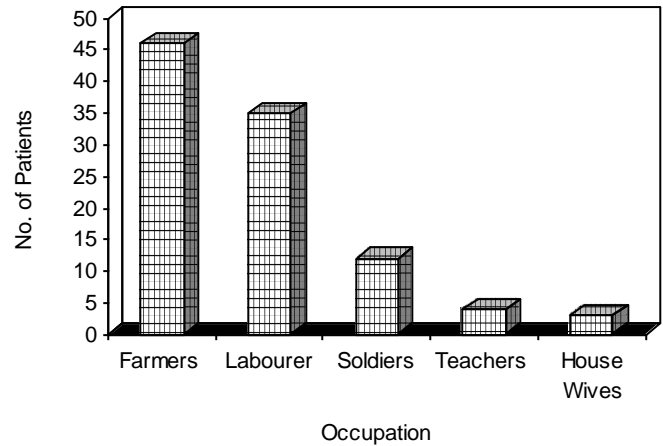
Graft was shifted to the recipient area and stitched limbus to limbus with 10/0 Nylon. All cases were given dexamethasone + chloram phenicol eye drops post operatively 5 times a day in the 1<sup>st</sup> week which was tapered off and stopped in the sixth week of follow up.

Follow up extended for nine months during which patients were checked for evidence of recurrence, integrity of graft, wound healing, cosmetic appearance and any other complication. Recurrence was defined as fibrovascular proliferation invading the cornea > 1.5 mm. Chi square test was used to analyse recurrence rates and P value < 0.05 was considered significant.

**Results**

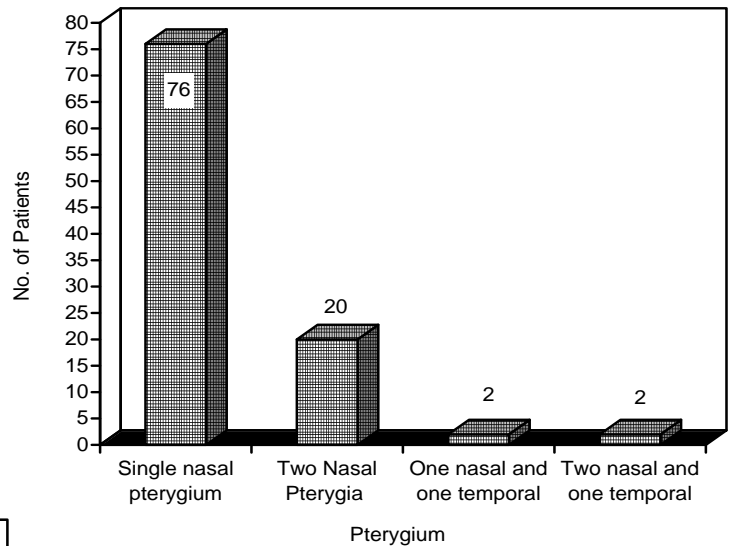
One hundred and twenty (120) patients were operated and twenty (20) patients did not come for follow-up. Therefore, one hundred (100) patients were included in this study. The patient’s age ranged from 21 – 60 years with mean value of 40 years. Pterygium surgery was performed in 50 (50%) patients with bare sclera technique and in 50 (50%) patients with conjunctival autograft technique.

Eighty two patients (82%) were male while 18 patients (18%) were females. Male to female ratio was 4.5 : 1. Majority of the patients 33(33%) were between 31 – 40 years of age (Figure 1). The vast majority of patients were outdoor workers (farmers and labourers), 81 patients (81%) with a positive history of ultraviolet rays exposure (Figure 2).

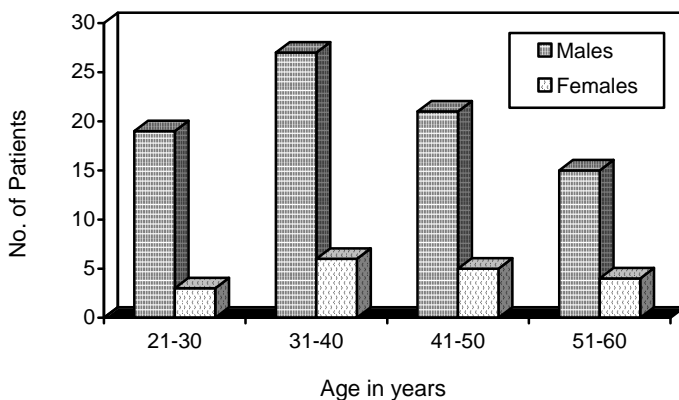


**Fig. 2: Occupation Chart.**

Seventy six (76%) patients had only single nasal pterygium while 24(24%) patients had two or more pterygia at the time of presentation. Out of 126 pterygia 122 were located on the nasal side of cornea and four were located on the temporal side. None of the temporal pterygia was without the presence of its nasal counter part (Figure 3).



**Fig. 3: Laterality of Pterygium.**



**Fig. 1: Age and Sex distribution of the patients.**

There were 30 recurrences (60%) in the bare sclera group, 3 at 3 months, 12 at 6 months, 15 at 9 months. There were 2 recurrences at 6 months, 3 at 9 months in the conjunctival autograft group and the difference in recurrence rate was statistically significant (Table 1).

No intra-operative complication was observed during the study. No undesirable effect was seen at the bared donor area (superior limbal region) which was subsequently covered by re-growth of adjacent tissue during the follow up. There were three scleral thinning in the bare sclera group, 2

conjunctival cyst, 1 in bare sclera and 1 in conjunctival autograft, 3 symblephron formation 2 in bare sclera 1 in conjunctival autograft. One granuloma formation in bare sclera group.

We had no complications like extraocular muscle disinsertion graft necrosis, graft retraction and scleral necrosis in either group.

**Table 1:** No. of recurrences of bare sclera v/s Conjunctival autograft groups.

	<b>Bare Sclera n = 50</b>	<b>Conjunctival Autograft n = 50</b>	<b>Bare Sclera + Conjunctival Autograft n = 100</b>
3 months	3	0	3
6 months	12	2	14
9 months	15	3	18
Total	30 (60%)	5 (10%)	35 (35%)

## Discussion

The pterygium is one of the commonest disorders in a tropical country such as Pakistan. Exposure to ultra violet light is presumed to be the most important risk factor. A wide range of surgical procedures for removal of pterygium have been used. However, recurrence after pterygium excision without any adjunctive therapy has been reported to be as high as 30% to 88% especially in hot dry and sunny atmosphere, but in this study the recurrence rate with bare sclera is 60% and with conjunctival autograft is 10% due to the same atmospheric condition.

In this study most of the patients were from the labour class (road workers, construction workers, farmers) who has to work outside for long period of time and were extensively exposed to hazardous effects of infrared and ultra violet radiations present in the sunlight.

Various adjunctive therapies like mitomycin C thiotepa and beta radiations had been used after pterygium excision in an effort to lower the recurrence rate but these measures have resulted in serious sight threatening complications with variable rates of recurrence. Due to high rates of complications these adjunctive therapies are less frequently used now and therefore, conjunctival, autograft has been adopted in the management of pterygium.

Alternatively the bare sclera after pterygium excision can be covered by the recently popularized method of using conjunctival autograft without or with limbal stem cell. Conjunctival autograft transplantation was described as a treatment for pterygium by Kenyon et al. in 1985. In this technique a free conjunctival graft from the superotemporal bulbar conjunctiva is used to resurface the expose scleral surface after pterygium resection. With only a few variations from Kenyon's original report on conjunctival autografting, we performed pterygium excision with limbal stem cell auto-

grafting in our patients in which graft was taken from the superior limbal region.

We had low recurrence rate of 10% with conjunctival autograft as compared to bare sclera technique 60% (Table 1). Recent studies on the limbal stem cell autografting reported its effectiveness in the prevention of pterygial recurrence 0 to 12.5%. Our study suggested a relationship between age and recurrence of pterygium. Youth is associated with increasing risk of recurrence and as the age advances, chances of recurrences become less and less. Accordingly, our patients who developed recurrence manifested these between six weeks to three months of follow up. Some patients developed recurrence despite the fact that they were regular sunglasses wearers, suggesting that use of protective measures can delay but not prevent the recurrence in susceptible population. Trachoma which is common in our population and is a leading cause of blindness is responsible for secondary depletion of stem cells as reported by some studies.

In our study the use of limbal stem cell autograft after pterygium excision was based on the hypothesis that there is focal dysfunction of stems cells in the nasal limbal area secondary to exposure to ionizing infrared and ultraviolet radiations present in the sunlight, so the resulting stem cell dysfunction play a role in the etiology of pterygium.

In this study we noticed that limbal stem cell autografting resulted in low recurrence rate, insignificant complications, rapid surface healing, minimal corneal scarring and restoration of cosmetically an acceptable appearance post-operatively.

Since limbal stem cell autografting offers a low rate of recurrence, and is free from long term complication, it appears that stem cell autografting is a safer alternative when compared to bare sclera excision or excision with various adjunctive therapies like mitomycin C, thiotepa and beta radiations etc.

Conjunctival autograft may not always be technically feasible. When very large conjunctival defects are left to cover such as in primary double headed pterygium or when the superior bulbar conjunctiva needs to be preserved for future glaucoma surgery. Other alternatives need to be sought out. In this study we discussed the use of interrupted 10/0 Nylon sutures to secure the conjunctival autograft. Typically the first 2 weeks post surgery associated with some discomfort and foreign body sensation. All sutures were removed after two weeks, after which the symptoms decreased dramatically.

The conjunctival inflammation disappeared by the fourth week. This approach is preferred because the interrupted nature of the suture allowed for any fluid build up to escape through the intervening spaces. In addition minimal reaction is associated with Nylon. The drawback of this approach is that some patients may not be as cooperative at the slit lamp at the time of suture removal. Alternatively 10/0 Nylon may be used as a running suture or 10/0 vicryl either as interrupted (short knots) or running suture eliminates the need for suture removal postoperatively. Although

more practical, it was found that more inflammation at the wound edges with the use of vicryl.

Preoperative assessment should include a motility examination to rule out entrapment of the medial rectus muscle. During surgery the medial rectus muscle should be isolated with a muscle hook and the dissection should proceed carefully and meticulously.

### Conclusion

Pterygium surgery should be taken seriously and it should be done by the experience surgeon, under good illumination, aseptic conditions and preferably under the microscope. Every patient having gone through pterygium surgery should be followed up regularly at least for period of three months so that any complications should be managed appropriately.

Most of the complications of pterygium surgery occur within first few weeks to three months. It is difficult to treat a recurrent pterygium as compared to a primary pterygium and adjunctive treatment should be added to the surgical excision of recurrent pterygium.

Although it is more time consuming procedure, it certainly is worth while to provide patients the benefits of a conjunctival autograft following excision of pterygium.

### References

1. Al – Quraan.
2. Wright KW. Conjunctival degenerations. In: Cooke DB, Klass FM. Text Book of Ophthalmology. 1<sup>st</sup> ed USA. RR Donnelley; 1997; 681-82.
3. Insler MS, Caldwell DR, Leach DH. Pterygium. In: Brightbill FS, Corneal surgery theory technique and tissue. 2<sup>nd</sup> eds. St Louis: Mosby year book 1993; 336-38.
4. Rucha G. Surgical management of pterygium- Techniques in ophthalmology. 2003; Vol. 1 (1): 22-26.
5. Threlfall TJ, English DR: Sun exposure and pterygium of the eye, a dose response curve. Am J Ophthal 1999; 128 (3): 280-87.
6. Fisher JP, Trattler W. Pterygium (Internet) 2001; available from URL: <http://www.emedicine.com/oph/topics/542.htm> cited on 10.31.2004.
7. Ooldenburg JB, Garbus J, McDonnell JM et al. Conjunctival Pterygia. Mechanism of Corneal topographic changes. Cornea 1990; 9: 200-4.
8. Mahar PS. Role of Mitomycine C in reducing the recurrence of pterygium after surgery. PJO 1996; 12: 91-94.
9. Ali Z, Qazi ZA. Evaluation of recurrence following pterygium excision with limbal stem cell autograft. PJO 1999; 15: 24-29.
10. Khan SB, Jan A, Saleem M, Islam ZU, Surgical management of pterygium PJO 2005; 21: 54-57.
11. Cheng HC, Tseng SH, Kao PL, Chen FK. Low dose intraoperative mytomycine C as chemo adjuvant for pterygium surgery cornea 2001; 20: 24-29.
12. Akhtar MS. Degenerative changes in the conjunctiva in: Basic Ophthalmology 1<sup>st</sup> ed Pakistan, Combined Printer. 2002: 127-129.
13. Apple DJ, Raab MF. Ocular pathology. 4<sup>th</sup> ed. St Louis: Mosby year Book 2000.
14. Archila EA, Aremas MC. Etiopathology of pinguecula and pterygium cornea 1995; 14: 543-44.
15. Mackenzie FD, Hirst LW, Battistutta D, Green A. Risk analysis in the development of pterygia. Ophthalmology 1992; 99: 1056-61.
16. Wong VA, Law FC. Use of mitomycine C with conjunctival autograft in pterygium surgery in Asia. Canadians Ophthalmology 1999; 106 (8): 1512-15.
17. Tseng SC, Puang Sricharen V. Cytologic evidence of corneal diseases with limbal stem cell deficiency. Ophthalmology. 1995; 102: 1476-85.
18. Tseng SC. Staging of conjunctival squamous metaplasia by impression cytology. Ophthalmology 1985; 92: 728-33.
19. Sanchez, Thorin JC, Rocha G, Yelin JB. Metaanalysis on the recurrence rate after bare sclera resection with and without mytomycin C use and conjunctival autograft placement surgery for primary pterygium. Br J Ophthalmol 1998; 82: 661-65.
20. Srivastava U, Saini VK et al., Limbal stem cell graft. A pilot study (Internet) 2005; URL: <http://www.aios.in>.
21. Kenyon K, Wagoner MD, Hettnger ME. Conjunctival autograft transplantation and recurrent pterygium. Ophthalmology 1985; 92: 1461-70.
22. Roque M. Combined Lamellar Keratoplasty and conjunctival autograft in the surgical treatment of recurrent pterygium. Web J Ophthalmol 2001; Vol. 1: 40-5.
23. Barraque JI. Etiology, pathogenesis, and treatment of the pterygium. Symposium on medical and surgical diseases of the cornea; transactions of the new Orleans academy of ophthalmology St. Louis: CV Mosby, 2001: 167-178.
24. Niazi FAK, Niazi MAK. Safety and efficacy of sliding conjunctival autograft including limbal stem cells compared to simple sliding conjunctival autograft in treating recurrent pterygium. J Rawal Med Coll. 2003; 7: 59-62.
25. Gris O, Guell JL, del Camp Z limbal – conjunctival autograft transplantation for the treatment of recurrent pterygium. Ophthalmology 2000; 107: 270-3.
26. Al Fayez MF. Limbal versus conjunctival autograft transplantation for advanced and recurrent pterygium. Ophthalmology 2002; 109: 1752-5.