

Case Report

Bilateral Branchial Fistulae and Cervical Rib

I U R KHAN M A SHAFIQ B A KHAN

Department of Surgery, K. E. Medical College/Mayo Hospital, Lahore
Correspondence to Dr. Intesar Ur Rashid Khan, Senior Registrar

Introduction:

Basic understanding of cervical embryology is essential to the discussion of branchial anomalies. The branchial apparatus develops during the second to sixth weeks of fetal life. At this stage, the neck is shaped like a hollow tube with circumferential ridges, which are termed branchial arches. (Fig 1) Branchial arches develop into the musculoskeletal and vascular components of the head and neck. Many developmental anomalies of the branchial apparatus have been identified: cysts, fistulas, sinuses, ectopic glands, and malformations of head and neck structures. The first branchial cleft develops into the external auditory canal. The second, third, and fourth branchial clefts merge to form the sinus of His, which is normally involuted. A branchial cleft cyst forms when a branchial cleft is not properly involuted. Occasionally, both the branchial pouch and branchial cleft fail to become involuted, and a complete fistula forms between the pharynx and skin.

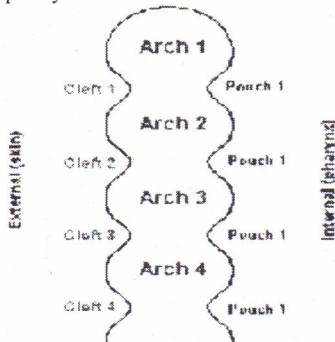


Fig 1 Branchial clefts and pouches

CASE REPORT

An 18-year-old female presented with bilateral openings on each side of midline at lower 1/3rd of neck since birth and a swelling in left anterior triangle of neck for last seven years. There is history of clear discharge from both the openings. Never had any purulent discharge or signs of inflammation around them. Seven years back patient noted a hard swelling on the left side of neck associated with pain in left arm on heavy manual work' relieved by taking rest. No colour change, loss of muscle mass or feeling of numbness in left hand or arm. On examination there was 3x4-cm swelling, hard in consistency, overlying skin was normal and showed pulsations on its lateral margin (Fig 2). Her left radial pulse used to diminish when hand was lifted above the head. (Adson sign) Her X-ray chest (Fig

3) revealed cervical rib on left side. Her Doppler study revealed normal veins in left upper limb. Left subclavian artery was bit ectetic while passing anterior to left cervical rib with post curve minimal dilatation (5.5mm pre-curve diameter and 9 mm post-curve diameter) with again normal diameter later on. Left Axillary, brachial, radial and ulnar arteries were normal

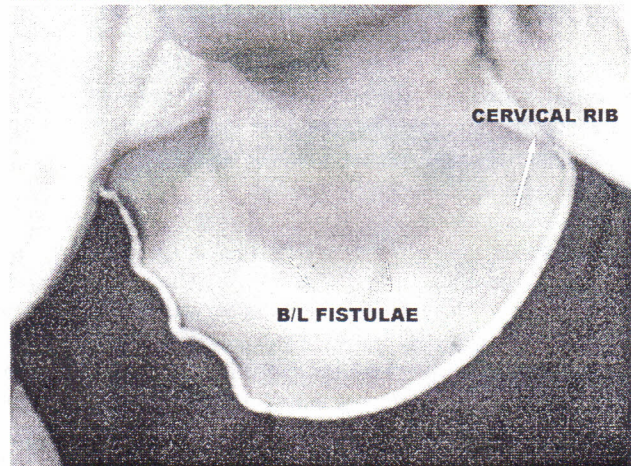


Fig 2 The Patient's Neck

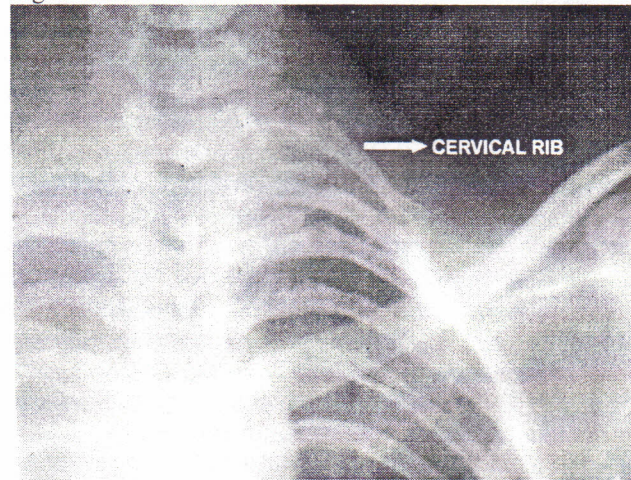


Fig 3 X-Ray showing cervical rib

After making diagnosis, operative treatment (excision of B/L branchial fistulae and Left cervical rib) was offered to the patient. Pre-operative assessment revealed patient to be in ASA Grade I. After giving general anesthesia with endotracheal intubation, Atti's incision (Collar incision extending from anterior border of one Trapezius muscle to another) with ellipse around the openings was made. Fistulous tracts were traced up to the lateral wall of pharynx, between post belly of digastric muscle and

hypoglossal nerve, where they were tied and cut; transverse incisions on upper neck at level of cricoid cartilage helped in tracing the tracts onto the lateral wall of pharynx (Fig 4 & 5). Excision of the cervical rib was done through the same incision. Cords of brachial plexus and subclavian artery were found lying anterior to the cervical rib. Slings passed under the cords and artery to save them and cervical rib was excised (Fig 6). Sibson's Fascia was exposed and left pleura were found intact. After securing haemostasis, platysma and skin were closed over suction drains. Patient showed smooth recovery post operatively and was sent home after successful removal of suction drains and skin sutures.

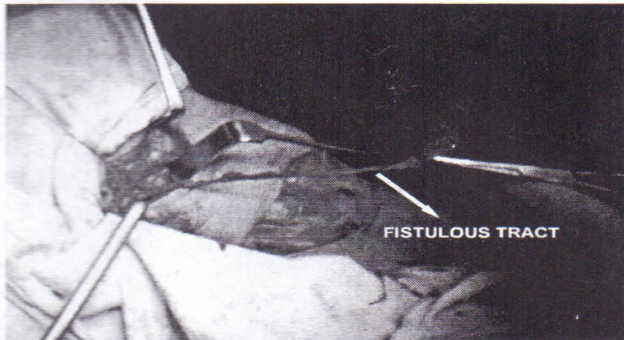


Fig 4 The Fistula tract

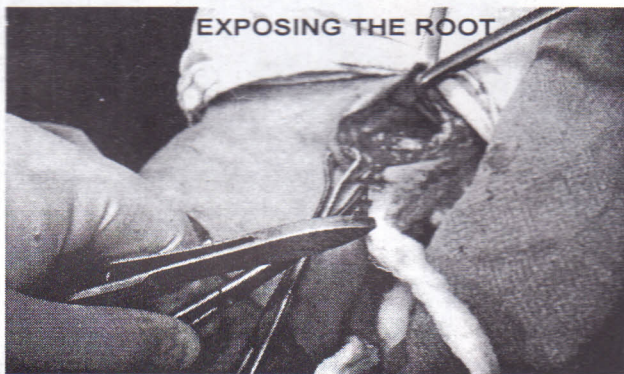

Fig. 5. Exposing the root

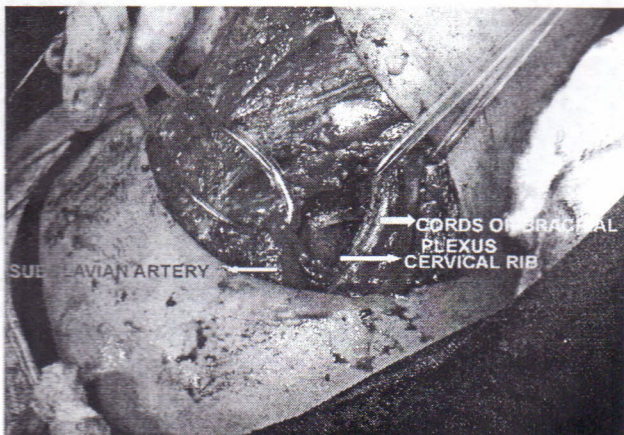


Fig 6 Subclavian Art & Cords lying over cervical rib

Discussion:

The second branchial cleft accounts for 95% of branchial anomalies. Most frequently, these fistulae are identified along the anterior border of the lower third of the sternocleidomastoid muscle. Fistulous tract courses superiorly along the carotid sheath and then medially over the hypoglossal nerve between the internal and external carotid arteries to end at the pharynx adjacent to the tonsillar fossa. Majority of them are lined by squamous epithelium, although ciliated columnar epithelium has been reported as well. Complete surgical resection is the treatment of choice and results in a good prognosis. A stair step incision is sometimes needed to follow the circuitous course. Alternative treatments, such as percutaneous sclerotherapy, remain unproven.

Cervical ribs and rudimentary first ribs occur in less than 0.5% of the population. This aberrant anatomy leads to repeated intermittent arterial compression coinciding with arm movement. This repetitive localized trauma leads to intimal lesions, focal arterial stenosis, poststenotic dilatation, aneurysmal change, and subsequent thromboembolic complications. The second portion of the subclavian artery, which has a retroscalene position, often is the site of positional compression and stricture. Treatment options include anterior and middle scalenectomy, first rib resection, or scalenectomy plus first rib resection. Reports of scalenectomy versus first rib resection have noted similar results for both procedures irrespective of the procedure performed. Pearce et al noted no difference in results from when the procedure was rib resection only, anterior and middle scalenectomy, or combined first rib resection plus scalenectomy.

Vascular and neurological symptoms were not marked in our patient. The purpose of reporting this case is that two rare embryological abnormalities presented simultaneously and successfully dealt with by a single operation.

Acknowledgement

We thank Dr. Khawaja Mohammad Azeem, Associate Professor Of Surgery, for his kind permission to publish this article

References:

1. Benson MT, Dalen K, Mancuso AA: Congenital anomalies of the branchial apparatus: embryology and pathologic anatomy. *Radiographics* 1992 Sep; 12(5): 943-60 [Medline].
2. Brown RL, Azizkhan RG: Pediatric head and neck lesions. *Pediatr Clin North Am* 1998 Aug; 45(4): 889-905 [Medline]
3. 3e-Medicine-Thoracic outlet obstruction: Article by Nicholas D Garcia, MD
4. Principles of Surgery, Seventh Edition: Seymour I Schwartz, M.D., 602.
5. 5.eMedicine - Branchial Cleft Cysts Article by Barton F Branstetter IV, MD