

## Research Article

# Multiphasic Gadolinium Enhanced Magnetic Resonance Imaging in Hepatic Venous Occlusive Disorders of Paediatric Patients: A Way Forward

Ahmed Imran<sup>1</sup>, Abid Ali Qureshi<sup>2</sup>

<sup>1</sup>Senior Registrar of Pediatric Radiology, The Children's Hospital & Institute of Child Health, Lahore; <sup>2</sup>Associate Professor of Pediatric Radiology, The Children's Hospital & Institute of Child Health, Lahore

### Abstract

**Background:** Budd Chiari syndrome and hepatic venous occlusive disorders have major implications in paediatric patients as they can lead to cirrhosis. There is a need to establish the role of imaging in early lesion detection and characterization, particularly exploring the role of multiphasic magnetic resonance imaging (MRI).

**Objective:** To determine the role of ultrasound and multiphasic MRI in paediatric patients with Budd Chiari syndrome or clinically suspected hepatic venous occlusive disorder.

**Patients And Methods:** A descriptive cross sectional study was conducted in the department of Diagnostic Radiology, CH and ICH Lahore. A total of 41 patients with known history of Budd Chiari syndrome or clinically suspected cases of hepatic venous outflow occlusion are included in the study. Each patient underwent ultrasound and Contrast enhanced Multiphasic MRI.

**Results:** Data analysis showed that ultrasound detected cirrhotic liver texture in 61% patients, caudate lobe hypertrophy in 24%, splenomegaly in 58%, ascites in 44 %, narrowing of IVC in 29%, hepatic vein thrombosis in 44% and hepatic focal lesions in only 0.2% patients. MRI detected cirrhotic liver texture in 53% patients, caudate lobe hypertrophy in 26%, splenomegaly in 58%, ascites in 44 %, narrowing of IVC in 44%, hepatic vein thrombosis in 73% and hepatic focal lesions in 7% patients. Multiphasic MRI has a higher sensitivity in detecting the changes particularly hepatic vein thrombosis and hepatic focal lesions.

**Conclusion:** Multiphasic MRI has better diagnostic yield in cases of Hepatic venous occlusive diseases particularly in detecting venous thrombosis and hepatic focal lesions in the background of cirrhotic liver.

**Received** | 30-05-2018: **Accepted** | 25-02-2019

**Corresponding Author** | Dr. Ahmed Imran, Senior Registrar of Pediatric Radiology, The Children's Hospital & Institute of Child Health, Lahore. **Email:** ahmedimran9@gmail.com

**Keywords** | Multiphasic Magnetic resonance imaging (MRI), Budd Chiari syndrome, hepatic venous occlusive disorders

### Introduction

Budd-Chiari syndrome is a disorder characterized by hepatic venous outflow obstruction at the level of the hepatic veins, the inferior vena cava (IVC), or the right atrium.<sup>1,2,3</sup> It is classified into primary and secondary varieties. It can occur at any age. The clinical manifestations range from mild symptoms to fulminant acute liver failure to chronic disease.<sup>4</sup> Early

detection of Budd Chiari is very important in timely management and to avoid complications as decompensation can occur faster in this set of patients.

Imaging plays a key role in diagnosis and follows up of Budd Chiari syndrome. Imaging features depends upon the stage of the disease. Two forms are recognized, acute fulminant form and chronic.<sup>5,6,7,8</sup> The commonly used diagnostic tools are ultrasound,

Computed Tomography (CT) scan, Magnetic Resonance Imaging (MRI) and venography. Parameters like hepatic veins/IVC thrombosis, in homogenous liver texture, caudate hypertrophy, splenomegaly, ascites and focal liver lesions/nodules can be assessed.

Grey scale ultrasound coupled with Doppler imaging is the initial investigation in suspected Budd Chiari syndrome. In acute forms liver is enlarged and there is ascites. The liver may show altered texture secondary to infarction. Qualitative information can be obtained about direction and flow pattern in hepatic veins. According to a study by Liao et al its diagnostic efficacy is 97.1%.<sup>9</sup> The findings specific to Doppler ultrasound are absence of hepatic venous flow or retrograde flow pattern.<sup>10</sup>

CT scan in case of Budd Chiari demonstrates flip flop enhancement pattern with increased enhancement in the central portion of the liver and decreased enhancement in the peripheral region due to portal backflow. Chronic cases show caudate hypertrophy, multiple intrahepatic and extra hepatic collateral veins and regenerative nodules.<sup>11</sup>

Dynamic contrast enhanced multiphasic MRI is accurate in delineating the path of the Inferior Vena Cava and hepatic veins and is very useful for assessing the extent of membranous obstructions, thrombotic obstructions, and obstructions of collaterals. MRI is helpful in differentiating Inferior Vena Cava compression due to caudate hypertrophy and IVC occlusion in cases where Ultrasound is equivocal.

The aim of this study was to explore and compare the imaging findings of gadolinium enhanced multiphasic MRI with ultrasound findings in paediatric hepatic veno occlusive disorders and Budd Chiari syndrome.

## Patients and Methods

After approval from the institutional Ethical review board a descriptive cross sectional study using prospective data from 6-5-2016 to 6-01-2017 was conducted at the Department of diagnostic radiology, Children's Hospital and the Institute of Child Health Lahore. The study period was 7months. From a total of 41 patients with ages between 1 year to 15 years with proven Budd Chiari syndrome or clinically

suspected hepatic veno occlusive disease were included in the study. The patients with multisystem disorders were excluded from the study. Demographic details, clinical data and imaging findings were documented. Doppler analysis of hepatic veins and inferior vena cava (patency and waveform) and grey scale ultrasound to assess liver parenchyma was performed using Toshiba Aplio 500.

All the patients underwent Multiphasic MRI on 1.5 Tesla (Ingenia Philips) MR system. Multi-echoic and multi-phasic post contrast sequences eThrive and mDixon techniques were used. Initial planning include T<sub>1</sub> plain (axial), T<sub>2</sub> Axial and coronal images. T<sub>1</sub> post contrast images were acquired in Arterial (15 sec), venous(90 sec), portal (180 sec) and delayed phases (300 sec).

All qualitative data were expressed as proportions. The chi-square test was for studying the categorical variables (SPSS Inc., Chicago, IL, USA). Differences were considered statistically significant when P was less than 0.05.

## Results

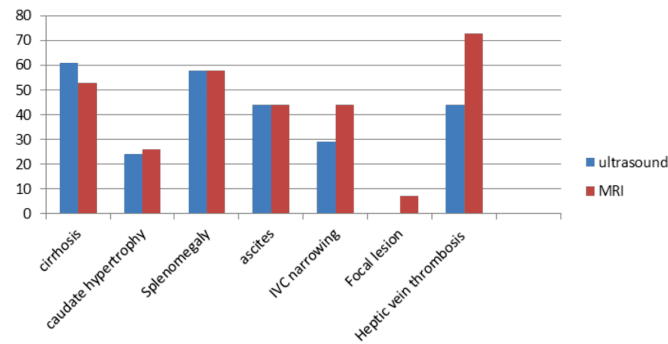
All the patients underwent both ultrasound and MRI examinations. In our study out of 41 patients 31(76%) were males and 10(24%) were female. The youngest subject was 1 year old and the oldest was 15 years of age. Ultrasound and MRI findings were documented in the form of Cirrhotic hepatic parenchymal texture, caudate lobe hypertrophy, splenomegaly, ascites, narrowing of IVC calibre, hepatic vein thrombosis and hepatic focal lesions in the background of cirrhotic liver.

The results of ultrasound and contrast enhanced dynamic MRI were comparable regarding the hepatic parenchymal findings, splenomegaly and ascites. But Multiphasic MRI had a significantly higher diagnostic yield in detecting IVC narrowing, Hepatic vein narrowing/thrombosis and focal hepatic lesions. Ultrasound detected IVC narrowing in 29% of cases as compared to 44% detected by MRI. Multiphasic MRI demonstrated hepatic vein thrombosis in 73% of cases whereas ultrasound was able to pick this finding in 44% cases. MRI had a higher percentage of detecting focal hepatic lesions i.e. 7% in comparison to 0.2% by ultrasound in the back ground of cirrhotic liver. (Graph 1)

We computed the chi-square value by using the following formula.

$$X_2 = \sum ((O_i - E_i)^2 / E_i)$$

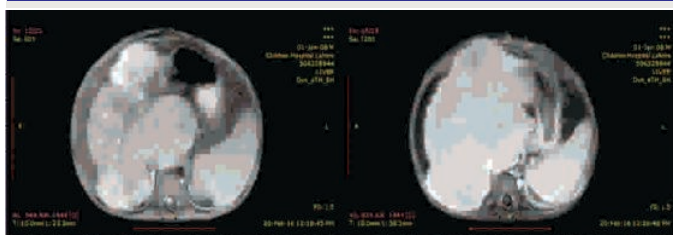
The result of summation is 13.86 with 6 degrees of freedom. Using Chi-square table the P-value for score of 13.86 with 6 degrees of freedom is 0.0314 The result is significant as p value is less than 0.05. (Table1)



**Graph 1:** Percentage of Various findings detected by Ultrasound & Multiphasic MRI

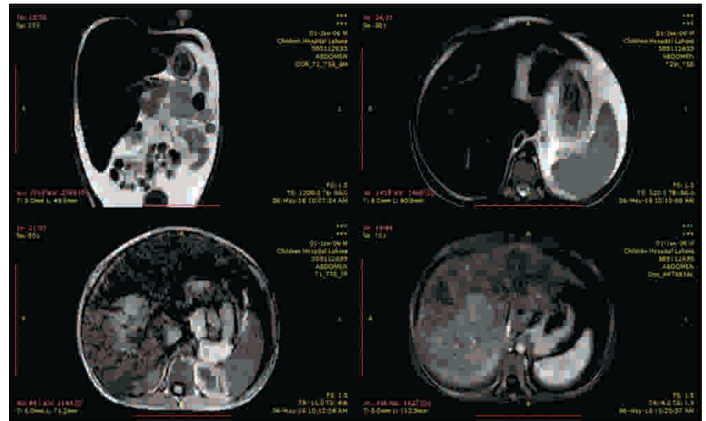
**Table 1:** Computation of Chi-square value for Ultrasound and MRI

	Ultrasound	MRI	Summation
Cirrhosis	61	53	114
Caudate Hypertrophy	23	26	49
Splenomegaly	58	58	116
Ascites	43	43	86
IVC Narrowing	29	43	72
Hepatic Focal lesion	0.2	7	7
Hepatic Vein Thrombosis	43	73	116
	257	303	560

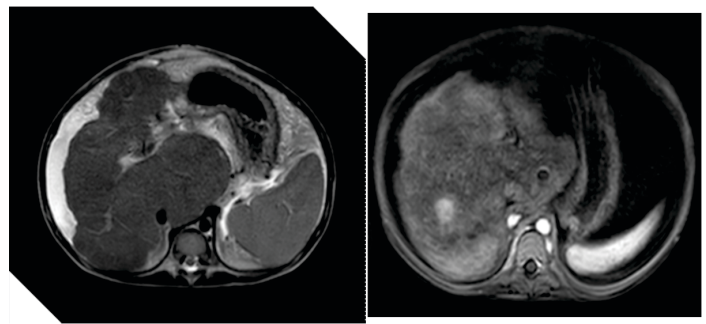


**(Figure 01):** Contrast enhanced T<sub>1</sub>, Axial sections : Back ground parenchymal changes of CLD : Non-visualization of hepatic veins , intact calibre of IVC , caudate lobe hypertrophy , ascites and splenomegaly

*Budd Chiari syndrome*



**(Figure 2)** T<sub>2</sub> coronal and axial slices with T<sub>1</sub> post contrast dynamic MRI : heterogeneous enhancement of hepatic parenchyma , slit like IVC , and ascites suggest Venous-occlusive Disease



**(Figure : 03)** T<sub>1</sub> Un-enhanced and Arterial Phase images : Focal arterial Enhancing lesion in right lobe with Chronic Budd Chiari.

**Discussion**

Budd-Chiari syndrome is a rare clinical entity characterized by hepatic venous outflow obstruction.<sup>1</sup> There is an accepted incidence of one case per one hundred thousand people in the general population of the world.<sup>3</sup> The clinical manifestations of Budd Chiari Syndrome are a result of partial or complete obstruction of venous outflow from small hepatic veins to the hepatic portion of the Inferior Vena Cava .

The diagnosis of Budd chiari syndrome is based on imaging and awareness of the imaging findings detrimental in early diagnosis and appropriate treatment strategy.<sup>12</sup> Different imaging modalities are available, these includes ultrasound coupled with Doppler imaging, CT, MRI and conventional venography. In our study we compared the sonography with Contrast Enhanced Multiphasic MRI.

Sonography remains the initial investigation due to

its easy availability and inexpensiveness. It has a reported diagnostic sensitivity of 75.0% to 90%.<sup>13</sup> A study conducted by Ferral H et al reported that ultrasound can depict absence of flow in hepatic veins and Inferior Vena Cava and imaging depends upon the level of obstruction, acuteness of the condition, and secondary decompensation.<sup>14</sup> Caudate lobe hyper-trophy is a salient feature. In our study Ultrasound was sensitive in detecting hepatic cirrhosis, splenomegaly and ascites. Regarding hepatic vein thrombosis, IVC narrowing and detection of focal lesions Ultrasound had a lower sensitivity as compared to multiphasic MRI.

Hepatic vein obstruction is manifested by ostial narrowing, echogenic thrombus, and altered flow patterns in the form of turbulent flow, non-visualization of the veins, or reversal of flow. Obstruction in the inferior vena cava presents as an echogenic web, membrane, or thrombus with turbulent flow to absent flow with in depending upon the degree of luminal compromise. Collateral formation is an important distinctive feature of sub-acute and chronic BCS. Collaterals that develop may be of intrahepatic or extra-hepatic type. Secondary signs of liver failure are present in late stages. The limitations of sonography were inability to image webs consistently, underestimation of thrombus, overlying bowel gas artefacts and operator dependency in determination of Doppler blood flow analysis.

Computed Tomography (CT) although not included in the present study can help in diagnosis of Budd Chiari and hepatic veno occlusive disorders. It has an overall reported accuracy of 50% in identifying hepatic vein thrombosis.<sup>15</sup>

The main aim of our study was to assess the role of Gadolinium enhanced dynamic multiphasic MRI in paediatric Budd chiari and hepatic veno occlusive disorders. MRI provides better soft-tissue contrast than does computed tomography and is emerging as an important modality in evaluation of pediatric liver lesions.<sup>16</sup> It is increasingly being used for comprehensive evaluation of liver diseases in children because of the lack of radiation, better lesion detection and characterization.<sup>17,18,19</sup>

In the present study Multiphasic Gadolinium enhanced MRI demonstrated higher diagnostic yield in

detecting hepatic vein thrombosis.<sup>20</sup> The safety of Gadolinium based contrast agents is well established in paediatric population.<sup>21</sup> Its ability to detect hepatic focal lesions especially in the background of cirrhotic parenchyma was excellent. MRI can differentiate between regenerating nodules and hepatocellular carcinoma. Regenerative nodules are bright on T<sub>1</sub>-weighted MR images and strongly hyper vascular after Intravenous bolus administration of gadolinium contrast material. The nodules are predominantly iso-intense or hypo-intense relative to the liver on T<sub>2</sub>-weighted images distinguishing them from Hepatocellular carcinoma which is hypo-intense in relation to the liver on T<sub>1</sub>-weighted images and hyper-intense on T<sub>2</sub>-weighted images.

The study had few limitations. MRI is an expensive and time consuming investigation and the need for sedation in children adds additional cost and risk. Its interpretation requires expertise. We have not correlated MRI findings with hepatic venography/ inferior veno cavography which are considered gold standard for evaluation of hepatic veins and MRI.

Hepatic Venography and Inferior Venocavography using Digital Subtraction Angiography (DSA) is considered the gold standard for evaluation of the hepatic veins and IVC and as it allows assessment of the level of obstruction, the presence of an occlusive membrane and differentiation between a thrombus and a tumor.<sup>22</sup> Intrahepatic and extrahepatic collateral veins can be visualised by DSA. A study by Lu X et al compared the results of compared DSA with MRV showed that MRV picked the morphology of an obstruction of the IVC, especially at the distal end of the obstruction with 100% sensitivity, 57.1% specificity, 92.5% positive predictive value and 100% negative predictive value.<sup>23</sup>

Our present study proved excellent diagnostic yield of Multiphasic MRI in detecting hepatic venous or Inferior Vena cava occlusion in comparison to Doppler Ultrasound.

In our next study we aim to correlate the MRI findings with that of venography as early and accurate detection of hepatic vein thrombosis is essential in planning treatment. Treatment is aimed at prevention of thrombus propagation, restoration of flow in thrombosed veins, hepatic decongestion and preven-

tion of complications.

To the best of our knowledge, Contrast enhanced Multiphasic MRI findings in paediatric Budd Chiari syndrome are being reported for the first time in Pakistan. Our current study serves as a baseline for future research.

## Conclusion

From the results of present study it is concluded that Multiphasic Gadolinium enhanced dynamic MRI is a useful imaging tool in evaluation of patients with Budd Chiari syndrome and hepatic veno occlusive disease. It is an excellent non-invasive problem solving modality in cases where Ultrasound findings were equivocal.

**Ethical Approval: Given**

**Conflict of Interest: None**

**Funding Source: None**

## References

- Kathuria R, Srivastava R, Yachha S. Budd Chiari syndrome in children: Clinical features, percutaneous radiological intervention and outcome. *Eur J Gastroenterol Hepatol.* 2014; 26(9):1030-8
- Hefaidh R, Cheikh M, Marsaoui L, Ennaifer R. The Budd Chiari Syndrome. *Tunis Med.* 2013; 91(6):376-81
- Valla DC. Budd Chiari syndrome/hepatic venous outflow tract obstruction. *Hepatol Int.* 2018; 12:168-180.
- Parekh J, Matel VM, Canas-Coto A, Friednab D, Lee WM; Acute liver failure study group. *Liver Transpl.* 2017; 23(2):135-142.
- Fan X, Liu K, Che Y, Wang S, Wu X, Cao J et al. Good clinical Outcomes in Budd Chiari Syndrome with Hepatic Vein Occlusion. *Dig Dis Sci.* 2016; 61(10): 3054-3060
- Cheng DL, Zhu N, Xu H, Li CL. Outcomes of endovascular interventional therapy for primary Budd-Chiari syndrome caused by hepatic venous obstruction. *Exp Ther Med.* 2018; 16(5):4141-4149.
- Jin X, Zhang K, Jin GQ. Diagnostic value of dynamic contrast enhanced CT in treatment of hepatic veno occlusive disease. *Clin Med Eng.* 2013; 20:519-520
- Nobre S, Khanna R, Bab N. Primary Budd Chiari Syndrome in children: Kings college Hospital experience. *J Pediatr Gastroenterol Nutr.* 2017; 65:93-6
- Liao JT, Xiao Y, Huang TH, Pan RZ, Wang SC, Huang YJ. Color Doppler flow image of Budd-Chiari syndrome. *Zhong Nan Da Xue Xue Bao Yi Xue Ban.* 2007; 32(1):170-3.
- Ageno W, Dentali F, Promero. Incidence rates and case fatality rates of portal vein thrombosis and Budd Chiari Syndrome. *Thromb Haemost.* 2017; 117(4): 794-800.
- Patil P, Deshmukh H, Popat B, Rathod K. Spectrum of imaging in Budd Chiari syndrome. *J Med Imaging Radiat Oncol.* 2012; 56(1):75-83.
- Faraoun SA, Boudjella Mel A, Debzi N, Benidir N, Afredj N, Guerrache Y et al. Budd-Chiari syndrome: an update on imaging features. *Clin Imaging.* 2016; 40(4):637-46.
- Trivedi CR, Thakkar H, Sannanjanja B, Shah HU. Ultrasound and Doppler features of Budd Chiari syndrome in pediatric population. *Ultrasound Q.* 2015; 31 (1): 45-54
- Ferral H, Behrens G, Lopera J. Budd-Chiari Syndrome. *Am J Roentgenol.* 2012; 199(4):737-45.
- Yang S, Sun G, Zang R. Diagnostic value of multislice spiral CT and magnetic resonance imaging in treatment of hepatic veno occlusive disease (HVOD). *Biomedical Research* 2017; 28 (16): 7216-7219
- Alqatie A, Mann E, Moineddin R, Kamath BM, Chavhan GB. Solitary liver lesions in children: inter-observer agreement and accuracy of MRI diagnosis. *Clin Imaging.* 2015; 39(3):442-448.
- Govind B. Chavhan, Susan Shelmerdine, Kartik Jhaveri, Paul S. Babyn. *Liver MR Imaging in Children: Current Concepts and Technique.* *RadioGraphics.* 2016; 36:1517-1532
- Almotairi M, Oudjhane K, Chavhan GB. Pediatric multifocal liver lesions evaluated by MRI. *Indian J Radiol Imaging.* 2015; 25(3):296-302.
- Chavhan GB, Mann E, Kamath BM, Babyn PS. Gado-benate-dimeglumine-enhanced magnetic resonance imaging for hepatic lesions in children. *Pediatr Radiol.* 2014; 44(10):1266-1274.
- Khaled M. Elsayes, Akram M. Shaaban, Sarah M. Rothan, Sanaz Javadi, Beatrice L. Madrazo, Rosa P. Castillo et al. *A Comprehensive Approach to Hepatic Vascular Disease.* *RadioGraphics.* 2017; 37:813-836
- Schneider G, Schürholz H, Kirchin MA, Bücker A, Fries P. Safety and adverse effects during 24 hours after contrast-enhanced MRI with gadobenate dimeglumine (MultiHance) in children. *Pediatr Radiol.* 2013; 43(2):202-211.
- Patil P, Deshmukh H, Popat B, Rathod K. Spectrum of imaging in Budd Chiari syndrome. *J Med Imaging Radiat Oncol.* 2012; 56:75-83
- Lu X, Xu K, Zhang QQ, Yang C, Li SD, Li JS, Rong YT, Zhu MH. Study on between magnetic resonance venography and digital subtraction angiography on the inferior vena cava obstructive interface morphology of Budd-Chiari syndrome. *Zhonghua gan zang bing za zhi= Zhonghua ganzangbing zazhi= Chinese journal of hepatology.* 2011 Dec; 19(12):923-6.