

Colonic Injuries; Is Primary Repair a Safe Option?

I U R KHAN K IRSHAD M A SHAFIQ B A KHAN A M CHAUDHRY

Department of Surgery, Mayo Hospital/King Edward Medical College, Lahore

Correspondence to Dr. Intesar-ur-Rashid Khan Senior Registrar e-mail intesarurrashidkhan@hotmail.com

Objectives: This study was conducted at Mayo Hospital, Lahore from April 2004 to May 2005 to compare the results of primary repair and exteriorization in cases of large gut injuries. **Materials and methods:** 80 patients, presenting in emergency between Jan. 2004 and December 2005, were selected out of which 63 were males and 17 were females. Colonic injuries were divided into five categories and were dealt accordingly. **Inclusion criteria:** All colonic injuries presenting to emergency in study period except. **Exclusion criteria:** Injuries requiring ileocolic anastomosis, repair and proximal fecal diversion and distal colonic injuries requiring Hartmann's procedure. **Key words:** Primary repair, colostomy.

Repair of colon wounds was historically a failure, from the first description in the Book of Judges, until World War I when occasional success was noted. Due to the high failure rate with primary repair during World War I, colostomy was mandated by Major General W. H. Ogilvie, the consultant surgeon of the Middle East Forces in the East African Command in 1943. The reasons for the high failure rate were delays in therapy as well as high velocity wounds, delay in effective resuscitation with an absence of blood banks, and minimal antibiotic development at that time. Improvements in trauma care resulted in decreased mortality from these wounds by the time of the Korean and Vietnam conflicts. In the 1950s, there were some surgeons who began to challenge the concept that colostomy was mandatory for management of all civilian colon injuries. The first prospective study done in 1979 laid the foundation for the modern treatment of colon injuries by confirming the safety and efficacy of primary repair in selected patients. During the 1980s, other investigators have advanced this concept. Exteriorization of colon repair with early drop back (5-7 days) into the peritoneal cavity was occasionally done during the period of time between 1960 and 1970, but has been abandoned in recent years. It is now recognized that almost all of those patients can be more appropriately treated by primary repair. The past decade witnessed an increasing interest in primary repair of colon wounds, and some have taken this concept one step further to colo-colostomy after resection of destructive wounds of the colon.

The risk factors for complications in colonic Injury management are:

1. Thin wall and sparse blood supply
2. Shock
3. Duration from injury to operative control
4. Presence of colonic bacteria
5. Associated injuries
6. Presence of peritonitis /fecal contamination
7. Forceful / mass peristalsis in colon
8. Anatomical location of injury
9. High velocity missile injuries

Materials and methods

This study was conducted at North surgical Unit, Mayo Hospital Lahore. A total of 80 patients presenting in emergency between Jan 2004 to Dec 2005 were selected. The Injuries requiring

ileocolic anastomosis, repair and proximal diversion and distal colonic injuries requiring Hartmann's procedure were excluded from the study. Primary repair was performed using prolene 4/0 interrupted sutures in single layer, in patients presenting early (< 12 hours since injury) with contamination limited to one quadrant only. In patients who presented late and /or with gross fecal contamination, exteriorization was performed.

Injuries were categorized into five grades;

I-Partial thickness Lacerations: which were repaired with inverting seromuscular sutures

II-Full Thickness Lacerations: Which were closed in two or single layer

III- Circumferential deserosalization injury of sigmoid colon: which were repaired primarily by re approximating the serosa

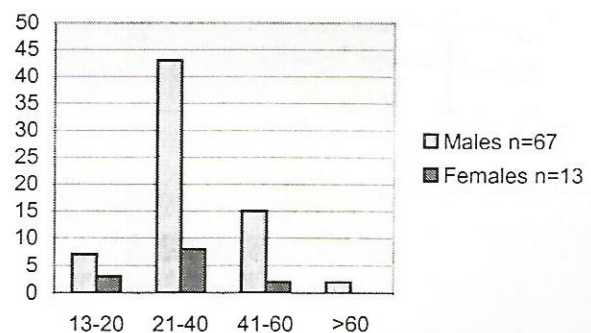
IV- Non destructive Lesions: involving 50% of bowel wall without devascularization: They were also repaired primarily in cases where there was peritonitis limited to single quadrant.

V- Destructive lesions: They include completely transected colon or that involves tissue loss and devascularised segment. They were managed with Colostomy

Table 1. Modes of injury

Mode	%age
<u>Penetrating</u>	
Gunshot	69%
Stabs	29%
Icepick	02%
<u>Blunt</u>	
Blunt	05
Air insufflation injury	01

Table 2 Age Distribution



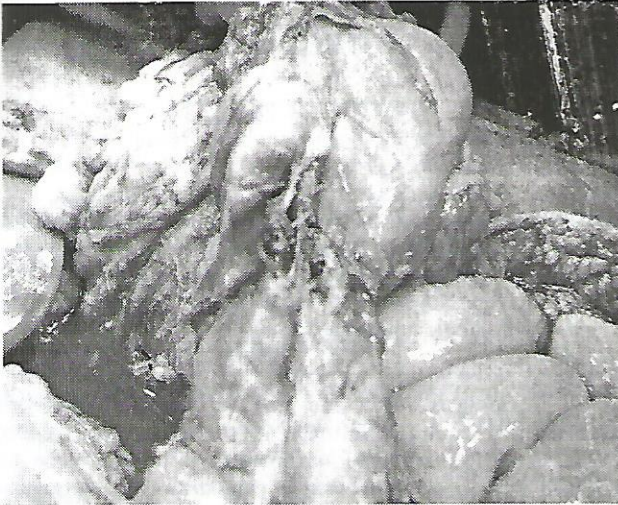


Fig.1:Non- Destructive colonic injury

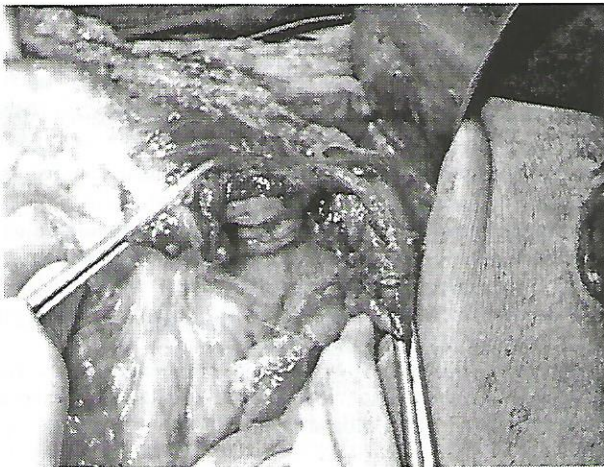


Fig.2: Destructive colonic injury

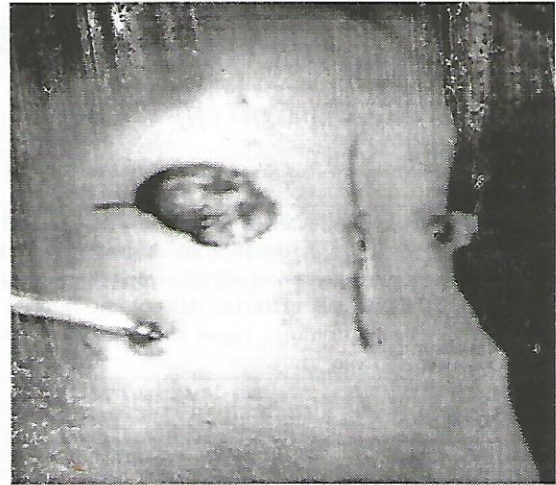


Fig 4. Colostomy

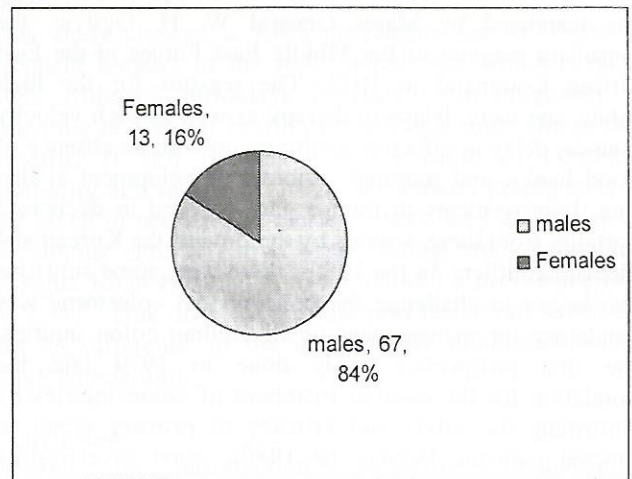


Fig 5: Ratio of males and females

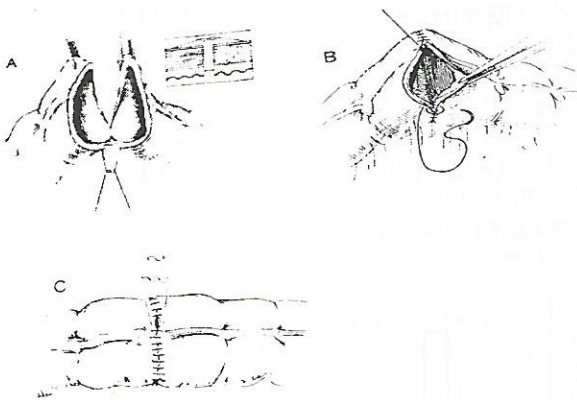


Fig. 3.Primary repair




Fig 6 Grade wise distribution of injuries

Results:

Out of 80 patients, 9% had Grade V injuries, 39% of patients presented with Grade I-III injuries. 52% of patients had Grade IV injury. All Grade V injuries were managed with colostomy as per recommendations. Out of the remaining 91% of patients, 49% fulfilled the criteria for Primary repair and the same was done in these patients. Remaining 42% were those patients who either presented late and / or had gross fecal contamination so these were managed by exteriorization. Among the patients with primary repair only 3 patients developed serious complication in the form of leak and exteriorization had to be performed in them all of these were high velocity fire arm injury victim. In the group of patients with exteriorization 4 patients has stoma related complications. In all the other patients post op recovery was unremarkable.

Discussion:

Management of penetrating colonic injuries has been evolving over the last thirty years. Before that time, the most colon wounds in the civilian population were managed by exteriorization of the wound or proximal colostomy because of a fear of a high rate of breakdown. In the past decade, there has been an increasing trend toward primary repair. Advantages of primary repair are the avoidance of colostomy, with the subsequent reduction in the morbidity of the colostomy itself and the cost associated with colostomy care and the subsequent hospitalization for reversal. Potential drawbacks of primary repair are the morbidity and mortality associated with failure of repair. If there were no difference in morbidity between the approaches, primary repair would be preferred. In recent years, there have been several prospective studies that support primary repair over colostomy; however, there is continued confusion as to when primary repair is appropriate.

Conclusion:

The decreased morbidity associated with avoidance of colostomy, the disability associated with the interval from creation to closure of the colostomy, and the charges associated with colostomy and the closure of the colostomy all support a standard for primary repair of non-destructive (Grade I-IV) colon wounds. For destructive (Grade V) colon wounds, the data would support resection and anastomosis for stable patients without significant associated injuries. Patients with serious associated

injuries or significant underlying disease have better results with resection and colostomy.

Time since injury, fecal contamination and high velocity injuries are other important factors to be considered while attempting primary repair.

References:

1. Stone HH, Fabian TC : Management of perforating colon trauma : Randomization between Primary closure and exteriorization. *Ann Surg* 190 : 430 – 6, 1979.
2. Chappuis CW, Frey DJ, Dietzen CD, et al : Management of Penetrating colon injuries. A Prospective Randomization trial. *Ann Surg* 213 : 492-7,1991.
3. Faleess RE, Wanamaker SR, Santanello SA, et al Colorectal trauma: Primary repair or anastomosis with intracolonic bypass vs ostomy. *Dis Colon Rectum* 35:957- 63. 1992
4. Sasaki LS, Allaben RD, Golwala R, et al: Primary repair of colon injuries: A prospective randomized study. *J Trauma* 39:895 -901, 1995.
5. Gonzalez RP, Merlotti GJ, Holevar MR: Colostomy in penetrating colon injury: Is it necessary? *J Trauma* 41:271-5. 1996.
6. George SM, Jr. Fabian TC, Voeller GR, et al: Primary repair of colon wounds. A prospective trial in nonselected patients *Ann Surg*.209:728-34, 1989
7. Baker LW, Thomson SR, Chadwick SJ: Colon wound Management and prograde colonic lavage in large bowel trauma *BJ Surg*. 77:872-6, 1990
8. Demetriades D, Charalambides D, Pantanowitz D: Gunshoi wounds of colon: Role of primary repair. *Ann R Coli Sure Engl* 74:381-4, 1992
9. Ivatury RR, Gaudino J, Nallathambi MN, et al: Definitive treatment of colon injuries: A prospective study. *Am Surg* 59:43-9, 1993
10. Thigpen JB Jr, Santelices AA, Hagan WV, et al: Current management of trauma to the colon. *Am Surg* 46:108-10,1980
11. Wiener I, Rojas P, Wolma FJ: Traumatic colonic perforation Review of 16 yearsi experience. *Am J Surg* 142:717-20-1981
12. Dang CV, Peter ET, Parks SN, et al: Trauma of the colon: Early drop-back of exteriorized repair. *Arch Surg* 117:652- 6, 1982