

Diode Laser Trans – Scleral Cyclo – ablation as a Primary Surgical Treatment for Primary Open – Angle Glaucoma after Maximum Tolerated Medical Therapy

Khalid Mahmood,¹ Muhammad Tariq Khan,² Jawad Bin Yamin Butt,³ Tariq Qureshi,⁴ Anwar-ul-Haq Ahmad⁵

Abstract

Introduction: The incidence rate and prevalence of glaucoma in Pakistan is similar to that of other dark – colored population countries. Primary trabeculectomy is still a preferred surgical approach. Diode laser is widely accepted as the therapy of choice in severe glaucoma cases. The purpose of this study was to determine the role of Diode Laser Trans-scleral Cyclo-ablation as a primary surgical treatment option in Primary Open Angle Glaucoma after maximum tolerated medical therapy.

Methods: This quasi – experimental study was conducted at Layton Rahmatullah Benevolent Trust Free Eye Care and Cancer Hospital, Lahore. Sixty patients fulfilling the inclusion criteria were selected from the Glaucoma unit for this study. 25 – 30 burns of Diode

Laser were applied to 270 degrees avoiding 3 and 9 o'clock positions, 1.5 mm posterior to the limbus. Laser was set at duration of 1 second and power between 1000 and 1500 mw. Patients were followed up for a period of one year.

Results: Out of a total of 60 eyes with mean age 52.73 ± 7.40 years, 36 (60%) were male and 24 (40%) were female. The mean pre-operative Intra Ocular Pressure IOP was 41.0 ± 7.0 mmHg (The pre-operative IOP ranged from 28 mmHg to 60 mmHg). The mean post-operative IOP was 18.97 mmHg on day one, 16.75 mmHg at 1 week, 15.68 mmHg at 1 month, 15.00 mmHg at 6 months and by the end of a year it was about 14.15 mmHg (The post-operative IOP ranged from 6 mmHg to 52 mmHg). There was a significant drop of more than 50% of post-operative IOP as compared to pre-operative IOP.

Conclusion: Diode Laser Trans-scleral Cycloablation is a practical, rapid, well – tolerated procedure that provides a significant lowering of intraocular pressure with few complications and can be considered as alternative treatment in POAG if medical therapy fails.

Key Word: Diode Laser, Trans-Scleral, Cyclo-ablation.

Mahmood K.¹

Associate Professor, Avicenna Medical College and Hospital, Bedian Road DHA Phase XI, Lahore – Pakistan

Khan M.T.²

Consultant Ophthalmologist, LRBT Eye Hospital, Lahore

Butt J.B.Y.³

Ophthalmologist, LRBT Eye Hospital, Lahore

Qureshi T.⁴

Ophthalmologist, LRBT Eye Hospital, Lahore

Ahmad A.U.H.⁵

Resident MO, LRBT Eye Hospital, Lahore

Introduction

Glaucoma is the major cause of irreversible blindness.^{1,7} The incidence rate and prevalence of glaucoma in Pakistan is similar to that of other dark – colored population of the developing countries, but concrete statistical evidence is lacking. According to a study

conducted in Lahore, 23% of the blindness is found to be caused by glaucoma.⁶

Long – term medical treatment is not feasible because of the high cost, poor compliance and sometimes low availability of medications. Glaucoma is often considered to be a surgical problem. Trabeculectomy with anti-metabolites is an effective treatment for primary open angle glaucoma.^{1,7} Primary trabeculectomy is still a preferred surgical approach all over for cases in which a larger reduction in IOP is the aim of the treatment, especially when high IOP persists in spite of administration of maximum tolerable anti glaucoma medication.^{2,8}

Diode Laser Trans-scleral Cycloablation (DLCA) has been used successfully for the treatment of refractory glaucoma, including those eyes in which other surgical treatments have failed.^{1,7} Diode laser is widely accepted as the therapy of choice in severe glaucoma cases and is suitable as a primary surgical procedure.^{4,5}

In developing countries, there is a shortage of both ophthalmologists and resources for eye care. Unfortunately, expensive medical and surgical treatment cannot be offered to every glaucoma patient. Therefore, DLCA is a thought to be simple, rapid and much less expensive surgical procedure for patients with POAG after maximum tolerated medical treatment. Diode laser is a safe, effective procedure to reduce the IOP in the treatment of different glaucoma with few severe complications. This study was intended to see the results of this technique in glaucoma patients and to assess the complications seen in these cases.

Materials and Methods

Sixty patients fulfilling the inclusion criteria were selected from the Glaucoma Unit of Layton Rahmatulla Benevolet Trust (LRBT) Hospital to be included in this study. After taking informed consent, socio-demographic data (name, age, sex, occupation) was recorded. A complete ophthalmological history was taken. Preoperative and postoperative examination was done by including visual acuity with Snellen Chart and IOP was measured with Goldmann applanation tonometer. Slit lamp examination with Haag Streit BQ – 900 was done for anterior segment evaluation. For fundus examination including evaluation of cup – disc ratio, super field 90D lens was used. Gonioscopic evaluation of anterior chamber angle with Goldmann triple mirror and perimetry with Humphry Visual Field Analyser was also done.

Treatment procedure included preoperative administration of peribulbar or sub tenon anaesthesia with 2% lignocaine HCL injection. Transscleral Diode Laser Cyclophoto-coagulation (“cyclodiode”) was performed using the Iridis Quantal laser machine. Laser was applied for duration of 1 second with power between 1000 to 1500 mw. The power was adjusted until a popping sound was heard and then reduced to just below that level. This power was thought to be low enough to cause complications and at the same time to produce desirable pressure lowering effects. Approximately 20 – 25 burns were applied 1.5 mm posterior to the limbus over 270 degrees. 3 and 9’0 clock positions were avoided to save the ciliary nerves. Oral NSAIDS, topical dexamethasone 0.1% eye drops along with antiglaucoma medication were continued for the 1st week. Anti glaucoma medication was tapered in accordance with the drop in intra-ocular pressure. Topical steroids, usually dexamethasone 0.1% eye drops, were prescribed four times a day for 2 – 4 weeks after treatment.

Follow up was recorded on 1st day, 1st week, 1st month, 6th month and 1 year. Re-treatment were only done in cases where the IOP was not achieved up to > 21 mm of Hg after 4th week of laser application. Reapplication of laser was done with 2 seconds duration and 2000 mw power. Post-operative management was remained unchanged.

Any complications encountered like anterior segment inflammation, hyphema and hypotony were also noted and managed.

Results

A total of sixty patients were included in the study, between the ages of 45 to 60 years and the mean age of patients was about 52.73 ± 7.40 years.

About 60% of the patients were male and about 40% were female. 52% operated eyes were right and 48% were left eyes. Most of the patients were using three or more anti-glaucoma drugs pre-operatively (Figure 1).

The mean pre-operative IOP was 41.0 ± 7.0 mmHg. The pre-operative IOP ranged from 28 – 60 mmHg (Table 1). The mean post-operative IOP was 18.97 mmHg on day one, 16.75 mmHg at 1 week, 15.68 mmHg at 1 month, 15.00 mmHg at 6 months and by the end of a year it was about 14.15 mmHg (The post-operative IOP ranged from 6 – 52 mmHg). There was a significant drop of more than 50% of

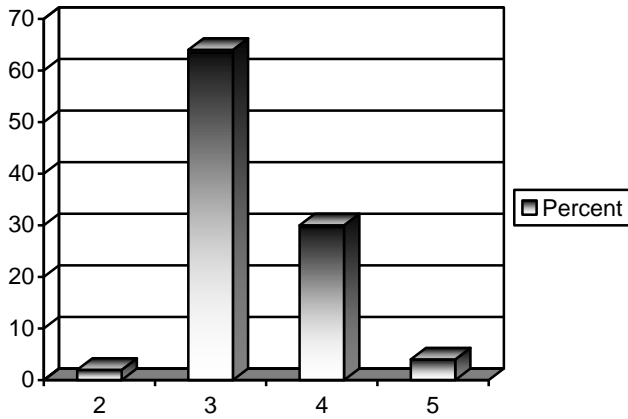


Figure 1: Number of Anti Glaucoma Medications being used prior to DLCA.

mean post-operative IOP as compared to mean pre-operative IOP (Figure 2).

Anterior segment inflammation was seen in only eight eyes (13.3%) out of 60 eyes. Mild hyphema in 5 eyes (8.3%) while 6 eyes (10%) developed hypotony.

Statistical Methods

Preoperative and postoperative mean Intra ocular

pressure was assessed using paired t test and final P-values were 0.00 which is less than 0.05, and this shows that the test is highly significant (Table 2). It shows that the reduction in IOP after application of DLCA at the end of one year is significantly lower than the pre-operative IOP. Complications recorded with Diode laser trans-scleral cycloablation were assessed using chi square test, that included anterior segment inflammation, hyphema and hypotony, and it showed that the minimum expected frequency is 30.0, and P value for each complication is 0.00 which is less than 0.05, showing that the complications rate is not significant.

Discussion

Diode laser cycloablation has developed an acceptable track record for the treatment of refractory glaucoma.⁹⁻¹² It has also been tried as a primary surgical treatment in different types of glaucoma.¹³⁻¹⁵ Complications profile is acceptable and most authors have reported insignificant and transient complications like pain and inflammation.¹⁶⁻¹⁸ Some surgeons are trying it as an alternative to drainage implant surgery in complex glaucoma.¹⁹ One limitation of the study may be that group consisted of a small number of 60 patients.

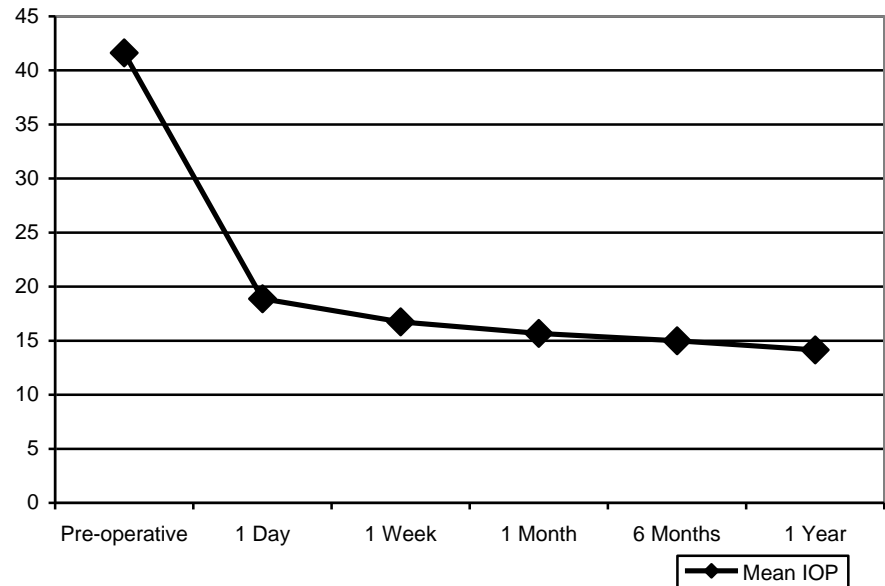
Table 1: Mean Pre-op and Post-op IOP.

	Pre-Operative IOP	Post-Operative IOP on day 1	Post-Operative IOP by Week 1	Post-Operative IOP by Month 1	Post-Operative IOP by Month 6	Post-Operative IOP by Month 12
Number of Pt.	60	60	60	60	60	60
Mean	41.62	18.97	16.75	15.68	15.00	14.15
Std. Deviation	8.61	9.86	8.26	8.41	7.44	6.60
Minimum	28	2	4	2	3	6
Maximum	60	40	38	46	50	52

Table 2: Paired Samples t-Test.

Group	Paired t-Test Statistics						
	Mean	SD	Mean Difference	Std. Deviation	t	Df	Sig. (2-tailed)
Pre-Op IOP	41.62	8.61	27.47	11.55	18.418	59	.000
Post-Op IOP by 12 Months	14.15	6.60					

P < 0.05. This shows that the reduction in IOP after application of DLCA at the end of one year is significantly lower than the pre-operative IOP.

Figure 2: Drop of Mean IOP Following DLCA.

However, sufficient follow-up information from all patients was obtained and the cases were included on consecutive basis.

No standard protocol has yet been agreed upon for the energy settings. Different settings have been used ranging from 1 Watt to 2.5 Watts Watts for 1 – 2 seconds.^{20,22} In othis study a power of 1000 – 1500 mw titrating with the pop sounds was used. Spencer and Vernon used a fixed setting and did not alter it to hear the pop sound.³

Oral NSAIDS, topical dexamethasone 0.1% eye drops along with antiglaucoma medication except miotics were continued for the 1st week. Anti glaucoma medication was tapered in accordance with the drop in intraocular pressure. Topical steroids, usually dexamethasone 0.1% eye drops, were prescribed four times a day for 2 – 4 weeks after treatment. A mean drop of 50.08% in IOP was noted in our patients. This is comparable to other studies mentioned above where a decrease of 20% – 65% in mean IOP has been reported.

Regarding the number of treatment sessions again there is no agreement on how many times the procedure should be repeated. Spencer and Vernon repeated the procedure up to five times.²² We had a maximum of 3 sessions in our series. Retreatment was done in 44% of which only 6% received 3 treatment sessions. Brancato et al¹⁸ and Bock et al²³ had a retreatment rate of 65% and 70% respectively. Nouredin et al²⁰ recommend that a high power setting results in better IOP control and lesser need for retreatment.

The drop in IOP was more than 50% and final IOP

was ± 14.15 mmHg. Results in literature vary from 48% – 92%.^{12,15,19,22} Reviewing the literature one finds that better success rate is seen with higher power settings and increased number of treatments. Egbert et al¹⁵ had a success rate of 48%. Their power settings were low and treatment repeated only in 20% cases. They recommend that higher power settings and repeated treatment would improve success but they were conservative because they were undertaking the procedure as a primary treatment. Highest rate we could find in literature is that of Gupta and Agarwal¹⁹ which is 92%. A striking difference in their method was that they treated 360 degrees instead of 270 degrees.

Murphy et al⁹ have also measured the sensitivity to cyclophotocoagulation and found chronic closure glaucoma and glaucoma secondary to retinal surgery to be the most sensitive to this treatment. Though we specifically did not measure the sensitivity but our findings seem to confirm this.

Most serious adverse effects of this therapy are hypotony and phthisis. Rates reported are highly variable. In our series there was no case of phthisis and hypotony occurred only in 6 out of 60 patients. In this study of Diode Laser Trans-scleral Cycloablation as primary treatment for primary open angle glaucoma, the treatment was, as hoped, quick and relatively simple to apply. Patient acceptance of treatment was excellent and patients found the procedure less frightening than trabeculectomy. The procedure seems safe as no major complications were observed.

Conclusion

The results shows that DLCA if applied carefully with relatively lower power and duration, is highly successful in achieving desirable IOPs in cases of PAOG after failed medical treatment. The treatment is most of the time single, lasts longer and cause less complications. High success and low complication rate combined with portability, durability and easy to learn technique may make diode laser cycloablation a favorable treatment option in cases of POAG with failed maximum tolerable medical therapy.

References

1. Reiss GR, Lee DA, Topper JE. Aqueous humor flow during sleep. *Investophthalmol viscid* 1984; 25: 776-8.
2. Davson H. *The Eye: Vegetative Physiology and biochemistry*. 3rd ed. San Diego: Academic press; 1984.
3. Leydhecker W. The intraocular pressure, clinical aspects. *Ann ophthalmol* 1996; 8: 389-90.
4. Duckman RH, Fitzgerald DE. Evaluation of intraocular pressure in pediatric population. *Optom Visci* 1992; 69: 705-9.
5. Becker M, Funk J. Diode laser cyclophotocoagulation as the primary surgical intervention in glaucoma. *Ophthalmologie* 2001; 98: 1145-8.
6. Jahangir S. A survey of blindness in eye patients in Punjab. *Pak J Ophthalmol* 1993; 9: 43-5.
7. Egbert PR, Fiadoyor S, Budenz DL, Dadzie P, Byrd S. Diaode laser transscleral cycloablation as a primary surgical treatment for primary open – angle glaucoma. *Arch Ophthalmol* 2001; 119: 345-50.
8. Jalal T, Mohammad S. Three years retrospective study of patients underwent trabeculectomy in Lady Reading Hospital Peshawar. *J Postgrad Med Inst* 2004; 18: 487-94.
9. CC Murphy, CAM Burnett, PGD Spry, DC Broadway, JP Diamond. A two centre study of the dose – response relation for transcleral diode laser cyclophotocoagulation in refractory glaucoma. *Br J Ophthalmol* 2003; 87: 1252-57.
10. Ataulah S, Biswas S, Artes PH, O'Donoghue E, Ridgway AEA, Spencer AF. Long term results of diode laser cycloablation in complex glaucoma using the Zeiss Visulas II system. *Br J Ophthalmol* 2002; 86: 39-42.
11. Martin KRG, Broadway DC. Cyclodiode laser therapy for painful, blind glauco Schlote T. Derse M. Zierhut M. Transscleral diode laser cyclophotocoagulation for the treatment of refractory glaucoma secondary to inflammatory eye diseases. *Br J Ophthalmol* 2000; 84:999-1003 matous eyes. *Br J Ophthalmol* 2001; 85: 474-476.
12. Schlote T. Derse M. Zierhut M. Transscleral diode laser cyclophotocoagulation for the treatment of refractory glaucoma secondary to inflammatory eye diseases. *Br J Ophthalmol* 2000; 84: 999-1003.
13. Heinz C, Koch JM, Heiligenhaus A. Transscleral diode laser cyclophotocoagulation as primary surgical treatment for secondary glaucoma in juvenile idiopathic arthritis: high failure rate after short term follow up. *Br J Ophthalmol*. 2006; 90 (6): 737-40.
14. Lai JS, Tham CC, Chan JC, Lam DS. Diode laser transscleral cyclophotocoagulation as primary surgical treatment for medically uncontrolled chronic angle closure glaucoma: long – term clinical outcomes. *J Glaucoma*. 2005; 14 (2): 114-9.
15. Egbert PR, Fiadoyor S, Budenz DL, Dadzie P, Byrd S. Diode laser transscleral cyclophotocoagulation as a primary surgical treatment for primary open angle glaucoma. *Arch Ophthalmol* 2001; 119: 345-350.
16. Bloom PA, Tsai JC, Sharma K, et al. Cyclodiode transscleral diode laser photocoagulation in the treatment of advanced refractory glaucoma. *Ophthalmology* 1997; 104: 1508-19.
17. Kosoko O, Gaasterland DE, Pollack IP, et al. The Diode laser ciliary ablation study group. Long term outcome of initial ciliary ablation with contact diode laser transscleral cyclophotocoagulation for severe glaucoma. *Ophthalmology* 1996; 103: 1294-302.
18. Brancato R, Carassa RG, Bettin P, et al. Contact transscleral cyclophotocoagulation with diode laser in refractory glaucoma. *Eur J Ophthalmol* 1995; 5: 32-9.
19. Gupta V, Agarwal HC. Contact trans – scleral laser cyclophotocoagulation treatment for refractory glaucomas in the Indian population. *Indian J Ophthalmol* 2000; 48: 295-300.
20. Nouredin BN, Zein W, Haddad C, Ma'luf R, Bashshur Z. Diode laser transcleral cyclophotocoagulation for refractory glaucoma: a 1 year follow-up of patients treated using an aggressive protocol. *Eye*. 2006; 20: 329-35.
21. Chang SH, Chen YC, Li CY, Wu SC. Contact diode laser transscleral cyclophotocoagulation for refractory glaucoma: comparison of two treatment protocols. *Can J Ophthalmol* 2004; 39 (5): 511-6.
22. Spencer AF, Vernon SA. "Cyclodiode": results of a standard protocol. *Br J Ophthalmol* 1999; 83: 311-316.
23. Bock CJ, Freedman SF, Buckley EG, et al. Transscleral diode laser cyclophotocoagulation for refractory pediatric glaucomas. *J Pediatr Ophthalmol Strabismus* 1997; 34: 235-9.