

Case Report

Hemodynamics of Constrictive Pericarditis: A Case Report

Nauman Naseer¹, Awais Hussain Kazim², Noor Anjum³

¹Head of Cardiology Department, Bahria International Hospital, Lahore; ²Fellow Cardiology, Bahria International Hospital, Lahore; ³Fellow Cardiology, Bahria International Hospital, Lahore

Abstract

To diagnose constrictive pericarditis requires a high degree of clinical acumen as the signs and symptoms overlap with other cardiac diseases. Usually as cardiologists, we encounter most of our disease burden labeled under ischemic and valvular heart disease and when encountered with constrictive pericarditis, an uncommon diagnosis, like this case report it can get overlooked. Early diagnosis can lead to definite treatment with surgical pericardiectomy. There is little room for medical therapy in constrictive pericarditis and in cases diagnosed too late, who develop advanced heart failure symptoms from it, don't derive as much benefit from surgical pericardiectomy. We are sharing this case report, where diagnosis of constrictive pericarditis was initially missed; and what work up we did for diagnosis with special focus on right heart catheterization with hemodynamics that we used to refer the patient for pericardiectomy.

Materials and Methods : For the right heart catheterization, Right groin area was sterilized with pyodine liquid and draped. The subcutaneous tissue was numbed with 10 ml of 2% lidocaine injection. The right femoral vein vascular access was taken via 6 Fr sheath. The Arrow® Double-Lumen Balloon Wedge-Pressure Catheter was used to obtain tracings of the right heart system. The right femoral artery access for taken via 5 Fr sheath. Pig tail catheter used to measure left ventricular pressures. This case has been reviewed and approved by the IRB (Institution review board) of Bahria International Hospital, Lahore. The literature for discussion was reviewed from Pub Med and internet search engines before submission.

Results and Conclusions : The right heart catheterization revealed the equalization of high diastolic pressures in each chamber of the heart, including the characteristic sign of ventricular interdependence between the left and right ventricles. In conclusion, despite advancement of CT technology, right heart catheterization remains an integral part of constrictive pericarditis workup. Tracings for constrictive pericarditis hemodynamics can be found in cardiology text books but it is emphasized that the reason for submission of the case report is that the right heart catheterization is not routinely done in most major cardiac centers in Pakistan and important serious diseases such as the aforementioned can be easily missed by not regularly performing this procedure.

Received | 03-07-2018: **Accepted** | 27-06-2019

Corresponding Author | Dr. Nauman Naseer, Head of Cardiology Department, Bahria International Hospital, Lahore

Email: nauman.naseer@gmail.com

Keywords | right heart catheterization, hemodynamics, heart failure

Introduction

The pericardium has two layers that surround the heart consisting of visceral and parietal pericardium. Between these layers is a thin film of liquid about

50ml in volume.¹ Constrictive pericarditis is present when a thickened and adherent pericardium restricts diastolic filling of the heart. The exact prevalence of constrictive pericarditis is not known but in some previous studies it is reported in 0.2–0.4% of patients

following cardiac surgery.^{2,3} It can occur through a variety of etiologies. Idiopathic and post-cardiac surgery cases are the two most frequent etiologies in the first world countries though tuberculous etiology forms a significant bulk in Pakistan⁴ and many developing countries.^{5,6} Other causes include radiation, rheumatologic diseases, malignancies and trauma. Worldwide, much work has been done regarding the investigations for constrictive pericarditis with echocardiography as the initial main tool. Other investigations include cardiac CT (computerized tomography), cardiac MR (magnetic resonance), cardiac PET (positron emission tomography) and of course right heart catheterization and hemodynamics on which our case report is based.

Case Report: A 65 year male diabetic, hypertensive (well controlled) history of ischemic heart disease status post PCI (percutaneous coronary intervention) to RCA (Right coronary artery) in 2004. He had been symptom free since then. He presented with 2 months history of recurrent chest pain, epigastric discomfort and shortness of breath on minimal exertion (NYHA III/IV). He also had progressive abdominal distention and pedal edema up to mid calves. There was history of cachexia, unintentional progressive weight loss and fatigue since 1 month.

On Examination, he was vitally stable. He had pallor, jugular venous pulse (JVP) was raised, bilateral pitting edema up to mid calves. Respiratory exam revealed normal vesicular breathing with decreased breath sounds on the right infrascapular region which was also dull to percussion. S1 and S2 were audible and normal intensity with no added sounds. Abdomen was soft, non – tender with shifting dullness.

Of notable labs, Hemoglobin 10.1 g/dL, White cell count $6.7 \times 10^9/L$, Platelets $138 \times 10^9/L$, Albumin 2.4 g/dL, Bilirubin 2.1 mg/dL, Creatinine 1.0 mg/dL, Urea 34 mg/dL, sodium 140 mmol/L, potassium 4.2 mmol/L. ECG showed normal sinus rhythm. Chest X-ray confirmed right sided effusion (Figure 1). Echocardiography of the initial workup revealed Ejection Fraction 50-55%, thickened pericardium, poor inferior vena cava collapse, and the left atrium was mildly enlarged. Ascitic fluid and pleural fluid had transudative results. Cardiac CT was also done which showed thickening of the pericardium.

Later a diagnostic angiography was done which showed LM (Left main artery) large caliber vessel. LAD (Left anterior descending artery) had 30-40% proximal mid disease. LCx (Left circumflex artery) had 50% proximal occlusion. RCA had chronic total occlusion.

With the above clinical information he was advised aspirin, statin and diuretics with plan to open the RCA-chronic total occlusion if symptoms did not remit. This initial work up and treatment plan was formulated at another facility.

With this history, the patient was brought to Bahria International Hospital, Cardiology department. His echocardiography was done again which along with the previous findings of Ejection Fraction 50 – 55 %, mildly enlarged left atrium, thickened pericardium, poor inferior vena cava collapse without respiratory variation also revealed mild tricuspid regurgitation, mild pulmonary hypertension and in diastology : E' at medial annulus was 16, lateral Annulus was 12. E/E' 14. This was consistent with annulus paradoxus, a feature in constrictive pericarditis.

To confirm our findings we carried out a right heart catheterization to look for the cardiac chamber pressures (figures 1-6).

(Below are the captions for the figures attached separately)

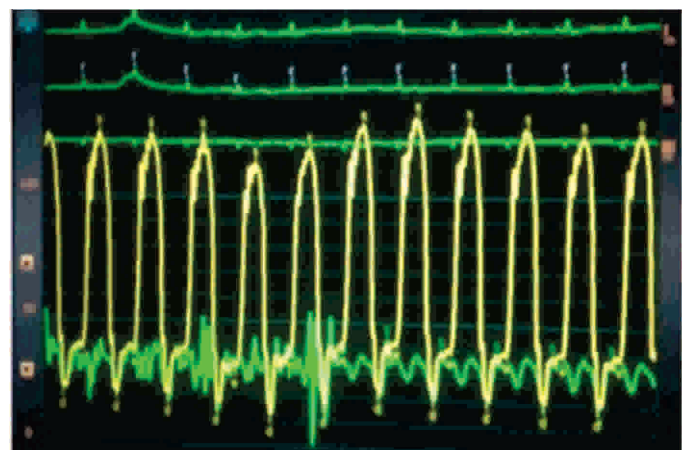


Figure 1: Pressures in RA (Right Atrium, Green Tracing) and LV (Left Ventricle, Yellow Tracing). Note Similar Diastolic Pressures. No Change in RA Pressures with Respiratory Variation Suggesting Kussmaul's Sign

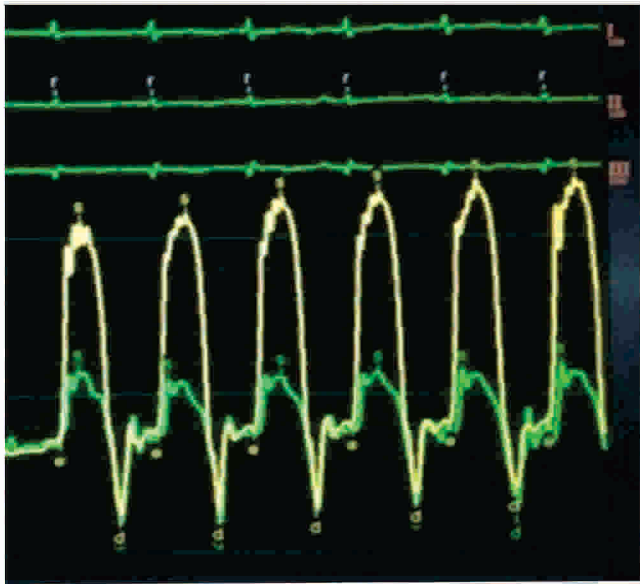


Figure 2: Pressures in RV (Right Ventricle, Green Tracing) and LV (Yellow Tracing). Similar Diastolic Pressures. Early Rapid Filling of LV and RV, Showing Square Root Sign. First Beat Shows Lower LV Pressure with Slightly Higher RV Pressure. With Progressive Increase in LV Pressure, RV Pressure does not increase and Remains Stable Suggesting Discordance Consistent with Ventricular Interdependence

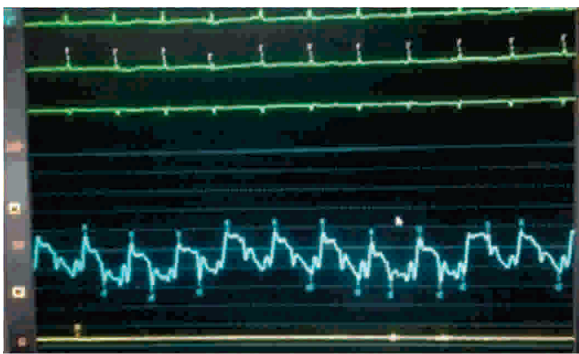


Figure 3: Tracing Show Elevated Pulmonary Artery Pressures (Blue Tracing) with Mild Pulmonary Hypertension

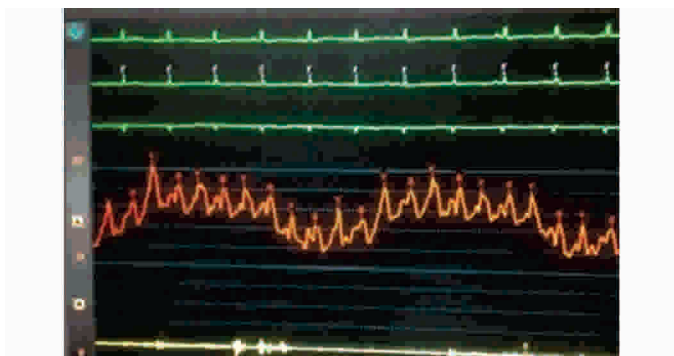


Figure 4: Tracing Show Elevated Pulmonary Capillary Wedge Pressure (PWCP, Orange Tracing)

Consistent with Diastolic Dysfunction

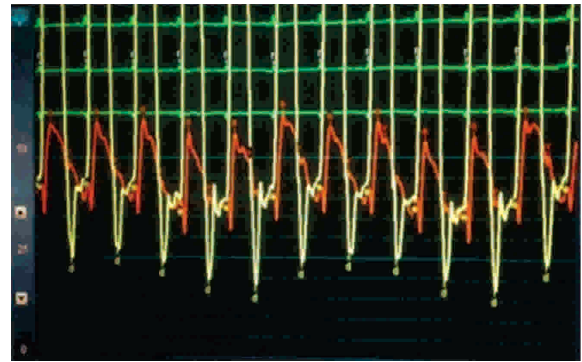


Figure 5: Simultaneous Tracings of PA (Pulmonary Artery, Orange Tracing) and LV (Yellow Tracing). There is Near Equalization of Diastolic Pressures

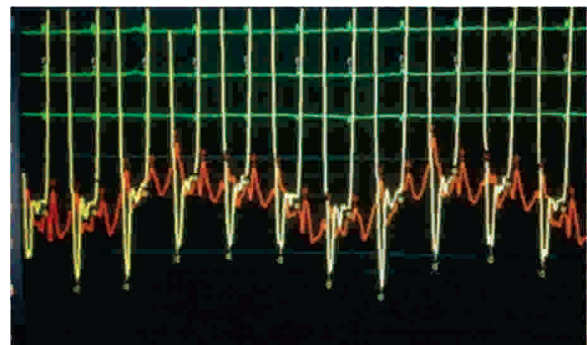


Figure 6: Simultaneous Tracings of PWCP (Orange Tracing) and LV (Yellow Tracing). There is near Equalization of Diastolic Pressures

The patient was referred to cardiac surgery. Within the next few days, pericardiectomy and graft to the RCA-CTO was applied. Pericardial specimen was sent for histopathology. The result was non-specific fibrous inflammation. Culture for TB was negative. The patient has been under follow-up since 8 months. The shortness of breath has resolved considerably to NYHA I. Right heart failure signs i.e. raised JVP, pedal edema and ascites have subsided.

Discussion

Constrictive pericarditis is a very treatable disease. Most chronic cases require surgical treatment. The main obstacle remains the diagnosis as it requires deep attention to details. Untreated, Constrictive Pericarditis is associated with a very poor prognosis¹⁷. Pericardiectomy though is the treatment of choice but is associated with significant morbidity and mortality. Before committing patients to surgery, it is important to be sure of the diagnosis which is mostly based on understanding of physiology and

hemodynamics and not just on pericardial thickening and calcification. In fact pericardial thickening > 4mm is not seen in 25% of cases and calcification is seen in not all but 75% of cases with surgically confirmed pericarditis who had preoperative CT imaging^[8]. It is very important to send the patient for surgery at the right time, as worsened pre-op NYHA status is associated with poor post surgical recoveries and outcomes^[9].

Echocardiography is the initial tool in the workup. Findings such as septal bounce, annulus paradoxus, severe diastolic function, inflow velocity differences during respiration are quite characteristic for constrictive pericarditis^[10]. Similarly characteristic findings, most of which were illustrated in the figures above, are seen in right heart catheterization which can confirm the diagnosis, not frequently done in Pakistan but still an inherent part of the workup. Other modalities include cardiac CT, cardiac MR, and cardiac PET. There is little room for medical therapy in constrictive pericarditis. Surgical pericardiectomy is the treatment of choice. Other factors contributing to poor prognosis include older age, poor functional status due to advanced NYHA class, low albumin, hyponatremia, co-existent coronary artery disease, low ejection fraction (EF), other co-morbidities including renal dysfunction and chronic obstructive pulmonary disease, and radiation induced constrictive pericarditis^[11].

References

1. Adler Y, Charron P, Imazio M, Badano L, Barón-Esquivias G, Bogaert J et al. 2015 ESC Guidelines for the diagnosis and management of pericardial diseases. *European Heart Journal*. 2015; 36(42): 2921-2964.
2. Im E, Shim C, Hong G, Yoo K, Youn Y, Chang B et al. The Incidence and Clinical Outcome of Constrictive Physiology After Coronary Artery Bypass Graft Surgery. *J Am Coll Cardiol*. 2013;61(20):2110-2112.
3. Syed F, Schaff H, Oh J. Constrictive pericarditis—a curable diastolic heart failure. *Nature Reviews Cardiology*. 2014;11(9):530-544.
4. Khan Khakar B, Khan S, Babar H. Surgical Experience of Chronic Constrictive Pericarditis at Quetta, Pakistan. *Pakistan Journal Of Medical Health Sciences*. 2012;6(1):63-65.
5. George TJ, Arnaoutakis GJ, Beaty CA, Kilic A, Baumgartner WA, Conte JV. Contemporary etiologies, risk factors, and outcomes after pericardiectomy. *Ann Thorac Surg*. 2012;94(2):445-451.
6. Oreto L, Mayer A, Todaro M, Mori N, Kress D, Kleinman L et al. Contemporary clinical spectrum of constrictive pericarditis: A 10-year experience. *Int J Cardiol*. 2013;163(3):339-341.
7. Miranda W, Oh J. Constrictive Pericarditis: A Practical Clinical Approach. *Progress in Cardiovascular Diseases*. 2017;59(4):369-379.
8. Murashita T, Schaff H, Daly R, Oh J, Dearani J, Stulak J et al. Experience With Pericardiectomy for Constrictive Pericarditis Over Eight Decades. *The Annals of Thoracic Surgery*. 2017;104(3):742-750.
9. Gillaspie E, Stulak J, Daly R, Greason K, Joyce L, Oh J et al. A 20-year experience with isolated pericardiectomy: Analysis of indications and outcomes. *J Thorac Cardiovasc Surg*. 2016;152(2):448-458
10. Miranda W, Oh J. Constrictive Pericarditis: A Practical Clinical Approach. *Progress in Cardiovascular Diseases*. 2017;59(4):369-379.
11. Constrictive pericarditis [Internet]. Uptodate. com. 2017 [cited 29 December 2017]. Available from: https://www.uptodate.com/contents/constrictive-pericarditis?source=history_widget#H21