

Case Report

An Unusual Intravesical Foreign Body in a Female Child: A Case Report and Literature Review

Shamsul Islam¹, Syed Maaz Abdullah², Hafiz Mudabbar Mahboob³, Uzma Malik⁴

¹Assistant Professor of Urology, KEMU/ Mayo Hospital, Lahore; ²House Officer, Mayo Hospital, Lahore; ³House Officer, Mayo Hospital, Lahore; ⁴Assistant Professor of Medicine, KEMU/ Mayo Hospital, Lahore

Abstract

Intravesical foreign body is a well-documented presentation in adults, however in children, it is rarely reported. We report a case of 5-years-old girl who presented with increased frequency of micturition, dysuria and fever. On examination, we found suprapubic tenderness and ultrasonography revealed a 1.5cm stone in the bladder. Diagnosis of vesical calculus was made and suprapubic cystotomy was done for stone retrieval. Stone turned out to be a foreign body (matchstick) and this alongwith the encrusted stone was removed. Later on, she admitted to inserting the match stick accidentally during play. Intravesical foreign body should always be included as a cause of vesical calculus in children, but its diagnosis requires a high index of suspicion. The mode of removal of foreign body should be tailored to its size, shape and nature, age and condition of the patient, and to the place and anatomy of urinary tract where it is lodged.

Received | 02-03-2018: **Accepted** | 03-07-2019

Corresponding Author | Dr Syed Maaz Abdullah, House Officer, Mayo Hospital, Lahore

Email: maaz-here@hotmail.com

Keywords | Intravesical, foreign body, children, cystostomy.

Introduction

Intravesical foreign body (FB) is an uncommon but a well-documented presentation in adults, however in children, it is still rarely reported.¹⁻³ In children, a FB is most commonly introduced into the bladder through the urethra, and that too mostly due to their inquisitive nature.⁴ Other causes in children include assault, be it sexual or otherwise, iatrogenic causes, or from migration from adjacent organs.⁵ The psychiatric, autoerotic and therapeutic causes of self-insertion of FBs are majorly reported in adults and have been rarely observed in paediatric age group.⁶ We report to you a case of a young girl who did not inform her parents about self-insertion of a matchstick into her bladder, and gradually developed severe urinary symptoms 6 weeks later.

Case report

A 5 year old girl presented to urology department with gradually intensifying lower urinary tract symptoms (LUTS) for 6 weeks. She complained of severe dysuria, burning micturition and increased frequency of micturition. She had also developed fever of 39 °C on the day of presentation. On physical examination, all the findings were normal except for suprapubic tenderness. Genital and gynaecological examinations were unremarkable. Urine analysis showed pyuria (with few pus cells) and microscopic haematuria. Blood urea and creatinine were normal. Plain X-ray of pelvis only showed a dim radiopaque shadow in the region of bladder. Kidney, ureter and bladder (KUB) ultrasonography revealed a 1.5cm stone in the urinary bladder. Open cystotomy was planned for stone

retrieval. During the operation, when the bladder was opened, it was discovered that the stone was actually encrusted on the centre of a matchstick of length 5.5cm. It was neither detected on pelvic radiogram nor on KUB ultrasonography. The matchstick along with the encrusted stone was successfully removed.

During the postoperative hospital stay, the child was retrospectively asked about any history of ingestion of matchstick. On probing, child remembered putting match stick while playing. Apart from this incident, no prior history of FB ingestion or inhalation was found. She said she did not tell her parents out of fear that they may rebuke her. She was also not mature enough to relate the symptoms which she developed to FB insertion. As the reported incident was very uncommon with respect to her age so, a psychiatric referral was advised for relevant evaluation and appropriate counselling and the child was discharged. Postoperative follow up after 2 weeks was also unremarkable and the child had successfully recovered.

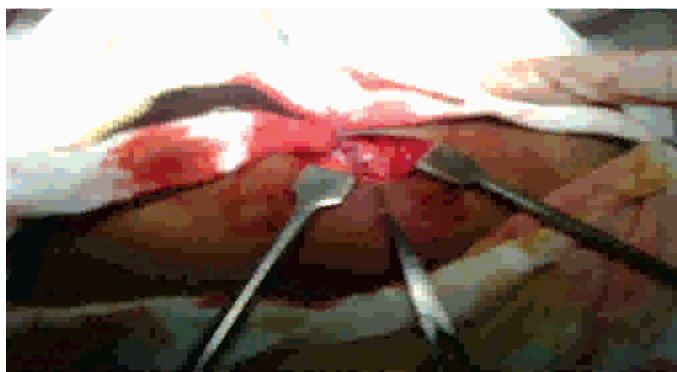


Figure 1: Perioperative image showing matchstick just after retrieval.



Figure 2: Matchstick with encrusted stone in its centre.

Discussion

The urinary bladder is the most common site for

foreign bodies in the urogenital tract. Intravesical foreign bodies pose a challenge to urologists.⁷ It should always be included as a cause of vesical calculus in children especially females as vesical calculi are almost always secondary in females.⁸ The diversity of objects reported to be found in the bladder is surprising.⁹ Some of the FBs listed in literature include metal objects, paperclips, hair pins, plastic caps, wires, thermometers, catheters, pencils, bamboo sticks, pieces of latex gloves, abdominal swabs, intrauterine devices (IUD) and surgical gauze.^{2,9-11} The incidence of foreign bodies in the urinary bladder is found to be gradually ramping up, partly because of the increased surgical procedures being performed nowadays (which in turn lead to increased iatrogenic FB introduction).³ The diagnosis of intravesical FB requires a high degree of suspicion particularly when no history of self-infliction is given and/or the foreign body is masked by the encrusted calculus on pelvic ultrasonography.^{5,12} Children may not reveal the history of self-insertion of FBs, perhaps out of fear of their parents that they (the parents) may reprimand them on what they have done, and also partly due to them being oblivious of the potential complications of intravesical FBs which may result. This may cause them to present late and with accentuated lower urinary tract symptoms. Prompt surgical intervention is crucial after diagnosis of intravesical FBs as delay leads to increased incidence of complications like stricture and stone formation, hydronephrosis, enterovesical fistulae and even renal failure.

The mode of removal of FB is dictated by its size, shape and nature, age and condition of the patient, and the place and anatomy of the urinary tract where it is lodged.^{4,9,13} Minimally invasive cystoscopic extraction is always the first line management option for foreign bodies which are relatively small and extractible without causing any significant trauma. For foreign bodies which have uncertain length or diameter, or those which are unusually large, open cystotomy is more preferable and safer option. The small diameter of urethra in children usually precludes the use of endoscopic techniques for FB removal due to the risk of urethral trauma and makes open cystotomy a favourable option for the operating surgeon which was the case in our setting.^{9,14,15} Another option, namely percutaneous FB retrieval using direct transurethral visualisation, is advocated by some

authors but this procedure, if performed without adequate synchrony between both approach sites, may lead to injury to other organs as compared to open cystotomy in which the route for visualisation and retrieval is direct and same.¹⁶ Postoperative follow-up is however necessary to rule out any complications of open surgery that may rarely develop.

Conclusion

Intravesical foreign body should always be included as a differential diagnosis in children presenting with a history of LUTS.¹⁷ This case report highlights the importance of focusing on history for ruling out an iatrogenic cause when radiological investigations suggest a vesical calculus in a female child. Once a definitive diagnosis is made, open cystotomy is a safe surgical procedure in children for extraction of foreign body of uncertain size and dimensions with minimum postoperative complications. However, there is still a need to explore minimally invasive cystoscopic procedures for extraction of small FBs with definite dimensions as this will further reduce hospital stay and related morbidity and thus, may prove to become a treatment of choice in children with intravesical FB.

References

- 1 Sharma G, Parmar KM, Lanka P, Singh SK. Unusual cause of bladder and urethral stones in a child. *BMJ Case Rep.* 2018;11(1):1.
- 2 Fath elbab T, Abdelhamid A, Galal E, Anwar A, Malek M, Tawfik E. Management of intravesical self-inflicted sharp objects in children: 10-year single-center experience. *Journal of Pediatric Urology.* 2016;12(2):97.
- 3 Mannan A, Anwar S, Qayyum A, Tasneem R A. Foreign bodies in the urinary bladder and their management: a Pakistani experience. *Singapore Med J.* 2011;52(1):24-28.
- 4 Mujagić S. Foreign body in the urinary bladder of 14-year-old boy: case report and review of literature. *Paediatrics Today.* 2015;11(1):54-58.
- 5 Al-Okour RK, Al-Ghawanmeh HM, Al-Ghazo M. Intravesical foreign body: The forgotten and forsaken diagnosis? A case report and review. *J Integr Nephrol Androl.* 2017;4(3):104-6.
- 6 Li Y, Gao Y, Chen X, Jiang S. Rare foreign body in bladder: A case report. *Medicine (Baltimore).* 2018; 97(17).
- 7 Soomro H, Jalbani IK, Faruqi N. Intravesical foreign body: tertiary care center experience from Pakistan. *JPMA: Journal of Pakistan Medical Association.* 2016;66(10):131-133.
- 8 Aziz el M, Amrani M, Abdelhak K, Hassan FM. A fragment of Foley catheter balloon as a cause of Bladder stone in woman. *Pan Afr Med J.* 2015; 21(1):284.
- 9 Rafique M. Intravesical foreign bodies: review and current management strategies. *Urol J.* 2008;5(4): 223-31.
- 10 De Silva WSL, Kodithuwakku K, Aponsu GUE, Rathnayake RMM, Rajasegaram E. A large bladder stone caused by the intravesical migration of an intrauterine contraceptive device: a case report. *J Med Case Rep.* 2017;11(1):293.
- 11 Singha Mahapatra R, Priyadarshi V, Sarma Madduri V, Pal D. Transrectal impalement of an incense stick in a child presenting as foreign body in the urinary bladder. *Case Reports.* 2014;bcr2014204689.
- 12 Thatte A, Rajendran S, Murphy L, Allen M. Intravesical foreign body: clinical features and diagnostic clues. *Case Reports.* 2014;bcr2014204828.
- 13 Dardamanis M, Balta L, Zacharopoulos V, Tatsi V, Tzima H. An Unexpected Foreign Body (a Thermometer) in the Bladder: A Case Report. *Urol Case Rep.* 2014;2(2):65-6.
- 14 Bansal A, Yadav P, Kumar M, Sankhwar S, Purkait B, Jhanwar A, et al. Foreign Bodies in the Urinary Bladder and Their Management: A Single-Centre Experience From North India. *Int Neurourol J.* 2016;20(3):260-9.
- 15 Levine MA, Evans H. Open removal as a first-line treatment of magnetic intravesical foreign bodies. *Can Urol Assoc J.* 2013;7(1):E25-8.
- 16 Hutton KAR, Huddart SN. Percutaneous retrieval of an intravesical foreign body using direct transurethral visualization: a technique applicable to small children. *Br J Urol Int.* 1999;83(6):337-8.
- 17 Bansal A, Kumar M, Kanodia G, Aeron R, Goel S. Unusual intravesical foreign body in young female migrated from vagina due to autoerotism. *Int Braz J Urol.* 2017;43(3):556-560.