

## A Comparative Analysis of Sextant and Extended 5 – Region 13 Core Trans-rectal Ultrasound Guided Prostate Biopsy

Kamran Zaidi,<sup>1</sup> Khizar Hayat,<sup>2</sup> Fawad Nasar Ullah,<sup>3</sup> Mumtaz Ahmed,<sup>4</sup> Ahmed Salman Waris<sup>5</sup>  
Sajjad Husain<sup>6</sup>

### Abstract

**Objective:** To compare the diagnostic value of Extended 5 – Region (13 core) Trans-rectal Ultrasound guided Prostate Biopsy with Standard Sextant Biopsy.

**Materials and Methods:** 60 patients underwent transrectal ultrasound guided biopsy of prostate. In addition to sextant biopsies, cores were taken from far lateral and mid regions of the gland. Pathological findings

Principal, Mian Nawaz Sharif Medical College, Gujrat of the additional regions were compared to those of the sextant regions.

**Results:** We performed 5 – region trans-rectal ultrasound guided prostate biopsy of 60 patients. The reason for biopsy was abnormal digital rectal examination in 10 patients (16.7%), elevated PSA in 26 (43.3%) and combined abnormalities in 24 (40%). Out of these 60 cases, 37 (61.6%) came out to have prostate cancer. Of the cancer patients 5 (13.5%) had an abnormal digital rectal examination, 14 (37.8%) had elevated PSA and 18 (48.6%) had both abnormalities. Among these 37 positive for carcinoma prostate cases, 22 patients were positive for prostate cancer in additional (zone 1, 3, 5) as well as sextant regions (zone 2, 4), 12 patients had cancer only in additional region 1, 3 and 5 and 3 patients were positive for prostate cancer in sextant regions alone.

**Conclusion:** Five region technique of prostate biopsy is an efficient mean of significantly increasing the diagnostic yield of prostate biopsy in finding carcinoma of the prostate. We have found this technique to be safe, efficacious and superior to sextant biopsies in diagnosing prostate cancer in patients with a PSA level of less than 10 ng / ml.

**Key Words:** Sextant and extended systematic 5 – region trans-rectal ultrasound guided prostate biopsy, Carcinoma of prostate.

---

Zaidi K.<sup>1</sup>  
Department of Urology, PGMI / Lahore General Hospital,  
Lahore

Hayat K.<sup>2</sup>  
Assistant Professor Department of Urology, PGMI / Lahore  
General Hospital, Lahore

Nasar Ullah F.<sup>3</sup>  
Senior Registrar, Department of Urology, PGMI / Lahore  
General Hospital, Lahore

Ahmed M.<sup>4</sup>  
Associate Professor Department of Urology, PGMI / Lahore  
General Hospital, Lahore

Waris A.S.<sup>5</sup>  
Professor of Department of Urology, PGMI / Lahore  
General Hospital, Lahore

Hussain S.<sup>6</sup>

### Introduction

Pakistan has a high incidence of cancer, from its inde-

pendence in 1947 to the present The escalating burden of non-communicable diseases worldwide warrants an urgent public health response, especially for Pakistan.<sup>1</sup> Prostate cancer is one of major problem facing by male population.<sup>2</sup> Adeno-carcinoma of prostate is multifocal and heterogeneous disease. Both low and high grade disease can be present simultaneously.<sup>3</sup> Considerable attention has been focused on early detection during the last decade using Prostate Specific Antigen (PSA), Digital Rectal Examination (DRE), TRUS and TRUS guided prostatic biopsy. By this method prostate cancer is detected at an early stage when it is organ confined, to decrease morbidity and mortality associated with the disease.<sup>4</sup> Not all prostatic malignancies are palpable on DRE. When DRE findings are correlated to pathological evaluation, under staging and over staging are often found. Consequently DRE fails to detect a significant number of malignancies. Among those which are detected by DRE, a significant number is at an advanced stage. Final diagnosis of prostate cancer can only be reached by histological confirmation of cancer cells on biopsy tissue.<sup>5</sup> Although a PSA level greater than 4ng/ml is considered elevated, age adjusted normal PSA values have been established. A rising PSA over time though less than 4 ng/ml may also be an indication for biopsy, especially in high – risk group. A change in PSA value or PSA velocity of more than 0.75 ng/ml per year was a specific marker for presence of prostate cancer<sup>[6]</sup> The advent of transrectal Ultrasonography offered a new way to evaluate the prostate. The trans-rectal ultrasound guided biopsy became standard urological procedure for detecting prostate cancer.<sup>7</sup> Prostate biopsy using trans-rectal ultrasound guidance involves removal of a series of randomly distributed cores of tissue from the posterior aspect of the prostate, the region believed to harbor the majority of prostate cancers. Two decades ago 2 to 4 biopsy cores were removed. After 1989, 6 cores (the sextant biopsy technique) became the standard for about a decade. Svetec et al (ref 8 of beyond) in 1998 demonstrated a 45.6% false negative rate of sextant biopsy. It was established that with 6 cores, many tumors are missed So 10 to 12 cores biopsy became popular.<sup>8</sup>

## Methodology

Patients were selected from Urology in-door and outdoor departments of Lahore General Hospital, Lahore. Full informed and written consent that outlines alter-

natives, consequences, and complications of biopsy was obtained prior to the procedure. All patients were given a 3 – day course of oral antibiotics (ciprofloxacin 500 mg and metronidazole 400 mg) started a night before biopsy. All patients had their bleeding profile PT APTT INR and platelet count a day before biopsy. Patients on anticoagulant were instructed not to take anti-platelet and anticoagulant drugs at least five days before biopsy, and their bleeding profile checked. All patients were given bowel cleansing with an enema at least two hours before the procedure starts. Adequate analgesia was provided by intravenous administration of (nalbuphin at dose of 0.1 mg/kg body weight) before the procedure starts, also instilling 10 cc of 2% intrarectal xylocain gel 5 – 10 minutes before the procedure to provide local anesthesia. Patients were placed in left lateral decubitus position with knees and hips flexed 90 degree. Transrectal ultrasound was performed and prostate volume was calculated using the formula for the volume of ellipsoid  $4\pi/3 \times \text{major axis}^2 \times \text{minor axis}$ . For biopsy, prostate was imaged in sagittal plane.

Prostate biopsy was performed under transrectal ultrasound guidance using a 5 MHZ rectal probe, fitted with transrectal puncture adaptor and an automatic spring – loaded biopsy gun. Each patient underwent 5-region method of biopsy regardless of the ultrasound appearance of prostate cancer.

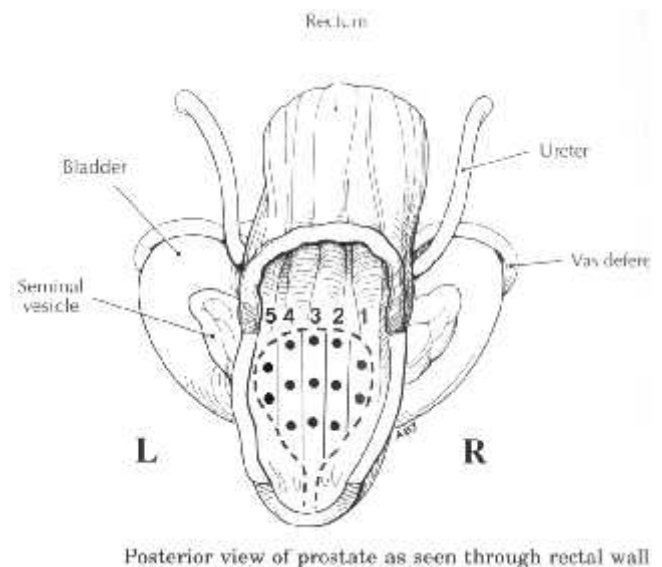
The 5 region biopsy technique was included taking Sextant biopsies as described by Hodge et al, half way between midline and lateral border 3 cores were taken from the right and 3 from the left prostatic lobe at apex, mid – gland and base. In addition, 2 biopsies were obtained from each lateral aspect of gland and 3 from the middle of the prostate. At least 13 biopsies per patient were taken.

The core biopsy specimens from each zone was sent separately and labeled according to the right lateral region (region 1), right mid (region 2), middle (region 3), left mid (region 4), and left lateral (region 5) areas. Core samples were sent to histopathologist and reported as cancer with an assigned Gleason Score. Biopsy findings from region 1, 3 and 5 were compared to those of region 2 and 4, which are the conventional sextant regions. Results were analyzed to find out the superiority or otherwise of extended systematic 5-region prostate biopsy over conventional Sextant biopsy in detecting prostate cancer. Statistical analysis comparing the results of biopsies of these regions was performed.

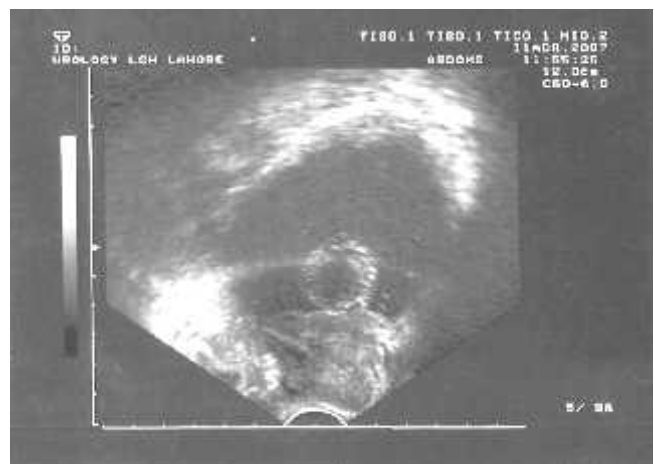## Results

The mean age of patients with benign prostatic conditions was  $66.9 \pm 10.61$  years (range 46 – 81 years), while that for adeno-carcinoma was  $70 \pm 11.4$  years (range 50 – 98 years) ( $p < 0.01$ ) (Fig. 1).

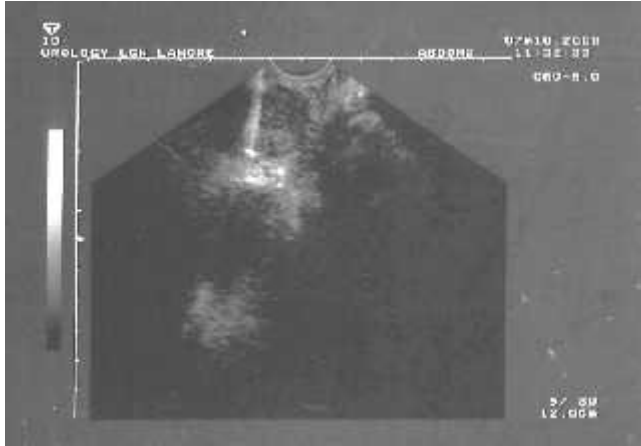Twenty nine patients (48.3%) presented with irritative lower urinary tract symptoms, 19 (31.7%) patients with irritative and obstructive symptoms and four patients (6.7%) with general weakness and lower back pain; one of them had chronic anemia and weight loss. Urinary retention was found in 31 patients (51.7%). Transurethral resection of the prostate (TURP) was done for 43 patients to relieve urinary obstruction after



**Fig. 1:**



**Fig. 2:** TRUS view of prostate and urinary bladder.



**Fig. 3:** TRUS guided prostate biopsy image showing biopsy Needle through a hypoechoic lesion.

the histopathological biopsy report (Fig. 2).

The reason for biopsy was abnormal digital rectal examination in 10 patients (16.7%), elevated PSA in 26 (43.3%) and combined abnormalities in 24 (40%). Of the 60 patients who underwent trans-rectal ultrasound guided prostate biopsy 37 (61.6%) had prostate cancer. Of the cancer patients 5 (13.5%) had an abnormal digital rectal examination, 14 (37.8%) had elevated PSA and 18 (48.6%) had both abnormalities (Table 1). Mean PSA for the cancer cohort was  $9.9 \pm 1.9$  ng/ml (95% confidence interval 7.75 to 12.06), which compared to a mean PSA of  $8.3 \pm 1.4$  ng/ml for patients without cancer (95% confidence interval 6.79 to 9.74).

Of the 37 patients with prostate cancer 12 (32.4%) had carcinomas only in regions 1, 3 and 5 (right lateral, middle and left lateral lobes). These tumors would have been undetected had the sextant biopsy technique been used (Table 2). This difference was statistically significant ( $p < 0.05$ ).

Of 13 patients (35.1%) with clinical stage T<sub>1c</sub> disease (nonpalpable) 5 (38.5%) had carcinoma of the prostate in regions 1, 3 and 5 only, which would have been missed by the standard sextant biopsy technique. Of 24 patients (64.9%) with stage T<sub>2</sub> lesions (palpable) 7 (29.2%) had cancer in zones 1, 3 and 5 only, which would have been missed by the sextant method (Table 2).

Serum PSA was correlated with digital rectal examination findings and regions of positive biopsy. Of 9 patients with stage T<sub>1c</sub> disease and a PSA of 4 to 10 ng./ml. 4 (44.4%) had carcinoma only in the additional regions, compared to 1 with stage T<sub>1c</sub> disease and a

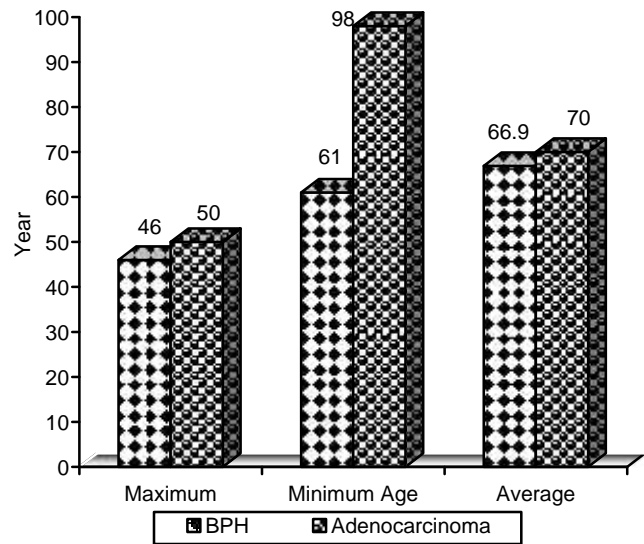
PSA of greater than 10 ng./ml, and 5 of 13 (38.4%) with palpable stage T<sub>2</sub> lesions and a PSA of less than 10 ng./ml. Only 2 of 11 patients with palpable stage T<sub>2</sub> disease cancer and a PSA of greater than 10 ng./ml was identified with the 5 region technique (Table 3).

Of the 37 patients with carcinoma 22 had a PSA of 10 ng/ml or less. Among these 22 patients 9 (40.9%) were diagnosed with the 5 region technique and not standard sextant biopsies. However, of the remaining 15 cancer cases out of 37 with a PSA of greater than 10 ng./ml. only 3 (15.0%) were diagnosed with the 5 region technique. Of the patients with a PSA of more than 10 ng./ml. 90% were diagnosed with the standard sextant biopsy method (Table 4).

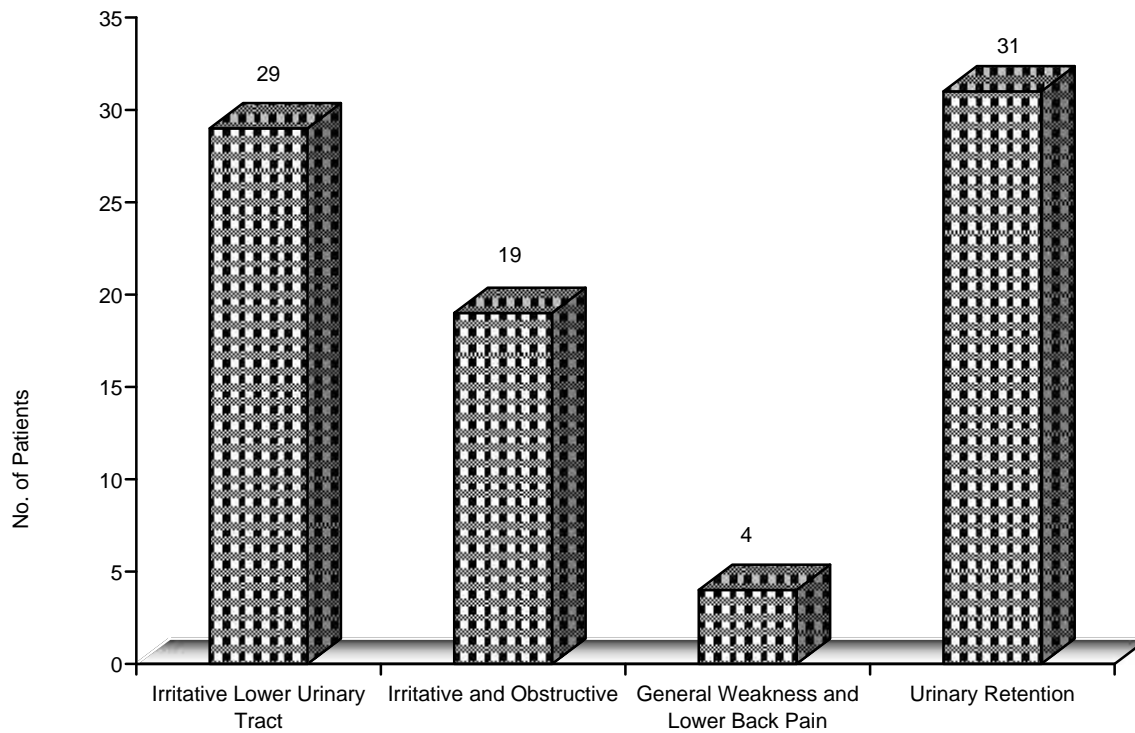
Among the 37 patients with cancer 4 (10.8%) were referred for radical prostatectomy, while 8 (24.2%) received external beam radiation therapy 1 (2.7%) patient received brachytherapy along with external beam radiation therapy at Agha Khan hospital. Due to advanced disease 15 patients (40.5%) were treated with androgen deprivation therapy: 7 (18.9%) are being followed with watchful waiting and 2 (5.4%) refused treatment.

Thirty seven (37) patients were detected positive in a study, in which 34 patients were detected in additional regions, biopsy method (region 1, 3, 5), in which

22 patients were also positive in sextant biopsy region (2, 4 regions, Gold standard) and were considered positive for Ca prostate with a sensitivity of 88% and specificity of 66% (positive predictive value 65% and negative predictive value 88%).



**Fig. 4:** Age ranges and mean of benign and carcinoma patients.



**Fig. 5:** Symptoms.

**Table 1:**  
Reason for Biopsy No. of Patients (%).

	Totals	Positive Digital Rectal Examination	PSA More Than 4.0 ng/ml	Both Abnormal
Ca	37 (61.6)	5 (13.5)	14 (37.8)	18 (48.6)
NoCa	23 (38.4)	5 (21.7)	12 (52.2)	6 (26.1)
Totals	60	10 (16.7)	26 (43.3)	24 (40)

**Table 2:** Regions of positive biopsies.

	No. of Patients	No. of Positive Biopsy (%)		
		In Regions 1, 3 and 5 Only	In Regions 2 and 4 Only (Sextant)	In Sextant and Additional Regions
Ca cohort	37	12 (32.4)	3 (8.1)	22 (59.5)
Clinical stage T <sub>1c</sub> Ca	13 (35.1)	5 (38.5)	2 (15.4)	6 (46.1)
Stage T <sub>2</sub> Ca or greater	24 (64.9)	7 (29.2)	1 (4.2)	16 (66.6)

Comparison between regions 1, 3, 5 and regions 2, 4: p value < 0.05 using Chi square test.

**Table 3:**  
Correlation of digital rectal examination and PSA with positive prostate biopsy.

No. of Patients	PSA range (ng/ml)	No. of Positive. / Total No. of Patients (%)	In Regions 1, 3 and 5 only
Normal digital rectal examination (stage T <sub>1c</sub> Ca)			
20	4 – 10	9/20 (45.0)	4/9 (44.4)
9	More than 10	4/9 (44.4)	1/4 (25)
Abnormal digital rectal examination (stage cT <sub>2</sub> Ca or greater)			
20	4 – 10	13/20 (65.0)	5/13 (38.4)
11	More than 10	11/11 (100)	2/11 (18.2)

**Table 5:**  
Correlation of PSA with positive biopsy.

PSA range (ng/ml)	No. of patients	No. of positive / Total No. of Patients (%)	In Regions 1, 3 and 5 only
4 or less 10	40	22/40 (55)	9/22 (40.9)
More than 10	20	15/20 (75)	3/20 (15.0)

## Discussion

The adenocarcinoma of prostate gland is the most common malignancy of genitourinary tract. Incidence of disease rises with increasing age. The various tools like PSA, DRE and TRUS are being used for diagnosis of disease, but the prostatic biopsy remains only the

diagnostic test for detection of prostate cancer.<sup>9</sup>

As more patients are being screened for prostate cancer, the number of patients undergoing prostate biopsies will annually increase. There are concerns about screening of prostate cancer that clinically insignificant cancers will be diagnosed which will not aff-

ect life expectancy.<sup>9</sup>

At the same time several recent studies have shown that prostate cancer is a progressive malignant disease which will affect life expectancy.<sup>9</sup> Albertsen et al reported a decrease in life expectancy of 4 to 8 years in a cohort of men 65 to 75 years old with Gleason scores 5 to 10 a carcinoma when treated with non-curative intent.<sup>10</sup> Several authors have shown that non-palpable stage T<sub>1c</sub> carcinoma of the prostate to be a significant disease. In our study of 60 cases, 37 were diagnosed as case of adeno-carcinoma of prostate. Out of these 37 cases 13 (35.1%) were having stage T<sub>1c</sub> disease. Out of these 13 patients 5(38.5%) cases were having positive biopsy in region 1, 3 and 5, 2 (15.4%) cases positive in region 2 and 4 alone. It was positive in 6 (46.1%) in all 5 regions. So by this technique no of diagnosed carcinoma of prostate cases increased which would have been missed by sextant technique. Stevec et al reported 45.6% false negative result of sextant biopsy for clinically localized disease (beyond 8).<sup>11</sup> Recently Lerner et al showed that 91% of patients with stage T<sub>1c</sub> carcinoma of the prostate had significant tumor grade and volume. They also showed a statistically significant progression – free survival advantage for patients with stage T<sub>1c</sub> disease treated with radical prostatectomy. Clearly, prostate cancer, even at early stages (T<sub>1c</sub>), is a progressive disease and prompt detection of disease at lower stages represents the best chance for survival.

Our results indicate a 32.4% increase in diagnostic yield of prostate biopsy when the 5 region method is used rather than the sextant method. By increasing the no of biopsy cores there was increase in cancer detection both for non-palpable and palpable lesions. The additional cancers found by the 5 region biopsy technique appear to be clinically significant.<sup>12</sup> Rabbani et al reported that 23% false negative result of sextant technique. In our stud there were 24 patients having stage T<sub>2</sub>. Out of these in 7 (29.2%) patients cancer was detected only in region 1, 3 and 5, 1 (4.2%) in sextant region while it was positive in 16 (66.6) patients by 5 region technique. So there is clear edge of extended 5 region biopsy technique even in T<sub>2</sub> group.<sup>13</sup> Svetec et al reported that in clinical localized disease in patients who had undergone radical prostatectomy the false negative result of 45.6% by sextant technique. This difference with our study could be due to ex vivo radical prostatectomy specimen sampling.<sup>14</sup> Eskew et al in his series of 200 patients performed extended prostatic biopsy. Out of these 200 cases, 31 had previously undergone sextant biopsy. At repeat biopsy by extended

technique 39% patients had prostate cancer. The average time between biopsies was less than 1 year (268 days, range 89 to 650 days). These data suggested that some carcinomas existed at the time of prior biopsy but remained undetected due to inadequate sampling.<sup>15</sup> Striker et al used the Bayesian theory to demonstrate that for a fixed percent volume of prostate cancer the probability of finding cancer increases as the number of biopsies increases. Optimal biopsy strategy has supported the use of extended 10 to 14 cores biopsy scheme a new gold standard for prostate biopsy. During the time between false – negative biopsy and repeat positive biopsy, the cancer may progress to a stage at which curative therapy is not possible or is ineffective.<sup>16</sup> Stamey recently stated that there may be some advantage to taking prostate biopsies more laterally than originally described by the sextant method. Since November 1993 he had been obtaining more laterally directed biopsies similar to regions 1 3and 5 of our 5 region technique. It appears that the 5 region biopsy method has its greatest use in patients with a serum PSA of less than 10 ng./ml. In this population 40.9% of cancers were diagnosed with the 5 region technique. These cancers would have been undetected with the sextant method. However, the standard sextant method detected 90% of the patients with cancer and a PSA of greater than 10 ng./ml. Thus, for patients with a PSA of greater than 10 ng./ml. there appear to be diminishing returns to additional biopsy over the standard sextant zones.<sup>17</sup>

There was no cancer in 23 patient who were included in this study. Out these 23 cases 2 cases had chronic pro-statis which settled with antibiotics. Remaining patients had benign disease which were put on follow up with serum PSA value, PSA velocity TRUS and digital rectal examination. Reported consequences of the transrectal ultrasound guided biopsy include haematuria, haematochezia, haemato-spermia and pain. Reported serious complications include prostate abscesses, Pseudomonas urinary tract infections, tumor tracking of the biopsy site and anterior rectal wall hematomas. There were no such complications of biopsy in our series. Of our patients 1% experienced gross haematuria after the biopsy, which was self – limited and no further intervention was required. Of the biopsy cohort 20% stayed in the outpatient observation unit for four hours. We used intravenous sedation to minimize patient discomfort along with intrarectal instillation of 2% lignocaine gel so that we could perform the biopsy. We observed pain and hematuria due to biopsy in middle region of the prostate gland.

## Conclusion

Secondary prevention relies on finding a disease process at the earliest stage possible to prevent associated morbidity and mortality. Finding prostate cancer when it is organ confined decreases cancer related deaths and sufferings. For this reason we introduce in Urology department Lahore General Hospital, Lahore the 5 region technique of prostate biopsy as a means of significantly increasing the diagnostic yield of prostate biopsy in finding carcinoma of the prostate. We have found this technique to be safe, efficacious and superior to sextant biopsies in diagnosing prostate cancer.

## References

1. Nishtar S, Bile KM, Ahmed A, Amjad S, Iqbal A. Integrated population – based surveillance of non-communicable diseases: the Pakistan model. *Am J Prev Med* 2005; 29: 102–6.
2. A. Jemal, R. Siegel, E. Ward et al., “Cancer Statistics 2008,” *CA Cancer Journal For Clinician*, 2008; vol. 58, No. 2: pp. 71-96.
3. Luciani L., Giorgi G., Valoto C. Role of trans-perineal six core prostate biopsy in patients with prostate specific antigen level greater than 10ng/ml and abnormal digital rectal examination findings. *Urology* 2006; 67: 555.
4. Yilmaz S., Eskicorapci C., Guilvey F. Individualization of biopsy protocol according to prostate gland volume for prostate cancer detection. *J Urol* 2005; 173: 1536.
5. Eichler K., Hempel S., Wilby J. Diagnostic value of systematic biopsy methods in the investigation of prostate cancer: a systematic review. *J Urol* 2006; 175: 1605.
6. H. Y. Lee, H. J. Lee, S.-S. Byun, S. E. Lee, S. K. Hong, and S. H. Kim, “Classification of focal prostatic lesions on trans-rectal ultrasound (TRUS) and the accuracy of TRUS to diagnose prostate cancer,” *Korean Journal of Radiology*, 2009; Vol. 10, No. 3: pp. 244–251.
7. C. De Nunzio, A. Trucchi, R. Miano et al., “The number of cores positive for high grade prostatic intraepithelial neoplasia on initial biopsy is associated with prostate cancer on second biopsy,” *Journal of Urology*, 2009; Vol. 181, No. 3: pp. 1069–1075.
8. A. V. Taira, G. S. Merrick, R. W. Galbreath et al., “Performance of trans-perineal template – guided mapping biopsy in detecting prostate cancer in the initial and repeat biopsy setting,” *Prostate Cancer and Prostatic Diseases*, 2010; Vol. 13, No. 1: pp. 71–77.
9. Beyond Diagnosis: Evolving Prostate Biopsy in the Era of Focal Therapy J. L. Dominguez – Escrig, S. R. C. McCracken, and D. Greene. *Prostate Cancer Volume 2011 (2011)*, Article ID 386207, 11 pages doi:10.1155/2011.
10. Albertsen PC, Fryback DG, Storer BE, Kolon TF, Fine J. Long – term survival among men with conservatively treated localized prostate cancer. *JAMA* 1995; 74: 626.
11. Eric P., Maxwell V., Peter R. Impact of increased number of biopsies on the nature of prostate cancer identified. *J Urol* 2006; 176: 1761.
12. Lerner SE, Seay TM, Blute ML, Bergstralh MS, Barrett DM, Zincke H. PSA detected prostate cancer (clinical stage T<sub>1c</sub>): an interim analysis. *J. Urol* 1996; 155: 821.
13. F. Rabbani, N. Stroumbakis, B. R. Kava, M. S. Cookson, and W. R. Fair, “Incidence and clinical significance of false – negative sextant prostate biopsies,” *Journal of Urology*, 1998; Vol. 159, No. 4: pp. 1247–1250.
14. D. Svetec, K. McCabe, S. Peretsman et al., “Prostate re-biopsy is a poor surrogate of treatment efficacy in localized prostate cancer,” *Journal of Urology*, 1998; Vol. 159, No. 5: pp. 1606–1608.
15. Eskew LA, Bare RL, McCullough DL. Patient characteristics and pathological findings in men undergoing repeat biopsies for suspected prostatic carcinoma. Read at annual meeting of Southeastern Section, American Urological Association 1995.
16. Stricker HJ, Ruddock LJ, Wan J, Belville WD. Detection of non-palpable prostate cancer. A mathematical and laboratory model. *Br J Urol* 1993; 71: 43-6.
17. Stamey TA. Making the most of six systematic sextant biopsies. *Urology* 1995; 45: 2.