

# Radiographic Evaluation of Joint Changes in Juvenile Idiopathic Arthritis

Amna Tariq,<sup>1</sup> Saira Rehman,<sup>2</sup> Samia Naz<sup>3</sup>

## Abstract

**Aim:** To evaluate the spectrum of joint changes using radiography as a tool in patients with Juvenile Idiopathic Arthritis at presentation.

**Study Design:** Observational study on prospective data.

**Place and Duration of Study:** Department of Diagnostic Radiology of The Children Hospital and The Institute of Child Health, Lahore, from October 2006 to October 2009.

**Patients and Methods:** 72 patients fulfilling the American college of rheumatology (ACR) criteria of JIA referred from the Rheumatology Clinic were enrolled in the study. Radiographs of both hands PA and knees AP were obtained and interpreted by a single paediatric radiologist. Other views were obtained in individual cases when required clinically. Statistical

analysis of data was done on SPSS version 16.0.

**Results:** Amongst a total of 72 patients, 59 (82%) had polyarthritis, followed by oligoarthritis and systemic onset disease in 12 (17%) and 1(01%) respectively. RA factor was negative in 64 (88.9%). Late joint changes were observed in 20 (27.7%) patients with erosions in 8 (11.1%), boutonniere deformity in 10 (13.9%), swan neck deformity in 07 (7%) and ankylosis in 2 (2.7%) patients. Regarding late changes maximum number of patients, that is 8, were in the age group 12 to 14 years, 14 (70%) were females, 18 (90%) had polyarticular type of JIA and their duration of illness at presentation was mostly between 5 to 8 years. Further evaluating patients with erosions, age range was from 8 to 15 years, 5 (62.5%) were females, 6 (75%) had polyarticular type of JIA and their duration of illness at presentation was mostly between 3 to 5 years.

**Conclusion:** Plain radiography, a readily available diagnostic modality remains the initial investigation in the evaluation of joint changes in children with JIA and its differential diagnosis. Children presenting late are at an increased risk of developing erosions which in particular can be assessed reliably in addition to monitoring of disease progression and detecting complications.

**Key words:** Juvenile Idiopathic Arthritis, JIA, polyarthritis.

---

TARIQ A.<sup>1</sup>

Post-graduate Resident Radiology  
The Children's Hospital and The Institute of Child Health,  
Lahore

Rehman S.<sup>2</sup>

Assistant Professor Radiology  
The Children's Hospital and The Institute of Child Health,  
Lahore

Naz S.<sup>3</sup>

Assistant Professor, Dept. of Paediatric Medicine and  
Rheumatology Clinic, Children's Hospital and The Institute  
of Child Health, Lahore – Pakistan

## Introduction

Childhood arthritis has now been reclassified into a

single internationally recognized entity of Juvenile Idiopathic Arthritis (JIA).<sup>1</sup> It is one of the most common rheumatic diseases of children leading to permanent disability in 10% to 20% of cases.<sup>2,3</sup> It begins under 16 years of age and persists for more than six weeks.<sup>4</sup> Incidence of JIA is approximately 13.9 / 100,000 children per year.<sup>5</sup> The exact etiology of the disease is unknown however infectious, genetic and environmental factors may play a role.<sup>6</sup> Pauci articular disease is the most common form of juvenile idiopathic arthritis with involvement of four or fewer joints.<sup>4</sup>

Three sets of criteria are used to classify JIA. The American College of Radiology (ACR), the European League against Rheumatism (EULAR) and the International League of Associations for Rheumatology (ILAR) criteria.<sup>7,8</sup>

The ACR criteria include age less than 16 years, signs of arthritis in one or more joints, disease duration 6 weeks or longer, onset type defined in first 6 months (polyarthritis when 5 or more joints, oligoarthritis when less than 5 joints are involved, and systemic onset disease) and exclusion of other forms of juvenile arthritis.

The EULAR proposed the term juvenile chronic arthritis (JCA) for the heterogeneous group of disorders that manifest as juvenile arthritis. The diagnosis requires that the arthritis begins before the age of 16 years, that it lasts for at least 6 weeks, and that other diseases are excluded.

The ILAR criteria are currently the preferred classification system. The aim is to provide a unified classification system. The ILAR classification of JIA includes the following features:

(1) Systemic onset (2) Persistent or extended oligoarthritis (3) Rheumatoid factor (RF) – positive polyarthritis (4) RF – negative polyarthritis (5) Psoriasis (6) Enthesitis (7) Others: the disease that does not meet criteria for any of the other subgroups, or it meets more than one criteria.

Juvenile idiopathic arthritis is characterized by synovial pannus formation due to inflammation leading to edema, hypervascularity and cellular hyperplasia. At the time of synovial proliferation juxta articular osteopenia is visualized on radiographs and contrast enhanced MR demonstrates synovial enhancement. Marginal erosions at the synovial articular junction occur due to mechanical and enzymatic destruction of cartilage during pannus invasion. This progresses to soft tissue imbalance and increased bone destruction leading to subluxation.<sup>4</sup>

Radiology has a considerable role in the management of JIA. Plain radiography is the primary tool used to assess and monitor the progression of juvenile idiopathic arthritis, its response to therapy and complications.<sup>10,11</sup> It helps to exclude other childhood disorders.<sup>12</sup> Radiographs are easy to obtain and x-rays of hands and knees provide very useful information.<sup>13,14</sup> The main limitation of conventional radiography is that it does not allow direct examination of the articular cartilage, synovium, and other important non-calcified structures in a joint.<sup>15</sup>

Radiographic signs include soft tissue swelling around the joints with periarticular demineralization. Joint space narrowing and erosions can be seen. Joint sub-luxation leading to deformities like ulnar deviation of fingers can occur along with boutonniere and swan neck deformities. Premature fusion of growth plates resulting in growth disturbances may be a sequelae. Large joints, particularly the knee may show enlarged square shaped epiphyses and widened intercondylar notch. Involvement of the spine, more commonly the upper cervical vertebrae, includes destruction, narrowing and eventual ankylosis of the facet joints. Erosions of the odontoid process of C<sub>2</sub> due to pannus formation resulting in atlantoaxial subluxation are recognized in JIA.

CT scan can help in cases where the anatomy is complex as in the temporomandibular and sacroiliac joints.<sup>10</sup> The major disadvantage of CT scan is that it involves a substantial radiation dose. Magnetic resonance imaging (MRI) and ultrasound are more effective and safer alternatives.<sup>1</sup> Small (and large) joint effusions are readily revealed using ultrasonography.<sup>10</sup> Serial measurements of synovial thickness and effusion volume on ultrasound have been used to monitor the progression of disease. Gadolinium enhanced MRI is the most sensitive modality in early disease to detect synovial hypertrophy and its enhancement, pannus and cartilaginous erosions.<sup>1,16-19</sup> However it is an expensive and time consuming procedure.

Bone scintigraphy can be used to determine the distribution of disease. It has high sensitivity but low specificity and involves high radiation.<sup>15</sup>

## Patients and Methods

72 patients fulfilling the American college of rheumatology (ACR) criteria of JIA, at presentation were enrolled in the study. They were referred from the Rheumatology Clinic over a period of three years from

October 2006 to October 2009. Data collected at first visit included age, gender, type of arthritis, type of joint involvement and associated systemic features. Relevant laboratory data was noted including, hemoglobin (Hb), total leukocyte count (TLC), platelet count (PLT), erythrocyte sedimentation rate (ESR), C-reactive protein (CRP) and presence of rheumatoid factor (RF) and antinuclear antibodies (ANA).

Radiographs of both hands PA and knees AP were obtained in our department using standard protocols and were interpreted by a single paediatric radiologist. Other views were obtained in individual cases when required clinically. Statistical analysis of data was done on SPSS version 16.0.

### Results

A total of 72 patients were enrolled in the study. There were 41 (57%) females and 31(43%) males. Male to female ratio was 1:1.3. The mean age at presentation was 10.82 years. Median age was 11.5 years with youngest patient 03 years and oldest patient 16 years of age. Most of the patients, that is, 40 (55.5%) were in the age group 11 – 16 years.

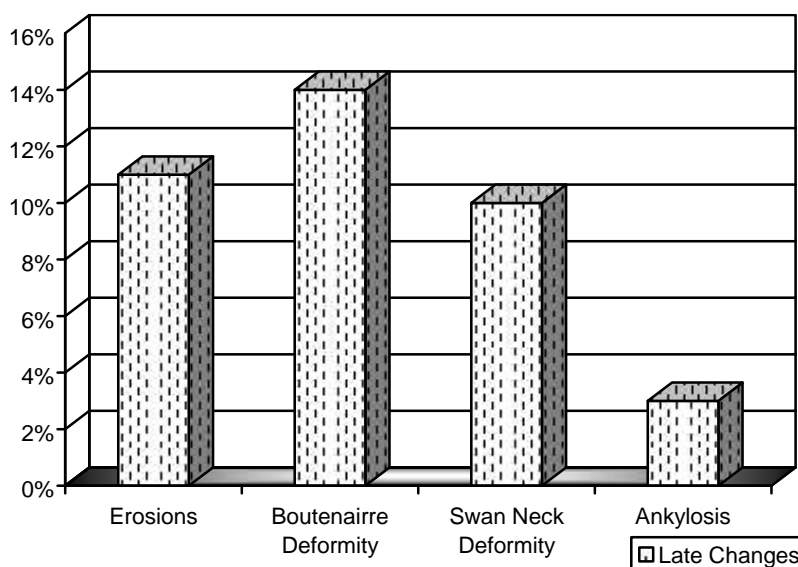
In our study polyarticular was the most common type of JIA seen in 59 (81.9%), oligoarticular in 12 (16.7%) and systemic onset JIA in 01 (1.4%) patients. We observed that RA factor was positive in only 08 (11.1%) and was negative in a majority of 64(88.9%) patients.

Results of this study were divided into two groups on the basis of early and late radiographic changes. Early joint changes were noted in 52 (69.4%) patients with soft tissue swelling in 49 (68.1%), periarticular osteopenia in 54 (75%) and epiphysis were square shaped in 51 (70.8%) patients.

Late changes (Figure 1) were documented in 20 (27.8%) patients with juxta articular erosions in 08, boutonairre deformity in 10, swan neck deformity in 07and ankylosis in 02 patients. Regarding late changes maximum number of patients, that is 8, were in the age group 12 to 14 years, 14 of them (70%) were females, 18 (90%) had polyarticular type of JIA and their duration of illness at presentation was mostly between 5 to 8 years.

In the 08 patients with erosions age range was 8 to 15 years, amongst which 05 (62.5%) were females, 06 (75%) had polyarticular type of JIA and their duration of illness at presentation was mostly between 03 to 05 years (Table 1).

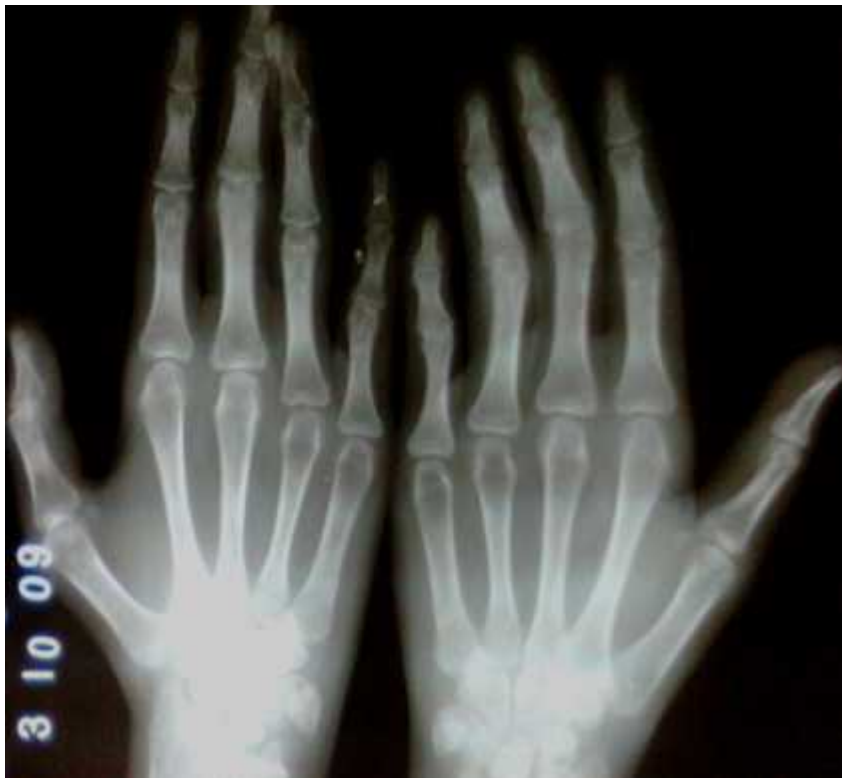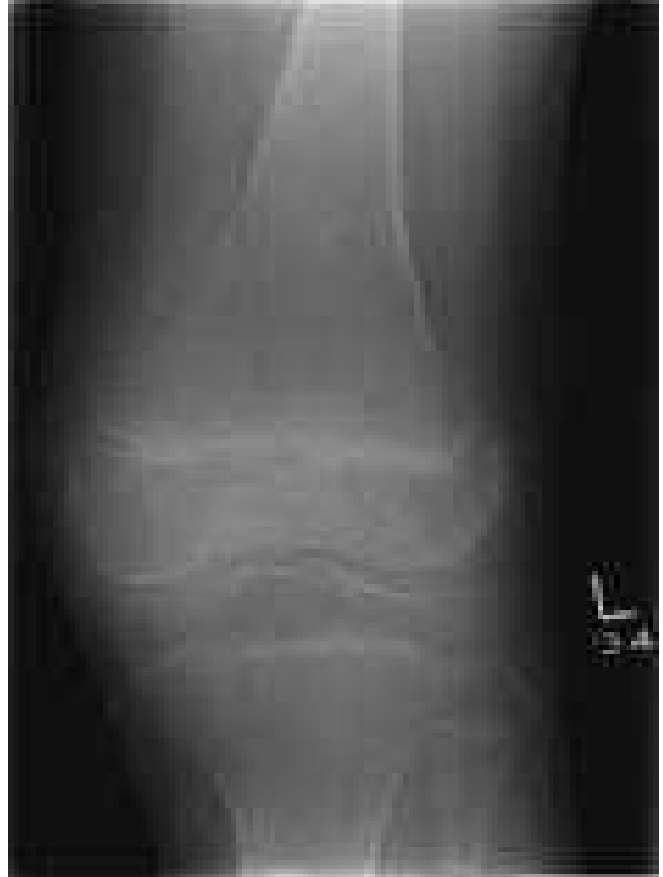**Figure 1:** Late Changes.



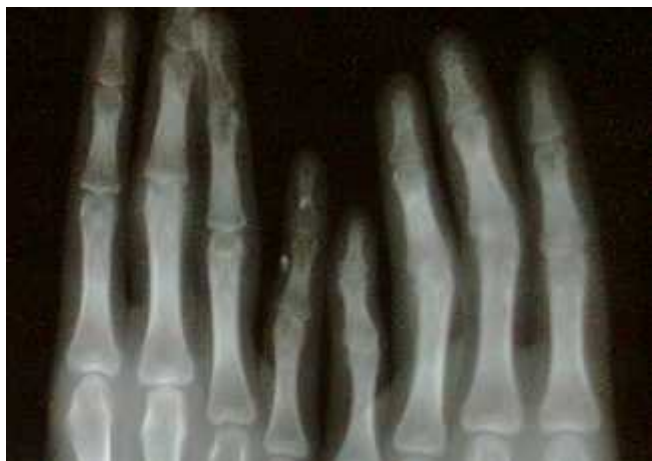**Table 1:** Erosions.

Age Range	Gender	Duration of Illness	RA Factor Positive	Type of JIA
08 to 15 years	62.5% females	03 to 05 years	25%	75% polyarticular

**Fig. 1:** Frontal radiograph left knee joint of a 14 years old female demonstrates juxta articular osteopenia with large square shaped epiphysis of distal femur and widened inter condylar notch. Joint space is reduced.



**Fig 2:** Frontal radiograph both hands demonstrates periarticular osteopenia with soft tissue swelling and reduced joint spaces along the proximal interphalangeal joints. Swan neck deformity is present at the 4<sup>th</sup> finger of right hand and boutonniere deformity at 5<sup>th</sup> finger of right hand and 3<sup>rd</sup>, 4<sup>th</sup> and 5<sup>th</sup> fingers of left hand.



**Fig. 3:** A closer view of figure 2.

## Discussion

JIA is one of the most common inflammatory diseases of childhood.<sup>20</sup> Disability and morbidity is the most dreaded in arthritis. Radiology has a key role in the diagnosis, management and follow-up of JIA. Radiographs remain the mainstay of diagnostic imaging in JIA, although their sensitivity in detecting early soft tissue involvement and erosions is limited, they are far easier to obtain and readily available as compared to other imaging modalities.<sup>21</sup> X-rays are useful in excluding other causes of joint swelling like Rickets, leukaemia, infection, Haemophilia and neuropathic joints as seen in our centre.

To the author's knowledge, the present study was the first in the country to describe the radiographic changes documented in children newly diagnosed as JIA.

Polyarticular was the most common type of JIA in our study which is not in accordance with the western literature that states pauciarticular disease as the most common type.<sup>4,22-24</sup> However in this respect our results were similar to a study done in India.<sup>25</sup> This indicates that polyarticular is the predominant type of JIA in the subcontinent. The explanation to this is the difference in genetic background of the population under study.

In the present study gender indicates the higher prevalence of females which was similar to other studies.<sup>26,27</sup> Predominance of male gender was present in different studies conducted in India.<sup>25</sup>

Late changes at presentation were documented in patients who presented with a longer duration of illness, mostly after 05 to 08 years which is consistent with the Indian study.<sup>25</sup> These were predominantly

seen in female patients belonging to the age group 12 to 14 years with polyarticular JIA being the most common type. This signifies the need for early recognition and prompt management of the disease in order to avoid complications. Patients should be educated and encouraged to seek medical help early which lacks in our society.

In our study erosions mostly involved the carpus, metacarpophalangeal and proximal interphalangeal joints which was also seen in a European study.<sup>24</sup> Data of patients with joint erosions was further analyzed and it was documented that females of an older age group presenting late with polyarticular and seronegative JIA were at an increased risk of developing juxta articular erosions during the course of their illness.<sup>24</sup> Radiographic evidence of erosions in a majority is visible after 20 months of disease. Early erosive changes within the first six months indicate aggressive disease and a poor prognosis.<sup>28</sup> We must admit the limitations of our study as erosions are detected early on ultrasound and MRI, however radiography is easily accessible and helpful in differential diagnosis at presentation.

All patients were managed in the Rheumatology Clinic with non-steroidal anti-inflammatory drugs (NSAIDs). Disease modifying agents (methotrexate) and steroids were used in patients where required.

This study provides the baseline of joint changes in JIA in our setting and further studies may be based on this data to assess the progression of joint erosions in patients on management.

## Conclusion

Radiography is a readily available, inexpensive diagnostic modality that remains the initial investigation in the evaluation of joint changes in children with JIA. Radiographs of hands and knees provide very useful information and erosions can be assessed reliably. Radiographs allow grouping of various arthritides on the basis of distribution and pattern of joint space changes with monitoring of disease progression and detecting complications.

## References

1. Johnson K, Gardner – Medwin J. Childhood arthritis: Classification and radiology. *Clin Radiol.* Jan 2002; 57 (1): 47-58.
2. Lang BA, Schneider R, Reilly BJ, Silverman ED, Laxer

- RM. Radiologic features of systemic onset juvenile rheumatoid arthritis. *J Rheumatol*. 1995; 22: 168-173.
3. Berquist T H. MRI of musculoskeletal system. 4<sup>th</sup> ed. p.1046.
  4. Slovis TL. Caffey's paediatric diagnostic imaging. Elsevier. 10<sup>th</sup> ed. p. 2460.
  5. Kliegman RM. Nelson text book of paediatrics. 16<sup>th</sup> ed. p.704.
  6. Ringold S, Burke A, et al. Juvenile idiopathic arthritis. *JAMA*. 2005; 294 (13): 1722.
  7. Lamer S, Sebag GH. MRI and ultrasound in children with juvenile chronic arthritis. *Eur J Radiol* 2000; 33 (2): 85-93.
  8. Argyropoulou MI, Margariti PN, Karali A, Astrakas L, Alfandaki S, Kosta P, et al. Temporomandibular joint involvement in juvenile idiopathic arthritis: clinical predictors of magnetic resonance imaging signs. *Eur Radiol*. Mar 2009; 19 (3): 693-700.
  9. Lee EY, Sundel RP, Kim S, Zurakowski D, Kleinman PK. MRI findings of juvenile psoriatic arthritis. *Skeletal Radiol*. Nov 2008; 37 (11): 987-96.
  10. Azouz EM. Arthritis in Children: conventional and advanced imaging. *Semin Musculoskeletal Radiol*. 2003 Jun; 7 (2): 95-102.
  11. Van Rossum MAJ, Zwinderman AH, Boers M, Dijkmans BAC, van Soesbergen RM, Fiselier TJW, et al. Radiologic features of juvenile idiopathic arthritis. *Arthritis Rheum* 2003; 48: 507-15.
  12. Wihlborg C, Babyn P, Ranson M, Laxer R. Radiologic mimics of Juvenile rheumatoid arthritis. *Pediatric Radiology*, 2001; Vol. 31 (5): 315-326.
  13. Van der Heijde DM, Boers M. The value of roentgen pictures in rheumatoid arthritis. *Ned Tijdschr Geneesk*. 1997 Sep 6; 41 (36): 1725-30.
  14. Devauchelle – Pensec V, Saraux A, Alapetite S, Colin D, Le Goff P. Diagnostic value of radiographs of the hands and feet in early rheumatoid arthritis. *Joint Bone Spine*, 2002 Oct; 69 (5): 434-441.
  15. Hekmatnia A, Chew FS. Imaging in Juvenile Rheumatoid Arthritis. *Medscape*.
  16. McHugh K, Gupta R, Murray K. Imaging in juvenile chronic arthritis. *Imaging*. 1999; 11: 91-97.
  17. Pedersen TK, K uselers A, Gelineck J, Herlin T. A prospective study of magnetic resonance and radiographic imaging in relation to symptoms and clinical findings of the temporomandibular joint in children with juvenile idiopathic arthritis. *J Rheumatol*. Aug 2008; 35 (8): 1668-75.
  18. Nistala K, Babar J, Johnson K, Campbell – Stokes P, Foster K, Ryder C, et al. Clinical assessment and core outcome variables are poor predictors of hip arthritis diagnosed by MRI in juvenile idiopathic arthritis. *Rheumatology (Oxford)*. Apr 2007; 46 (4): 699-702.
  19. Shanmugavel C, Sodhi KS, Sandhu MS, Sidhu R, Singh S, Katariya S, et al. Role of power Doppler sonography in evaluation of therapeutic response of the knee in juvenile rheumatoid arthritis. *Rheumatol Int*. Apr 2008; 28 (6): 573-8.
  20. Yanagimachi M, Miyamae T, Naruto T, Hara T, Kikuchi M, Hara R, et al. Association of HLA – A (\*) 02: 06 and HLA – DRB1 (\*) 04: 05 with clinical subtypes of juvenile idiopathic arthritis. *J Hum Genet*. Mar 2011; 56 (3): 196-9.
  21. Doria AS, Kiss MH, Lotito AP, Molnar LJ, de Castro CC, Medeiros CC, Cerri GG. Juvenile rheumatoid arthritis of the knee: evaluation with contrast – enhanced color Doppler ultrasound. *Pediatr Radiol* 2001; 31 (7): 524-531.
  22. Oen KG, Cheang M. Epidemiology of chronic arthritis in childhood. *Semin Arthritis Rheum* 1996; 26: 575-591.
  23. Andersson – Gare B. Juvenile Arthritis — who gets it, where and when. A review of current data on incidence and prevalence. *Clin Exp Rheumatol* 1999; 17: 367-374.
  24. Manners PJ, Bower C. Worldwide prevalence of juvenile arthritis—why does it vary so much? *J Rheumatol* 2002; 29: 1520-30.
  25. Aggarwal A Aggarwal V et al. Outcome in Juvenile Rheumatoid Arthritis in India. *Indian Pediatrics* 2004; 41: 180-184.
  26. Mason T, Reed A M, Nelson A M, Thomas K B. Radiographic progression in children with polyarticular juvenile rheumatoid arthritis: a pilot study *Ann Rheum Dis* 2005; 64: 491-493.
  27. Williams RA, Ansell BM. Radiological findings in sero-positive juvenile chronic arthritis (juvenile rheumatoid arthritis) with particular reference to progression. *Annals of the Rheumatic Diseases* 1984; 44: 685-693.
  28. Spencer S.P, Ganeshalingam S, Kelly S, Ahmad M. The role of ultrasound in the diagnosis and follow-up of early inflammatory arthritis. *Clinical Radiology* 2012; 67: 15-23.