

Presentation and Management of Extra Hepatic Bile Duct Injuries

M AYYAZ M A CHEEMA M W FAROOKA

Department of Surgery, King Edward Medical College/Mayo Hospital, Lahore
Correspondence to Dr. Mahmood Ayyaz, Associate Professor Surgery

Objective: To present the experience of presentation and management of extrahepatic bile duct injuries at a tertiary care unit of a teaching hospital. **Design:** A descriptive & observational case study. **Place and Duration of Study:** South Surgical Unit, Mayo Hospital, Lahore from June 1999 to 2004. **Subjects and Methods:** A total number of 15 patients 6 male and 9 female, with history of cholecystectomies presenting with biliary peritonitis or obstructive jaundice were included in the study. Their nodes of presentation and the operative management with outcomes were noted. **Results:** These were 6 male and 9 female patients with CBD injuries, the age ranged between 12 & 55 years. Six of them had laparoscopic cholecystectomies while nine had open procedures. Majority of them were referrals, mode of presentation was jaundice in 7 cases while 8 of them presented with jaundice, sepsis and peritonitis. Nine had Roux-en-Y hepaticojejunostomy, one loop HJ, 2 T-tube repairs, a cholecystojejunostomy and an ERCP stenting was done. One patient expired before any procedure could be done and another expired post operatively, rest of them showed delayed but good recovery. **Conclusion:** Damage to CBD is a serious complication. It is best avoided by adequate training, good exposure and knowledgeable dissection, difficult anatomy and unexpected bleeding are the most common aetiological factors. The gold standard for treatment is early intervention and a Roux-en-Y Hepaticojejunostomy and an early referral to centres where expertise is available as successive attempts by less experienced surgeons result in diminished returns.

Key words: Bile duct injuries (BDI), Common bile duct (CBD), Hepaticojejunostomy (HJ)

Bile duct injuries (BDI) occur both during open and laparoscopic cholecystectomy. Incidence of BDI for our country is unknown. Western figures are quoted as around 0.3% for open cholecystectomy and 0.74% for laparoscopic cholecystectomy. Exact mechanisms of these injuries is not known. Some of theories of causation are reported to be mistaken/variable anatomy or unexpected bleeding resulting in blunt clamping or excessive use of electrocautery. BDI is a devastating complication when a relatively benign disease is converted into a potentially malignant course which may result in long life disability/liver failure from secondary biliary cirrhosis and death.

Objective of this study is to report our experience with diagnosis and management of BDI following cholecystectomy referred to a tertiary care hospital.

Patients and methods:

This is a prospective observational study of all patients admitted to South Surgical Unit, Mayo Hospital, Lahore with a diagnosis of BDI over the period from June 1999 to December 2002. Data was collected about gender, age, type of original operation, source of patient referral, mode of presentation, investigations. Type of management, complications and outcome were also noted.

Results:

A diagnosis of BDI was made in a total 15 patients over the study period. There were 6 males and 9 females with median age of 45 years (range 22-58 years). Five of them had laparoscopic cholecystectomy (LC) while 4 had open cholecystectomy (OC) Six patients were referred from district headquarter or equivalent hospitals were 2 came from tehsil headquarter or equivalent hospital. One

injury occurred inside the surgical unit from a clip wrongly applied to the side of bile duct during LC. Although clip was removed during operation, it led to bile leak post operatively.

Five patients presented with obstructive jaundice, while 4 presented with biliary leak. This leak was generalized in 2 patients producing picture of biliary peritonitis and other 2 presented with localized leak showing up as biliary fistula. PTC was our investigation of choice. It was done in 5 patients (Fig.1). ERCP was done in 4 patients (Fig.2). One patient had a cholangiogram done through the drainage tube placed during original operation.

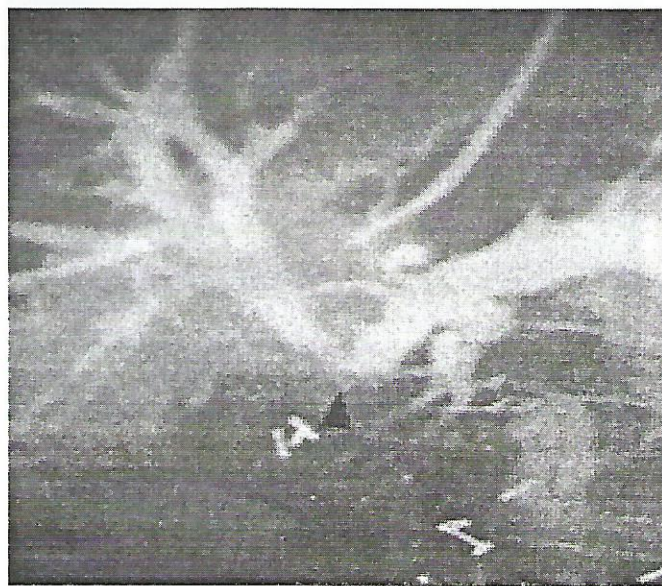

Fig. 1

Seven patients had Roux-en-Y hepaticojejunostomy (Fig.3), one had U-loop hepaticojejunostomy and one had simple suture with resolution of jaundice in all 9 patients. There was not mortality. These patients have been followed up for a period ranging from 5 to 46 months. During the follow up, three patients have presented with complications of recurrent cholangitis which have all settled with conservative management.

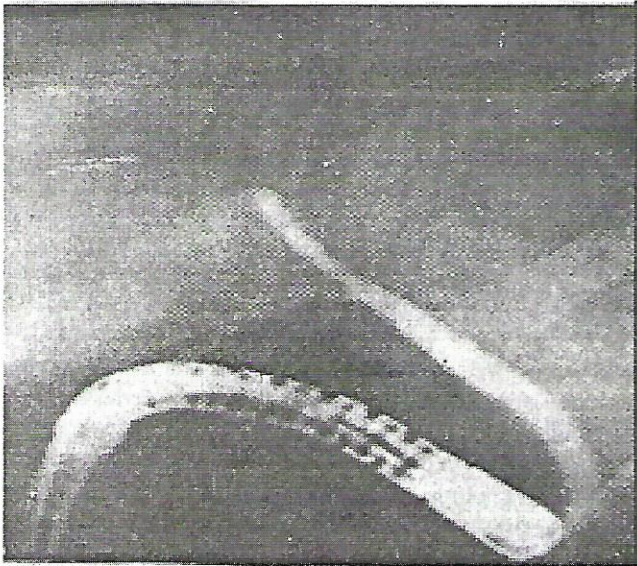


Fig. 2

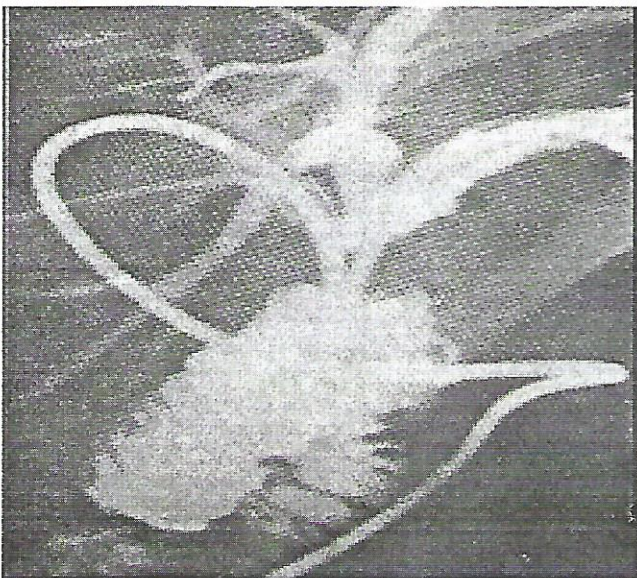


Fig. 3

Discussion:

Advent of LC has led to increase in BDI world over. The incidence of biliary lesions following laparoscopic cholecystectomy is up to threefold higher than that of the open procedure. This is frequently ascribed to a "learning

curve". Although incidence of BDI decreases with increasing experience, in one study about 1/3rd of injuries occurred after surgeons had each performed more than 200ic. Nonetheless need for laparoscopy skills training as a part of structured training programs is obvious. Both private and public hospitals should have rules for allowing LC privileges to surgeons upon evidence appropriate training. Possibility of a surgeon in this country starting LC without proper training amounts to "qualified quackery".

One mechanism for injury appears to be unexpected bleeding leading to panic situation and resulting in blind clamping or excessive use of electrocautery. All bleeding should initially be handled by pressure with swab both during open as well as LC. Careful and safe dissection of Calot's triangle should be the rule. Although difficult to prove, one reason for unexpected bleeding appears to be injury to a "caterpillar hump" of right hepatic artery which is accompanied by a very short cystic artery. This "caterpillar hump" is not rare as noted by authors. Conversion to open operation should be thought of as an adaptation of operative strategy and not counted as a complication.

For OC, good OR lighting and access through an adequate incision are essential. Tendency to make smaller and smaller incisions by trainee surgeons should be curbed.

Roux-en-Y hepaticojejunostomy works well as a conduit for established cases of BDI. Although injuries recognized during operation can be repaired by direct suture over t-tube if feasible, in one series 20 to 21 repairs had to be converted to Roux loop.

Conclusion:

- Damage to CBD is a serious complication, occurring both after open & laparoscopic cholecystectomy. It is best avoided by adequate training, good access and safe dissection avoiding blind clamping if unexpected bleeding occurs. Damaged CBD is best repaired by drainage into Roux-en-Y jejunal loops which works well as a conduit.
- Bile duct injury results from imprecise dissection and no inadequate demonstration of anatomy. The main contributing factors are the lack of recognized training, difficult anatomy (due to congenital anomalies or severe inflammation) and unexpected bleeding.
- Operative cholangiographics, though should be done are not easily available options and in anyway are not a substitute for careful dissections.
- Routine abdominal drainage may allow early detection of bile leak and avoids morbidity associated with biliary peritonitis.
- Late interventions or simple drain placements may result in fatal outcome.

- Repeated surgical interventions meet with a diminished return and should be referred at centers of expertise.
- A single well planned attempt by a skillful surgeon can be successful. Therefore injuries and complications should be dealt only by surgeons who are specifically doing this kind of surgery.

References:

1. Archer SB, Brown DW, Smith DC, Hunter JG. Bile duct injury during laparoscopic cholecystectomy: results of a national survey. *Ann Surg* 2001; 234(4):549-58.
2. Perissat J. Laparoscopic cholecystectomy: the European experience. *Am J Surg* 1993; 165(4):444-9.
3. Kune GA. Bile duct injury during cholecystectomy: causes, prevention and surgical repair in 1979. *Aust N Z J Surg* 1979; 49(1): 35-40.
4. Richardson MC, Bell G, Fullarton GM. Incidence and nature of bile duct injuries following laparoscopic cholecystectomy: an audit of 5913 cases. West of Scotland Laparoscopic Cholecystectomy Audit Group *Br J Surg* 1996; 83(10): 1356-60.
5. Neuhaus P, Schmidt SC, Hintze RE et al. Classification and treatment of bile duct injuries after laparoscopic cholecystectomy. *Chirurg* 2000; 71(2): 166-73.
6. Rossi RL, Schirmer WJ, Braasch JW, Sanders LB. Laparoscopic bile duct injuries. Risk factors, recognition, and repair. *Arch Surg* 1992; 127(5): 596-601.
7. Torkington J, Pereira J, Chalmers RT, Horner J. laparoscopic cholecystectomy, bile duct injury and the British and Irish surgeon. *Ann R Coll Surg Engl* 1998; 80(2): 119-21.
8. Schol FP, GO PM, Gouma DJ. Risk factors for bile duct injury in laparoscopic cholecystectomy: analysis of 49 cases. *Br J Surg* 1994; 81(12): 1786-8.
9. Gouma DJ, Go PM. Bile duct injury during laparoscopic and conventional cholecystectomy. *J Am Coll Surg* 1994; 178(3): 229-33.
10. Moossa AR, Mayer AD, Stabile B. Iatrogenic injury to the bile duct. Who, how, where? *Arch Surg* 1990; 125(8): 1028-30.
11. Inui H, Kown AH, Kamiyama Y. Managing bile duct injury surgery and after laparoscopic cholecystectomy. *J Hepatobiliary Pancreat Surg* 1998;5(4): 445-9.
12. Horvath KD. Strategies for the prevention of laparoscopic common bile duct injuries. *Surg Endosc* 1993; 7(5): 439-44.
13. MacFadyen BV Jr, Vecchio R, Ricardo AE, Mathis CR. Bile duct injury after laparoscopic cholecystectomy. The United States experience. *Surg Endosc* 1998; 12(4): 315-21.
14. Strasberg SM. Avoidance of biliary injury during laparoscopic cholecystectomy. *J Hepatobiliary Pancreat Surg* 2002;9(5): 543-7.
15. Asbun HJ, Rossi RL, Lowel JA, Munson JL. Bile duct injury during laparoscopic cholecystectomy: mechanism of injury, prevention and management. *World J Surg* 1993; 17(4): 547-51.
16. Roy AF, Passi RB, Lapointe RW. Bile duct injury during laparoscopic cholecystectomy. *Can J Surg* 1993; 36(5): 509-16.
17. Adamsen S, Hansen OH, Funch-Jensen P, Schultz S. Bile duct injury during laparoscopic cholecystectomy: a prospective nationwide series. *J Am Coll Surg* 1997;184(6): 571-8