

## Perspectives

### The outcome of Hang-Back Sutures Technique in Horizontal Strabismus Surgery

Umair Tariq Mirza<sup>1</sup>, Zahid Kamal Siddiqui<sup>2</sup>

<sup>1</sup>Assistant Professor of Ophthalmology, Mohi-ud-Din Islamic Medical College, Mirpur AJ&K; <sup>2</sup>Principal, Sahiwal Medical College, Sahiwal.

#### Abstract

##### Objective

The objective of the current study was to assess outcome of hang back sutures in horizontal strabismus with the reference to specific type of surgery known as postoperative alignment.

Study Design: Retrospective Observational type.

**Place and Duration of study:** Conducted in Lahore General Hospital and Mayo Hospital, Lahore from June 2006 to Feb 2018.

##### Methods

Patients with horizontal strabismus were recruited. Clinical assessment included cycloplegic refraction, best corrected visual acuity and routine assessment for squint. Those having coexisting ocular or neurological problems, previously squint surgery, A/V pattern or vertical deviation were excluded. All underwent recession by hang-back method using absorbable suture. Preoperative and postoperative deviation was measured in terms of degree on 1<sup>st</sup> day, 3<sup>rd</sup> month and at 6<sup>th</sup> month.

##### Results

Out of 64 patients, 66% were females while 34% were males with mean age of 14.22 years (SD 7.88). Amongst them 62 % had surgery for exotropia and 38 % for esotropia. All underwent unilateral (86%) and bilateral (14%) recession/resection procedure. Range of preoperative deviation was between 10 - 45 degrees (20-90PD) with mean of 20.86 degrees (SD 8.6) and postoperatively improved to 0-15 degree (0-30PD) with mean 1.91 degree (SD 3.77). 78% cases were straight or deviation less than or equal to 5 degree (10PD) on 1<sup>st</sup> postoperative day, at 3<sup>rd</sup> month as well as at 6<sup>th</sup> month. Out of 64 patients, 3% required readjustment of sutures and 3% needed revision surgery on the other eye.

##### Conclusion

We conclude that hang-back technique is simple and safe method for rectus muscle recession.

**Corresponding Author** | Dr. Umair Tariq Mirza; Assistant Professor of Ophthalmology, Mohi-ud-Din Islamic Medical College, Mirpur AJ&K, **Email:** utmirza@gmail.com

**Key words:** Strabismus, Horizontal, Esotropia, Exotropia, Ophthalmologist

#### Introduction

The goal of strabismus surgery is the correction of misalignment of the eyes. In the conventional procedure of recession, muscle is moved backwards

several millimeters from the original insertion and sutured to the sclera. This method however, can result in different complications; such as scleral perforation, longer procedure duration and difficult exposure at the site of sclera sutures. To avoid these probl-

ems, an alternative method of recession is used, which is termed as hang-back technique where rectus muscle is hanged from the original insertion. Better exposure and relative thickness of the original insertion site makes this technique safer with a shorter learning curve. Hang-back method was firstly tested for esotropia repair adjustable sutures technique only<sup>1</sup>, but later it was also examined for vertical deviation repair<sup>2,3</sup> as well as for exotropia.<sup>4,5</sup> Repka & Guyton<sup>6</sup> shared their particular experience of hang back technique for children having esotropia. Successful eye alignment, which followed the surgery is linked with psychosocial benefit<sup>7</sup> and improved cosmesis.<sup>8</sup> As previous studies had shown better safety and outcome with hang-back suture technique, we aimed to assess complications and post operative alignment in horizontal strabismus in our population.

## Methods

The case notes of the eligible patients were reviewed from 2006 to 2018. The records of 64 operations were available for analysis. Clinical assessment of the patients such as preoperative complete assessment for strabismus was done by performing cover tests, ocular motility, anterior and posterior segment examination. Squint is classified into Esotropia and Exotropia. Esotropia is a form of strabismus in which one or both of the eyes turn inward and in Exotropia one or both of the eyes are turned outward. The exotropia patients were of three types; infantile, intermittent and sensory. Esotropia patients were classified as infantile, non-accommodative, accommodative and sensory. Remaining all types of squint (post surgical and neurological/paralytic) were excluded from the study. The cycloplegic refraction was done using cyclopentolate 1%, trial of spectacle correction was given to achieve best corrected visual acuity. In addition, four patients also needed amblyopia therapy prior to surgery.

## Exclusion Criteria:

Following were excluded from the study:

1. Coexisting ocular or neurological morbidity,
2. Previous squint surgery,
3. Associated pattern or vertical deviation

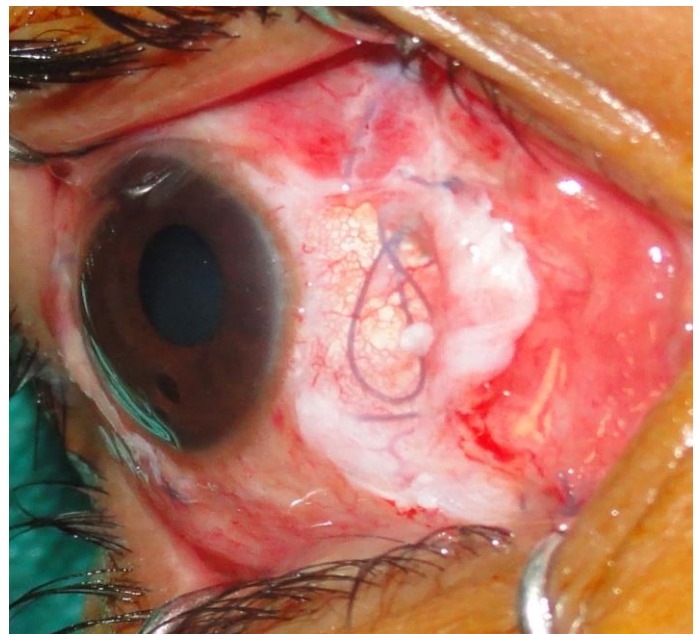
The estimation formula regarding length of recession/resection for patients were as follows.

1 mm recession/resection of Medial Rectus = 2- degree

**1 mm recession /resection of Lateral Rectus = 1-degree**

Conjunctival peritomy was done 1mm posterior to the limbus preserving limbal stem cells. Traditional technique of resection method was adopted, where muscle was isolated, measurement on the muscle was marked with bipolar cautery. Later 6/0 Vicryl W9552 (Polyglactin 910 on spatula needle) was used to pass the suture on top and bottom border of the muscle taking at least 1mm muscle mass in it. The muscle mass anterior to suture was removed using Westcott's scissors, taking caution to leave 0.5mm stump at insertion.

For rectus muscle recession Hang back technique was used, in which first muscle was secured with 6.0 Vicryl absorbable suture, by using type of whip knot (0.5mm from insertion) and then it was dis-inserted from its original site. At both end of suture/stitch, partial thickness scleral bites were taken just anterior to the insertion site and after measurement, knot was tied. (*Fig. 1*).



**Figure 1:** Bowknot of the hang-back suture

The patient was examined within 24 hours depending on the convenience of the family. In case of over or under correction the patient was taken again back to Operation theatre and muscle was re-adjusted under topical or general anaesthesia according to patient's age. During this process the bowknot was opened. In the case of under-recession the muscle was moved towards its origin, the knot reapplied and patient was reassessed till desired results were achieved. On the other hand, in case of under-recession of the rectus, the knot was opened, the muscle was advanced towards its insertion till the desired position was achieved. Conjunctival wound was closed with 7/0 polyglactin 910. Postoperatively the patient was given injectable antibiotics (Ceftriaxone) and oral analgesics (paracetamol) for first 5 days. Topical combination of antibiotic (Tobramycin) & steroid (dexamethasone) were given in drops & ointment form, initially 5 times per day in 1<sup>st</sup> post operative week then 3 times in the 2<sup>nd</sup> week. Those conjunctival sutures that did not absorb were removed in 1 week time.

Patients in the current study were evaluated on a criterion based on three time points such as surgery after 1<sup>st</sup> day, at 3<sup>rd</sup> month as well as at 6<sup>th</sup> month too. At three time points, procedural tests such as Visual Acuity, Slit lamp examination and measurement of deviation using cover tests were also done. The main outcome of the study was characterized as cosmetically acceptable result or residual squint up to 5° (10PD).

## Results

The break up of main types of horizontal strabismus were; Exotropia (62%) and esotropia (38%). The degree of strabismus ranged 15°-40°(30-80PD). The exotropia patients were of three types; infantile 15.5%, intermittent 13.5% and sensory 33%. On the other hand, esotropia patients were classified as infantile 3%, non-accommodative 3%, accommodative 17% and sensory 15% (Table 1). The majority of patients had unilateral (86%), whereas few had bilateral (14%) procedure.

**Table 1:** Break-up of categories of strabismus (n = 64)

PERCENTAGE OF VARIOUS SQUINTS			
EXOTROPIA (62%)		ESOTROPIA (38%)	
Infantile	15.5	Infantile	3
Intermittant	13.5	Non-accommodative	3
Sensory	33	Accommodative.	17
		Sensory	15

Analysis of gender showed that there were 66% females, males were only 34% in the sample and their ages varied from 2 to 25 years with mean age 14.22 (SD +/-7.88) as shown in Table 2.

**Table 2:** Demographic data (n = 64)

Demographic data		Percentages
<b>Gender</b>	Male	34%
	Female	66%
<b>Age</b>	02-25 years	14.22 (+/-7.88)

In the group pre-operative deviation ranged between 10 - 45 degrees with mean of 20.86 (SD +/- 8.6). In 87% patients, near and distance deviation was equal whereas 45% cases of preoperative deviation ranged between 15-30 degrees. Table 3 demonstrates degree of the deviations.

**Table 3:** Percentage of preoperative deviation in various types of Strabismus deviations

Strabismus	<15 Degree	15 Degree	15 – 30 Degree	>30 degree
Esotropia	4	56	36	4
Exotropia	5	35	52	8

There were 37% patients who had recession of the medial rectus, while 63% cases had recession of lateral rectus muscle. After the operation, good cosmetic appearance was achieved in 78% patients with a range of 0-5 degrees with a mean of 1.91 degree (SD +/-3.77). The patients with residual deviation of 5-10 degrees were 19%. Only 3% patients had deviation ranged between 10-15 degrees. Refraction, amblyopia therapy and convergence exercises resulted in improvement in 50% cases for post operation deviation with < 10 degrees. After the procedures the de-

viations in various forms of strabismus are demonstrated in the following table (Table 4).

**Table 4:** Percentage of postoperative deviation in various type of strabismus

Strabismus	Straight or less < 5°	5–10°	10–15°	Overcorrection
Esotropia	88%	12%	0%	0%
Exotropia	74%	21%	2%	3%

The complications encountered were; loose conjunctival suture (3%), subconjunctival hemorrhage (3%), dellen (1%), corneal epithelial erosion (1.6%).

Only 3% patients needed sutures readjustment to improve the outcome. 1.5% patients who developed diplopia after the operation had exotropia before the operation and later on they developed consecutive esotropia. These cases were managed with the use of hang-back knots to advance the muscle to a point where the appearance was acceptable and diplopia resolved. The loose conjunctival sutures were removed, whereas exposed part of adjustable sutures' was trimmed.

## Discussion

Our study analyzed the results of hang-back recession in terms of horizontal muscle surgery and found it successful for the patients having esotropes or exotropes. The patients (97%) had good cosmetic appearance at follow up visits; after 1st day, 1 month, and at 6<sup>th</sup> month.

Hang-back technique is the method that allows rectus recession with reduced risk of scleral perforation by needle passing through the sclera<sup>5,9,10,11</sup>. None of our cases had scleral perforation. Researchers in previous studies also showed safety and effectiveness of this technique compared to conventional recession surgery.<sup>11</sup> Moreover it gives the opportunity for adjusting the muscle after strabismus surgery<sup>14</sup>. However, in our study only 3% cases needed readjustment.

Its other advantages are easier surgical exposure<sup>5,11</sup> shorter duration of surgery<sup>11,12</sup> and decreased amounts of induced astigmatism following the operation<sup>13</sup>.

Comparison of hang-back technique with conventional recession surgery for horizontal strabismus also showed improvement in esotropia deviation from 31+/-9 to 7+/-6 PD (prism diopter) for hang-back recession whereas in exotropia, deviation improved from 28.9+/-9 to 0.5+/-11PD. It is specially effective for children having smaller globes, patients of myopia or collagen vascular diseases.<sup>11</sup> The long term results of hang back technique in 189 patients who went through unilateral or bilateral medial rectus recession improved on average deviation from 48 PD to 1.1 PD in the 1st group while in the 2<sup>nd</sup> group improvement was between 29PD to 1.1 PD.<sup>15</sup> Breckenridge reported a modified hang back surgery technique that resulted in minimizing need for repeating surgery.<sup>16</sup> Especially for medial rectus reinserting posteriorly is a difficult task.<sup>17</sup>

Not much work has been evident in our population regarding outcome of Hang-back suture technique in strabismus surgery. Limitations of our study was that it was performed on small number of cases, in limited centers and no comparative analysis was done with conventional recession technique. There is a need to further analyze outcome in a larger scale and involving more centers, which will yield satisfactory outcome. Also in future this technique should be assessed on vertical muscles, comparison should be done with adjustable suture technique and conventional rectus muscle recession techniques.

## Conclusions:

It may be concluded that hang-back technique is a suitable procedure for horizontal strabismus with better exposure during surgery, lower risk of scleral perforation and effective method especially in terms of post operative alignment.

## Conflict of interest

Authors declared no conflict of interest.

## References

1. Jampolsky A. Current techniques of adjustable strabismus surgery. Am J Ophthalmol. 1979 Sep 1; 88(3):406-18.

2. Scott WE, Sutton VJ, Thalacker JA. Superior rectus recessions for dissociated vertical deviation. *Ophthalmology*. 1982 Apr 1;89(4):317-22.
3. Mallette RA, Repka MX, Guyton DL. Superior rectus suspension recession for dissociated vertical deviation: a report of 59 operations. *Binocular Vis*. 1987 ;2:209-15.
4. Capó H, Repka MX, Guyton DL. Hang-back lateral rectus recessions for exotropia. *J Pediatr Ophthalmol Strabismus*. 1989 Jan 1;26:31-4.
5. Orlin A, Mills M, Ying GS, Liu C. A comparison of hangback with conventional recession surgery for exotropia. *J AA-POS*. 2007 Dec 1;11(6):597-600.
6. Repka MX, Guyton DL. Comparison of hang-back medial rectus recession with conventional recession. *Ophthalmology*. 1988 Jun 1;95(6):782-7.
7. Mruthyunjaya P, Simon JW, Pickering JD, Lininger LL. Subjective and objective outcomes of strabismus surgery in children. *J Pediatr Ophthalmol Strabismus*. 1996 May 1;33(3):167-70.
8. Willshaw HE, Keenan J. Strabismus surgery in children: the prospects for binocular single vision. *Eye*. 1991 May;5(3):338.
9. Hemmerdinger C, Rowe N, Baker L, Lloyd IC. Bimedial hang-back recession-outcomes and surgical response. *Eye*. 2005 Nov;19(11):1178.
10. Helveston EM .Surgical Management of Strabismus. 5th ed. Belgium: Wayenborgh Publishing; 2005. Chapter 7, Recession of a rectus muscle ; p.193
11. Helveston, E.M. Surgical management of strabismus: An Atlas Of Strabismus Surgery. 4th ed. Indiana: Mosby Inc.
12. Rajavi Z, Ghadim HM, Nikkhoo M, Dehsarvi B. Comparison of hang-back and conventional recession surgery for horizontal strabismus. *J Pediatr Ophthalmol Strabismus*. 2001 Sep 1;38(5):273-7.
13. Rodrigues AC, Nelson LB. Long-term results of hang-back lateral rectus recession. *J Pediatr Ophthalmol Strabismus*. 2006 May 1;43(3):161-4.
14. Betts C, Olitsky S. Corneal astigmatic effects of conventional recession vs suspension recession (“hang-back”) strabismus surgery: a pilot study. *Binocul Vis Strabismus Q*. 2006;21(4):211-3.
15. Metz HS. Myasthenia gravis presenting as internuclear ophthalmoplegia. *J Pediatr Ophthalmol Strabismus*. 1977 Jan 1;14(1):23-4.
16. Breckenridge AL, Dickman DM, Nelson LB, Attia M, Ceyhan D. Long-term results of hang-back medial rectus recession. *J Pediatr Ophthalmol Strabismus*. 2003 Mar 1;40(2):81-4.
17. Agrawal S, Singh V, Yadav A, Bangwal S, Katiyar V. Modified adjustable suture hang-back recession: Description of technique and comparison with conventional adjustable hang-back recession. *Indian J Ophthalmol*. 2017 Nov;65(11):1183.
18. Gaballah KA. Hang-back technique versus conventional rectus recession in strabismus surgery. *J Egypt Ophthalmol Soc*. 2018 Jul 1;111(3):123.