



## Research Article

# Surgical Outcomes of External Dacryocystorhinostomy Under Local Anaesthesia in a Tertiary Care Hospital: A Prospective Cohort Study

Usama Iqbal<sup>1</sup>, Farhan Ali<sup>2</sup>, Irfan Qayyum Malik<sup>3</sup>, Sarmad Zahoor\*<sup>4</sup>, Hafiz Abdul Rehman Waqas<sup>5</sup>.

<sup>1</sup>Post Graduate Resident Department of Ophthalmology Gujranwala Medical College/ Teaching Hospital, Gujranwala; <sup>2</sup>Assistant Professor, Department of Ophthalmology Gujranwala Medical College/ Teaching Hospital, Gujranwala; <sup>3</sup>Associate Professor, Department of Ophthalmology Gujranwala Medical College/ Teaching Hospital, Gujranwala; <sup>4</sup>Post Graduate Resident. Department of Cardiology, Punjab Institute of Cardiology, Lahore; <sup>5</sup>Medical Officer, Department of Ophthalmology Gujranwala Medical College/ Teaching Hospital Gujranwala.

### Abstract

**Objective:** This study was designed to conclude the success rate of external dacryocystorhinostomy surgery, patient concerns about surgical scar mark and their satisfaction with the appearance of surgical scar.

**Methods:** A prospective cohort study was conducted at Department of Ophthalmology, Gujranwala Medical College/ Teaching Hospital. Total 74 operated cases of DCR surgery under local anaesthesia in two year period (2018-19) were included. Mean follow-up was up to 11 months. Surgical success was defined as resolution of complaint of epiphora. Surgical failure was defined as blockage of lacrimal pathway on syringing. Patient concerns about surgical scar mark and their satisfaction with the appearance of surgical scar was also assessed by telephonic interview.

**Results:** Out of 74 patients 61 (82.43%) were female and 13 (17.56%) were male. Mean age of patients was  $39.49 \pm 14.26$  years. 10 patients had epiphora at the end of follow-up. Majority of failed cases presented at 3 month. Lacrimal syringing on 1 week follow-up was effective to clear any debris or blood clot. The success rate (86.49%) calculated from those patients (n = 67) who completed the follow-up. 46 (68.65%) were not satisfied with the appearance of their surgical scar mark.

**Conclusion:** External DCR performed in local anesthesia is a safe procedure with a success rate of above 85% at one year follow-up. Lacrimal pathway syringing, on follow-up after DCR surgery, can be effective to wash blood clot or debris. Majority of the patient do not find surgical scar mark cosmetically acceptable.

**Corresponding Author** | Dr. Sarmad Zahoor, (MBBS). Post Graduate Resident. Department of Cardiology, Punjab Institute of Cardiology, Lahore. **Email:** drsarmadzahoor@gmail.com

**Key Words:** Epiphora, Dacrocystitis, Dacryocystorhinostomy, Lacrimal System

### Introduction

In normal physiology tears pass through the lacrimal passages including lacrimal punctum, lacrimal canaliculi, lacrimal sac and naso-lacrimal duct. If there is any compromise along this normal pathway to tears outflow, there will be overflow of

tears known as epiphora<sup>1</sup>. Blockage of the lacrimal outflow can happen at any age. It can be congenital or acquired. Acquired nasolacrimal duct obstruction is a common cause of epiphora in adult population. Mostly it is idiopathic. Treatment for naso-lacrimal duct obstruction is a surgical procedure known as external dacryocystorhinostomy (DCR)<sup>2</sup>. It was first

described by Addeo Toti in 1904 and gained popularity due to its efficacy and relatively low complication rate<sup>3</sup>. It was later modified with suturing of lacrimal and nasal mucosal flaps in 1921's. It remains the gold standard procedure for the management of naso-lacrimal duct obstruction<sup>4,5</sup>.

With the introduction of endoscopy in surgical fields, the endo-nasal approach using nasal endoscope is gaining popularity in modern ophthalmology<sup>6,7</sup>. It has advantage of decreased morbidity, early post-operative recovery and better cosmetic results. Despite these changes in surgical approaches and surgical techniques, the underlying principle of reestablishing patent communication between the lacrimal sac and the nasal cavity, has not changed since dacryocystorhinostomy (DCR) was introduced<sup>3</sup>. The success range of DCR depend on many factors. It ranges from 68-90 % in different studies<sup>8</sup>.

External DCR is not performed routinely in private sector ophthalmic units of our locality. Department of Ophthalmology, Gujranwala Medical College/Teaching Hospital, Gujranwala is the only ophthalmic unit in whole district which is providing this facility to the patients of chronic dacryocystitis. Because of large burden of patients with this disease it is often required to perform this surgery in local anaesthesia. The objective of this study was designed to conclude the success rate DCR surgery in this setup. Because our unit is the only unit providing facility of DCR surgery to the patients of chronic dacryocystitis, the rationale of this study is to compute the current success rate and to look for the factors which can improve the success rate, patient concerns about surgical scar mark and their satisfaction with the appearance of surgical scar.

## Methods

A prospective cohort study was designed for the patients of chronic dacryocystitis who had underwent external DCR surgery, at ophthalmology department, DHQ teaching hospital/Gujranwala. The study was approved by Institutional Review Board, Gujranwala Medical College (Admin.213/GMC). Study duration was two years from January 2018 to December 2019.

Consecutive sampling was used as sampling technique. Inclusion criteria included all the patients with chronic dacryocystitis who were booked for ext-

ernal DCR surgery after informed consent. All the patients were examined by consultant ophthalmologist before being advised external DCR surgery. The patients were counselled about the nature of disease, surgical options, surgical scar mark and cosmetic aspects of surgery. Exclusion criteria included those patients suffering from acute infection (acute dacryocystitis), refusing for surgery under local anaesthesia or not willing to participate in this study. Because facility of endo-nasal DCR is not available in our setup, those patients who were not willing for surgery because of cosmetics aspects were not included.

The patients who had positive regurgitation test (Figure 1) were diagnosed as nasolacrimal duct blockage and were booked for surgery without any pre-operative diagnostic probing. Those who had negative regurgitation test were advised diagnostic probing. Only those patient who had common canalicular blockage on diagnostic probing were planned for DCR surgery with intubation. Pre-operatively all the patients had completed the course of topical antibiotics. All the surgeries were performed under local anaesthesia by one senior author. Nasal packing was prepared by soaking the gauze in xylocaine gel, and 5 ml of 2 % commercially available Xylocaine injection. Injection of local anesthetic (5 ml anesthetic formulation made by 2.5 ml of 2% Bupivacaine and 2.5 ml of 2% xylocaine) was given at three points; supratrochlear block, infra-trochlear block and 10 mm from medial canthus. No sedative or Intra muscular analgesics were used in any case. After painting and draping the surgical site, skin incision was given 10 from medial canthus at the level of medial canthal tendon. Orbicularis Oculi muscle fibers were dissected until periosteum is reached. Medial canthal tendon was dis-inserted for better view of lacrimal sac. Periosteum of anterior lacrimal crest was incised and raised. Lacrimal sac was separated from lacrimal fossa. 8-9 mm of bone adjacent to lacrimal sac was removed to create a bony window. Anterior flaps of lacrimal sac and nasal mucosa were raised and secured with 6/0 polyglactin suture (figure 2). Patients with canalicular blockage had silicon tube passed through canaliculi before securing the flaps. The muscle and skin were closed in layered fashion. Post operatively patients were kept in ward for one day. Nasal packing was removed after 24 hours.

Patients were followed up after 1 week, 1 month and at 3 months for examination of surgical scar or any

complain of epiphora. DCR tube was removed after 3 months. After that all the patients were interviewed by a telephonic call from the department. Patients were asked questions about active complaint of epiphora and condition of surgical incision scar. Surgical success was defined as resolution of complaint of epiphora. Lacrimal syringing with N/Saline was performed in those patients who had active complaint of epiphora on follow-up. Surgical failure was defined as blockage of lacrimal pathway on syringing. Regarding patients satisfaction was assessed by resolution of complaint and their concerns about surgical scar mark.

Data regarding demographics (gender, age and duration of symptoms), pre-operative assessment (regurgitation test and level of obstruction) and post-operative events was collected from patient's record file. On follow-up all patients were examined by one of the authors on initial visits. Data was entered on excel sheets, and then transferred to SPSS v 20.00. Descriptive statistics were used to describe the data.

### Results:

Total 74 patients were operated for dacryocystitis during study duration. Demographic details are given in table 1. Epiphora with discharge was the presenting complaint in all the patients. Other presenting complaints were medial canthus swelling, morning stickiness and pain. Regurgitation test was performed in all the patients. Regurgitation test was positive in 65 (87.83%) patients (figure 4). Remaining 9 (12.16%) patients had canalicular or common canalicular obstruction on diagnostic probing.

Per-operative complications and post-operative patients findings on follow-ups are enumerated in table 2. 20 (27.02%) patients presented with epiphora at one month follow-up in whom N/saline irrigation of lacrimal pathway was performed to wash any accumulated debris or any blood clot. Lacrimal pathway was patent in all these patients on syringing. Epiphora resolved in 18 out of 20 patients by this syringing of lacrimal pathway.

The failed cases presented after 3 months duration. 4 cases presented at 3 months duration, who had positive regurgitation test on examination. On successive

follow-ups 67 out of 74 patients were interviewed successfully on telephone. 7 patients were lost on follow-up. Maximum duration of follow-up was 20 months and minimum duration was 3 month. Mean duration of follow-up was 11.5 months. When patients were asked about active complaint of epiphora, 57 (85.07%) (n=67) patients responded that they have no complain of epiphora at present, 10 (14.92%) (n=67) patients had active complaint of epiphora. About surgical scar 46 (68.65%) (n=67) patients responded that they find their surgical incision scar mark cosmetically problematic. 21 (31.35%) (n=67) patients responded that either they are not worried about their surgical scar mark or the scar is faint (table 3).

**Table 1:** Demographic details of patients

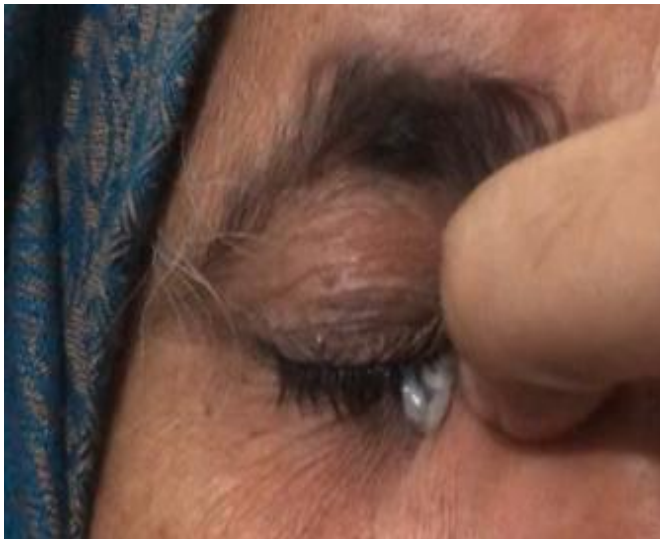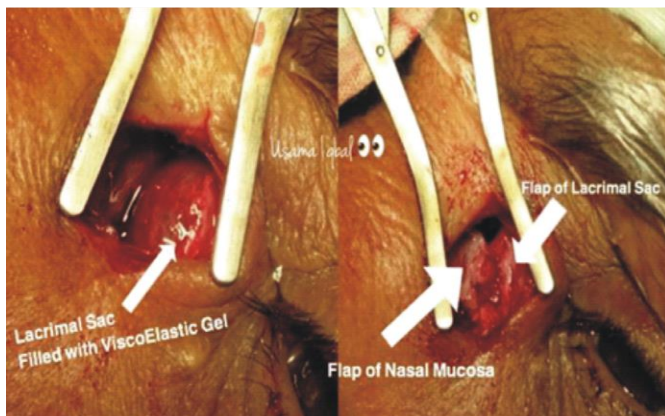
Demographic detail of patients	
	Mean
<b>Age</b>	39.49 ± 14.26 years
<b>Gender Distribution</b>	Frequency
Male	13 (17.56%)
Female	61 (82.43%)
	n = 74
	Mean
<b>Duration of symptoms</b> (Disease course)	3.10 ± 2.44 years

**Table 2:** Per-operative and Post-operative findings

Complications	Number of patients (n=74)
<b>Per-Operative</b>	
Excessive Bleeding	12 (16.21%)
Failure to secure flaps	7 (9.4%)
Failure to break maxillary-lacrimal suture	1 (1.35%)
<b>Post-Operative</b>	
<b>After 24 Hours</b>	
Periorbital swelling	44 (59.45%)
Periorbital ecchymosis	21 (28.37%)
Surgical site infection	1 (1.37%)
<b>One Week Follow-up</b>	
Medial Canthus Emphysema	4 (3.7%)
Medial Canthus cicatrisation	1 (1.37%)
<b>1 Months Follow-up</b>	
Epiphora with discharge	20 (27.02%)
<b>3 months Follow-up</b>	
Epiphora with discharge	4 (5.4%)

**Table 3:** Surgical Success and Patients satisfaction with surgical scar

Variables	Distribution (n=67)
<b>Surgical Success</b>	
Successful	57 (85.07%)
Failure	10 (14.92%)
( Per Protocol Analysis)	
<b>Total</b>	<b>67 (100%)</b>
<b>Patients Satisfaction with Surgical Scar</b>	
Scar was cosmetically problematic	21 (31.35%)
Scar was not cosmetically problematic	
<b>Total</b>	<b>67 (100%)</b>

**Figure 1:** Positive regurgitation test**Figure 2:** Lacrimal Sac filled with viscoelastic gel per-operatively to have a good sized flap Shown on right. Flaps of lacrimal sac and nasal mucosa after being secured using 6/0 vicryl Shown on left**Discussion:**

Chronic dacryocystitis is common in middle age adults. In our study, mean age of patients was  $39.49 \pm 14.26$  years with female predominance 61 (82.43 %) (n=74). This is comparable to other studies<sup>9,10,11</sup>. Some studies report higher mean age above 40 years by Rashid et al and even above 50 years in other studies<sup>2,8,12</sup>. Female predominance is seen generally in all the studies. It can be due to narrow anatomy of bony lacrimal pathway in females<sup>9</sup>.

Regurgitation test was performed in all the patients in our study. Positive regurgitation test depicts that there is stasis of tears at the level of lacrimal sac, both the lacrimal canaliculi and common canalicular duct are patent and blockage is present at the level of naso-lacrimal duct. Diagnostic probing syringing was performed only in those patients who had negative regurgitation test. Similar diagnostic protocol was used in a local study<sup>13</sup>. Dacryocystography and CT imaging were not required. Some studies suggest that they are useful in traumatic cases<sup>13,14</sup>.

Silicon tube Intubation was only performed in those patients who had canalicular or common canalicular duct blockage. In a local study done by Zia et al., it was reported that silicon intubation is unnecessary in case of patent lacrimal canaliculi<sup>15</sup>. Similar findings were reported in a meta-analysis conducted by Feng et al who showed no significant difference between the success rate of DCR surgery with or without the use of silicone tube<sup>16</sup>. It is considered that anastomosis of both anterior and posterior flaps give better surgical results<sup>1</sup>. In our study only anterior flaps were anastomosed. Securing anterior and posterior flaps sometimes become technically difficult<sup>1</sup>.

The most common complication after 24 hours was periorbital swelling noted in 59.45% of the patients. Qaim et al., reported echymosis as the most common finding observed after 24 hours<sup>10</sup>. Only one case of surgical site infection was noted in our study.

Surgical success was defined by resolution of epiphora symptoms. The success rate of external DCR reported in literature range from 75-95%<sup>17</sup>. In our study, total 10 patients had epiphora at the end of

follow-up. 4 patients presented at 3 months. Remaining 6 presented between 3-6 months. In our study 7 patients lost follow-up. The success rate (86.49%) calculated from those patients (n=67) who completed the follow-up. In a local study done by Rashid et al., who used similar definition of surgical success (i.e resolution of epiphora) 61.4 % success rate was reported. The duration of follow-up was 61 months<sup>3</sup>. The success rate of our study is better, it can be due to short follow-up duration (11 months as compared to 61 months). Other studies done in South Asia report success rate of 84.6% (three month follow-up) and 78%<sup>1,12</sup>. In a retrospective medical record review study of 769 patients the functional success rate was reported as 81.9%<sup>19</sup>. The success of our study is comparable to other studies. Difference in the range can be due to difference in duration of follow up. Some studies report success rate of above 90% with adjunctive mitomycin C<sup>6,16, and 20</sup>. In our study mitomycin C was not used. Also the studies which report success rate of above 90% have short duration of follow-up mostly 6 months.

Regarding surgical scar mark majority (68.65%) of the patients replied that either their scar was not fait or they were not satisfied with the appearance of their scar mark. Rizvi et al., in their study have concluded that scaring at surgical site should not be a reason for deciding the surgical approach<sup>21</sup>. They have reported that surgical scar visibility improved successively on follow up noted photographic evaluation by two independent observers. In our study only patient's comments about surgical scar mark are reported with no independent observation by second observer.

It is a single centre study with limited sample size and limited duration of follow-up. Authors recommend large sample multi centre studies with long follow-up duration. Aesthetics opinion can be sought by dermatologists and plastic surgeons to have better cosmetic results in relation to surgical scar. Multi-disciplinary studies can also be planned.

## Conclusion

External DCR performed in local anaesthesia is safe procedure with a success rate of above 85% at one year follow-up. Most of the failed cases present at

around 3 months post-operatively. Lacrimal pathway syringing, on follow-up after DCR surgery, can be effective to wash blood clot or debris. Majority of the patient do not find surgical scar mark cosmetically acceptable.

**Ethical Approval:** Given

**Conflict of Interest:** The authors declare no conflict of interest

**Funding Source:** None

## References:

1. Pokharel SM, Chaudhary SK, Chaurasiya BD. Factors Affecting the Success Rate of External Dacryocystorhinostomy at BP Koirala Institute of Health Sciences, Dharan, Nepal. *Birat Journal of Health Sciences*. 2017; 2(2):196-200.
2. Baig R, Khan QA, Ahmad K. Long-term outcome of primary external dacryocystorhinostomy. *JCPSP: J Coll Physicians Surg Pak*. 2013; 23(9):641.
3. Toti A. Nuovo metodo conservatore di radicale delle suppurazioni croniche del sacco lacrimale (dacriocystorhinostomia). *Cli. Mod. Pisa*. 1904; 10:385-7.
4. Leong SC, MacEwen CJ, White PS. A systematic review of outcomes after dacryocystorhinostomy in adults. *American journal of rhinology & allergy*. 2010; 24(1):81-90.
5. Badhu B, Dulal S, Kumar S, Thakur SK, Sood A, Das H. Epidemiology of chronic dacryocystitis and success rate of external dacryocystorhinostomy in Nepal. *Orbit*. 2005; 24(2):79-82.
6. Karim R, Ghabrial R, Lynch TF, Tang B. A comparison of external and endoscopic endonasal dacryocystorhinostomy for acquired nasolacrimal duct obstruction. *Clinical ophthalmology (Auckland, NZ)*. 2011;5(2):979.
7. Agarwal S. Endoscopic dacryocystorhinostomy for acquired nasolacrimal duct obstruction. *The Journal of Laryngology & Otology*. 2009; 123(11):1226-8.
8. Lefebvre DR, Dhar S, Lee I, Allard F, Freitag SK. External dacryocystorhinostomy outcomes in patients with a history of dacryocystitis. *Digital journal of ophthalmology: DJO*. 2015;21(3):1.
9. Shaikh RM, Hadrawi MT, Danish EY. Comparison of Success Rate of External Dacryocystorhinostomy with and without Mitomycin-C in patients of Chronic Dacryo-cystitis. *Pakistan J Med Heal Sci*. 2015; 9(3) :934-936.
10. Khan QA, Zia S, Iqbal Y. External Dacryocystorhinostomy under Local Anesthesia. *Pakistan Journal of Ophthalmology*. 2016;32(1):43-47.
11. Mukhtar SA, Jamil AZ, Ali Z. Efficacy of external dacryocystorhinostomy (DCR) with and without mitomycin-C in chronic dacryocystitis. *J Coll Physicians Surg Pak*. 2014; 24(10):732-5.

12. Ghasemi H, Asl SA, Yarmohammadi ME, Jafari F, Izadi P. External Dacryocystorhinostomy; Success Rate and Causes of Failure in Endoscopic and Pathologic Evaluations. *Iranian journal of pathology*. 2017;12(3):189.
13. Aslam MA, Mirza AB, Butt IA. Results of endoscopic endonasal dacryocystorhinostomy. *JPMA*. 2014; 64(6):619.
14. Muscatello L, Giudice M, Spriano G, Tondini L. Endoscopic dacryocystorhinostomy: personal experience. *Acta otorhinolaryngologica italica*. 2005; 25(4):209.
15. Muhammad Z, Tariq M, Jalis M, Khalid A. Is Silicone Intubation Necessary in Dacryocystorhinostomy? *Pakistan Journal of Ophthalmology*. 2016; 32(4):212-215.
16. Feng YF, Cai JQ, Zhang JY, Han XH. A meta-analysis of primary dacryocystorhinostomy with and without silicone intubation. *Canadian journal of ophthalmology*. 2011; 46(6):521-527.
17. Ozer S, Ozer PA. Endoscopic vs external dacryocystorhinostomy-comparison from the patients' aspect. *International journal of ophthalmology*. 2014;7(4):689.
18. Gupta SK. Intention-to-treat concept: a review. *Perspectives in clinical research*. 2011; 2(3):109.
19. Lee MJ, Khwarg SI, Kim IH, Choi JH, Choi YJ, Kim N, et al,. Surgical outcomes of external dacryocystorhinostomy and risk factors for functional failure: a 10-year experience. *Eye*. 2017; 31(5):691-697.
20. Das N, Zafar S, Jafri FA, Rizvi SF. Outcome of External Dacryocystorhinostomy with Adjunctive Mitomycin C in Tertiary Care Hospital. *Pakistan Journal of Ophthalmology*. 2016; 32(2):158-163.
21. Rizvi SA, Saquib M, Maheshwari R, Gupta Y, Iqbal Z, Maheshwari P. Cosmetic evaluation of surgical scars after external dacryocystorhinostomy. *International journal of ophthalmology*. 2016; 9(12):1745.