

## Research Article

### Accuracy of High Resolution Ultrasonography for Diagnosis of Rotator Cuff Tears Considering Magnetic Resonance Imaging as Gold Standard

Rana Dilawaiz Nadeem<sup>1</sup>, Khalid Rehman Yousaf<sup>2</sup>, Muhammad Tahir Yusuf<sup>3</sup>, Muhammad Akhtar<sup>4</sup>, Mumraiz S. Naqshband<sup>5</sup>, Irfan Ahmed<sup>6</sup>, Muhammad Jazib Nadeem<sup>7</sup>

<sup>1</sup>Chairman/Professor, Department of Orthopedic Surgery, KEMU/Mayo Hospital, Lahore; <sup>2</sup>Head/ Associate Professor, Department of Radiology, FJMU/Sir Ganga Ram Hospital, Lahore; <sup>3</sup>Senior Registrar, Orthopedic Surgery, Jinnah Hospital, Lahore; <sup>4</sup>Associate Professor, Orthopedic Surgery, KEMU/Mayo Hospital, Lahore; <sup>5</sup>Assistant Professor, Orthopedic Surgery, KEMU/Mayo Hospital, Lahore; <sup>6</sup>Senior Registrar, Orthopedic Surgery, Mayo Hospital, Lahore; <sup>7</sup>Internship, Department of Orthopedic Surgery, Services Hospital, Lahore

#### Abstract

**Objective:** To determine the diagnostic accuracy of high-resolution ultrasonography for the diagnosis of rotator cuff tears considering magnetic resonance imaging as gold standard.

**Methodology:** This correlational study was done using non-probability consecutive sampling technique, at the Department of Orthopaedic Surgery and the Department of Radiology, Services Hospital Lahore from 15th July 2013 till 14th January 2016. All the patients, age between 40 to 70 years, who presented with shoulder pain for last three month, that was not settled with oral analgesic, and were positive for Hawkin's -Kennedy test, Jobe's test and drop arm were included in the study. Patients who had fracture of the clavicle, scapula or proximal end of humerus, and patients with prosthetic implants and pacemakers were excluded in the study. All clinical test positive patients underwent ultrasonography (USG) and magnetic resonance imaging (MRI). We calculated specificity, sensitivity, positive predictive value (PPV), negative predictive value (NPV), accuracy and likelihood ratio for ultrasonography.

**Results:** Out of the total 92 patients, on MRI there were 68 (73.9%) complete and 24 (26.1%) partial Rotator Cuff Tears. USG diagnosed 62 out of 68 complete tears accurately. There were 21 true negative and 03 false positive complete tears. USG showed sensitivity of 91%, specificity of 87% (p-value <0.001 using T-test), positive predictive value (PPV) of 95%, negative predictive value of 77%, accuracy of 90.2 %, positive likelihood ratio of 9.55 and negative likelihood ratio of 0.15.

**Conclusion:** USG of the shoulder with a high definition linear array probe was found a highly accurate and reliable screening test for the Rotator Cuff Tears and it can be used reliably for the start of treatment of the rotator cuff tears.

**Corresponding Author** | Prof. Rana Dilawaiz Nadeem, Chairman/Professor, Department of Orthopedic Surgery, KEMU/Mayo Hospital, Lahore. **Email:** rdnaeem@yahoo.com

**Key Words:** Diagnostic accuracy, Magnetic Resonance Imaging, Rotator Cuff Tears, Ultrasonography.

#### Introduction

Rotator cuff tear pathologies are responsible for pain and limitation of range of motion of shoul-

der. Its incidence is between 30 to 70 %<sup>1</sup>. To treat a RCT's, the orthopedic surgeon must know the type of the RCT's. Clinical evaluation is mandatory in the diagnosis, but it has limitations while determining the

severity of tear. Some radiological investigation is necessary to determine the extent of the tear pathology. Choice to of radiological investigations are various including plain & CT arthrograms, shoulder ultrasound, plain MRI as well as MR Arthrography.<sup>2,3</sup>

Non-invasive investigations like shoulder USG and MRI have do not expose the patient to dangerous ionizing radiations<sup>1,4</sup>. The literature revealed that the most reliable investigation to detect rotator cuff pathologies is MRI but it has many limitations like. not readily available everywhere too much costly along with many contraindications like prosthetic implants, pacemakers, and the claustrophobia etc.<sup>4,5</sup> Another investigation that has good efficacy is USG of the shoulder, which is cost effective, readily available everywhere and permits dynamic imaging.<sup>6</sup> USG having a sensitivity of 85%, specificity 93% with 77% accuracy. The positive and negative predictive values were 88% and 72%.<sup>6</sup> MRI has sensitivity (up to 100%) and specificity (up to 99%) in diagnosing rotator cuff tears.<sup>7,8</sup>

In suspicion of rotator cuff tears clinician needs some cost-effective investigation for confirmation of the diagnosis. USG of shoulder can serve our purpose well because USG has better sensitivity and specificity in the hands of an experienced radiologist. This study was designed to compare the efficacy of USG in diagnosing RCT's with MRI considering the MRI as gold standard which has 99 to 100 % sensitivity and specificity.

## Methodology

This correlational study was done using non-probability consecutive sampling technique at department of Orthopedic surgery and department of Radiology Services Hospital, Lahore from 15<sup>th</sup> July 2013 till 14<sup>th</sup> January 2016. Sample size was 92 patients, 40 to 70 years of age, who had three months continued shoulder pain not being settled with oral analgesic and positive Hawkin's - Kenndy, Jobe's test and drop for rotator cuff tear arm test were included in the study. Patients who had fracture of the clavicle, scapula or proximal end of humerus were excluded from the study. Patients with prosthetic implants and pacemakers were also excluded from the study.

After Institutional and Ethical Review Board permission informed written consent was obtained with reference number IRB/2014/78/SIMS dated 16/07/2104. The plain radiographs of shoulder AP and lateral view of patients were taken in the Radiology Department of Services hospital Lahore. All clinical test positive patients underwent USG and MRI respectively. Ultrasonography of the patients was performed by the Musculoskeletal Radiologist in the same hospital. MRI of shoulder was done at the Radiology Department of the Sir Ganga Ram Hospital, Lahore. Data was collected on daily basis from the out-patient department. Findings of the patients were noted from all the investigations on the printed questionnaire. Questionnaires were put into the files according to the date, to maintain accuracy.

**Tear Positive on Ultrasonography :** Complete and partial tear of supraspinatus tendon, with anechoic or hypoechoic defect extending from the articular to the bursal surface or a contour defect of the subdeltoid fat plane extending medial to the junction of the humeral head and greater tuberosity or a hypoechoic, mixed hypoechoic or echogenic defect incompletely traversing the supraspinatus tendon, but extending to the articular or bursal surface or a contour defect of the subdeltoid fat plane not extending medial to the junction of the humeral head and greater tuberosity was regarded as tear positive.

**Tear Positive on MRI:** A well-localized area with increased signal intensity on T1-weighted and T2-weighted images from the bursal to the articular surface was taken as complete tear or incomplete fluid across the tendon was taken as partial tear.

Analysis of data was done using SPSS version-20. Quantitative variables were summarized using mean  $\pm$  standard deviation while qualitative variables were summarized using frequency and percentages. Statistical parameters in terms of sensitivity, specificity, accuracy, likelihood ratio and in terms of positive and negative predictive value were calculated for ultrasonography.

## Results

92 patients in total were included in the study. Out of 92 patients, 44 (47.8%) patients were males while 48

(52.2%) were females. Mean age was  $49.4 \pm 12.4$  years with age range of (40-70 years). 41 (44.6%) were labour workers. Housewives were 26 (28.3%) and the reason for their shoulder pain was found to be house-hold cleaning while sports men (mostly athletes) were 16 (17.4%) (Table 1). T-test was used as test of significance for P value, all P values < 0.05 were significant.

Out of the total 92 patients, on MRI there were 68 (73.9%) complete and 24 (26.1%) partial RCT's. USG diagnosed 62 out of 68 complete tears (sensitivity of 91%) accurately. There were 21 true negative and 03 false positive complete tears (specificity 87%) (p-value < 0.001). The positive predictive (PPV) value was 95%, negative predictive value (NPV) 77% and accuracy 90.2% (Table 2). The positive likelihood

ratio and negative likelihood ratio was 9.55 and 0.15 for USG respectively.

**Table 1:** Demographic data of age, gender and occupation:

| Variables              | Frequency (N=92) (%)               |
|------------------------|------------------------------------|
| Age (in years)         | (Mean $\pm$ S.D) $49.65 \pm 12.42$ |
| <b>Gender</b>          |                                    |
| • Male                 | 44 (47.8%)                         |
| • Female               | 48 (52.2%)                         |
| <b>Occupation</b>      |                                    |
| • Labor Workers        |                                    |
| • Housewives           | 41 (44.6%)                         |
| • Sports men           | 26 (28.3%)                         |
| • People with crutches | 16 (17.4%)                         |
| • Others               | 03 (3.2%)                          |

**Table 2:** Accuracy of high resolution ultrasonography for rotator cuff tears:

|                                  | Full Thickness Tear | Partial Thickness Tear | Total | p-Value |
|----------------------------------|---------------------|------------------------|-------|---------|
| Ultrasound (USG)                 | 62                  | 03                     | 65    | < 0.001 |
| Magnetic Resonance Imaging (MRI) | 68                  | 24                     | 92    |         |

Sensitivity = 91%

Specificity = 87 %

Positive Predictive value = 95 %

Negative Predictive value = 77%

Diagnostic Accuracy= 90.2 %

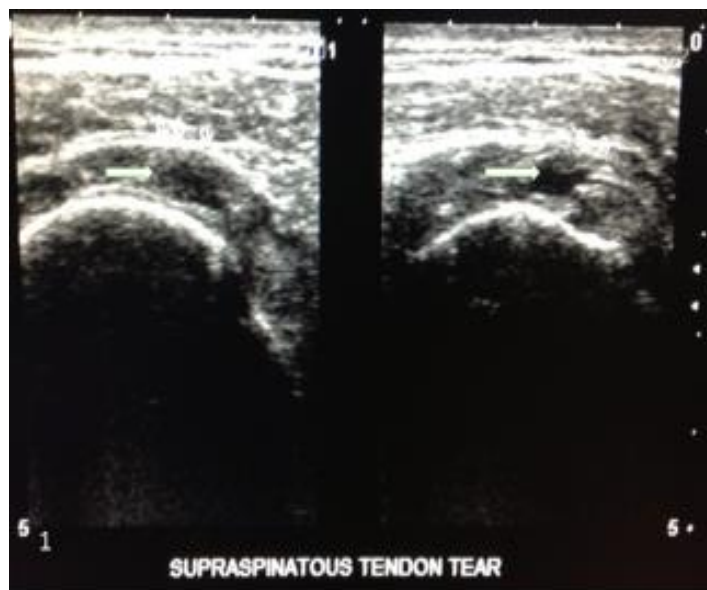

Figure 1. Partial thickness tear of SST in a 48 year old female

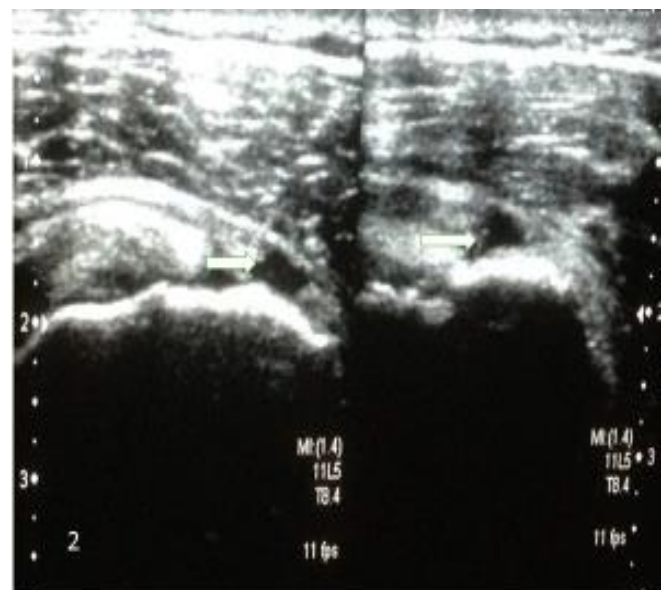

Figure 2 . Full thickness tear of supraspinatus tendon without retraction in a 54 year old male

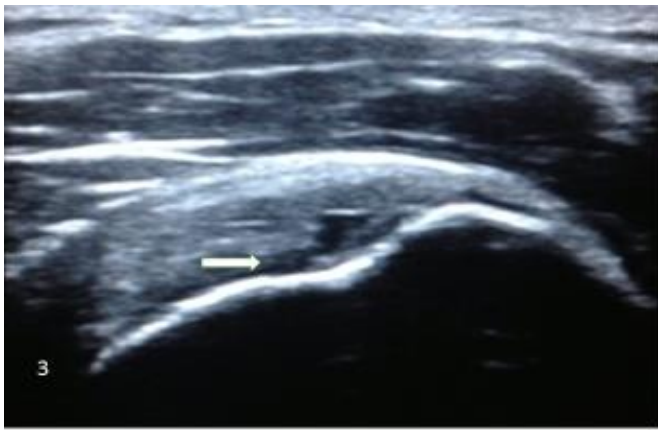


Figure 3. Partial thickness tear of articular surface of SST in a 65 year old female

### Discussion

Rotator cuff pathologies are frequently faced by the orthopedic surgeons in patients with shoulder pain and its incidence is between 30 to 70 %<sup>8</sup>. Out of 92 patients, 44 (47.8%) patients were males while 48 (52.2%) patients were females. Subharwal et al<sup>9</sup> had 68.3% females and 32.7% males' patients in their study.

With mean age  $49.4 \pm 12.4$  years, patient presented in different age groups with minimum age of 40 years and maximum age of 70 years. Fischer et al.<sup>10</sup> reported mean age of the patient was 68.3 years (range 49-81). The difference in mean age was due to inclusion of 40 to 70 years old patients in our study as compared to 40-81 years in their study.

Our study showed the sensitivity of 91%, specificity 87% while the PPV was 95% and NPV was calculated to be 77% for USG. Diagnostic accuracy was 90.2%. Van Holsbeek et al.<sup>11</sup> showed a sensitivity of 93% which is better than our study. These results show reliability of shoulder ultrasound and accurate screening test for the RCT's. Literature has shown a wide range of variability in the results of shoulder USG for the RCT's. Naqvi et al<sup>15</sup> reported USG 80% and 89% sensitivity and specificity respectively.

The findings of Okoroha et al<sup>12</sup> are consistent with findings of our study. Matthieu et al<sup>13</sup> showed 65% specificity for USG which is low as compared to our study. Roy et al.<sup>14-17</sup> reported 91% sensitivity and 86% specificity for USG. For USG, the finding of his study

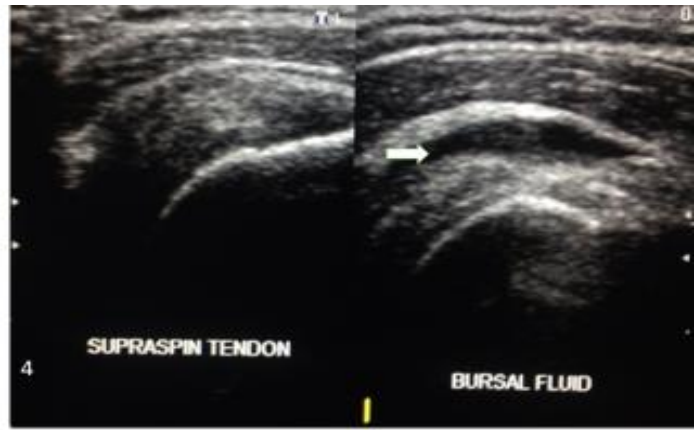

Figure 4. Fluid in the SASD bursa in a 45 year old male

is consistent with our study. In our study, USG has shown good results in detection of RCT. Our findings are similar to many studies and differ from other studies as well. The probable reason behind this difference can be due to lack of comfort, knowledge and training in USG and hesitation of Orthopaedic surgeon to incorporate USG in diagnosis of RCT<sup>15,18</sup>. USG is cheap, effective and easily available modality. With awareness, and accuracy in training the use of USG can be incorporated as a reliable tool for diagnosis of rotator cuff tears. In developing country like Pakistan, MRI requires too much cost, long waiting time, and has contraindications. Such limitation with MRI can be avoided with better knowledge and training of USG amongst orthopedic surgeon. Butterfly IQ diagnostic ultrasound which is new handy device is changing the way of medical practice in diagnosis of RCT without radiations<sup>16-20</sup>. This will change the practice of ionizing radiation exposure and expensive MRI for diagnosis of RCT.

The limitation with this method of USG is that the operator of the USG must be very competent in the musculoskeletal ultrasound which is the main determinant of the accuracy of the USG shoulder otherwise the results are not much favorable and accurate. We didn't measure the extent of thickness of RCT's.

To our knowledge limited work has been undertaken before in Pakistan so our study will be helpful in establishing the local data for the accuracy of ultrasonography of the shoulder for RCT's and it will serve as a guide for the future research on this subject. Furt-

her, we recommend the confirmation of RCT's tears on shoulder arthroscopy.

## Conclusion

Ultrasonography of the shoulder with a high definition linear array probe is a highly accurate and reliable diagnostic test for the RCT's and it can be used reliably for the start of treatment of the rotator cuff tears.

**Ethical Approval:** Given

**Conflict of Interest:** The authors declare no conflict of interest

**Funding Source:** None

## References:

- Klaips CL, Jayaraj GG, Hartl FU. Pathways of cellular proteostasis in aging and disease. *J Cell Biol.* 2018;217(1):51-63.
- Cullen DM, Breidahl WH, Janes GC. Diagnostic accuracy of shoulder ultrasound performed by a single operator. *Australas Radiol.* 2007;51(3):226-9.
- Gismervik SØ, Drogset JO, Granviken F, Rø M, Leivseth G. Physical examination tests of the shoulder: a systematic review and meta-analysis of diagnostic test performance. *BMC Musculoskelet Disord.* 2017;18(1):41.
- Wallny T, Wagner UA, Prange S, Schmitt O, Reich H. Evaluation of chronic tears of the rotator cuff by ultrasound: A NEW INDEX. *J Bone Joint Surg Br.* 1999;81-B(4):675-8.
- Naqvi GA, Jadaan M, Harrington P. Accuracy of ultrasonography and magnetic resonance imaging for detection of full thickness rotator cuff tears. *Int J Shoulder Surg.* 2009;3(4):94-7.
- Teng A, Liu F, Zhou D, He T, Chevalier Y, Klar RM. Effectiveness of 3-dimensional shoulder ultrasound in the diagnosis of rotator cuff tears: A meta-analysis: A meta-analysis. *Medicine (Baltimore).* 2018; 97(37):e12405.
- Brockmeyer M, Schmitt C, Hauptert A, Kohn D, Lorbach O. Limited diagnostic accuracy of magnetic resonance imaging and clinical tests for detecting partial-thickness tears of the rotator cuff. *Arch Orthop Trauma Surg.* 2017;137(12):1719-24.
- Zlatkin MB, Hoffman C, Shellock FG. Assessment of the rotator cuff and glenoid labrum using an extremity MR system: MR results compared to surgical findings from a multi-center study. *J Magn Reson Imaging.* 2004;19(5):623-31.
- Sabharwal T, Khanduri S, Khan S, Husain M, Singh A, Khan AU, et al. A comparative assessment between high-resolution ultrasonography and field magnetic resonance imaging in supraspinatus tear cases and its arthroscopic correlation. *Cureus.* 2019;11(9):e5627.
- Fischer CA, Weber M-A, Neubecker C, Bruckner T, Tanner M, Zeifang F. Ultrasound vs. MRI in the assessment of rotator cuff structure prior to shoulder arthroplasty. *J Orthop.* 2015;12(1):23-30.
- van Holsbeeck MT, Kolowich PA, Eyler WR, Craig JG, Shirazi KK, Habra GK, et al. US depiction of partial-thickness tear of the rotator cuff. *Radiology.* 1995;197(2):443-6
- Okoroa KR, Mehran N, Duncan J, Washington T, Spiering T, Bey MJ, et al. Characterization of rotator cuff tears: Ultrasound versus magnetic resonance imaging. *Orthopedics.* < C, Leblond J, Desmeules F, Dionne CE, MacDermid JC, et al. Diagnostic accuracy of ultrasonography, MRI and MR arthrography in the characterisation of rotator cuff disorders: a systematic review and meta-analysis. *Br J Sports Med.* 2015;49(20):1316-28.
- Kruse KK, Dilisio MF, Wang WL, Schmidt CC. Do we really need to order magnetic resonance imaging? Shoulder surgeon ultrasound practice patterns and beliefs. *JSES open access.* 2019;3(2):93-8.
- Biswas S, Kanodia N, Tak R, Agrawal S, Roy KS. Correlation of clinical examination, ultrasound, magnetic resonance imaging and arthroscopy as diagnostic tools in shoulder pathology. *Int J Res Orthop.* 2020;6(2):247-51.
- Liu F, Dong J, Shen W-J, Kang Q, Zhou D, Xiong F. Detecting rotator cuff tears: A network meta-analysis of 144 diagnostic studies. *Orthop J Sports Med.* 2020;8(2):356.
- Refaat M, Torkey A, Salah El Deen W, Soliman S. Comparing efficacy of shoulder ultrasound and magnetic resonance imaging in shoulder impingement. *Benha Med J.* 2021;38(S):112-127.
- Gilat R, Atoun E, Cohen O, Tsvieli O, Rath E, Lakstein D, et al. Recurrent rotator cuff tear: is ultrasound imaging reliable? *J Shoulder Elbow Surg.* 2018;27(7):1263-7.
- Ringshawl ZY, Bhat AA, Bashir Z, Farooq M, Wani M. Correlation between the Findings of Magnetic Resonance Imaging Shoulder and Shoulder Arthroscopy. *Journal of Clinical & Diagnostic Research.* 2020;14(9):5-10.