

Role of Topical Glyceryl Trinitrate in the Management of Anal Fissure

O F MUHAMMAD H SHAKIR H M AMJAD K M SOHAIL I ZAKRIA A SHAH.

Department of Surgery, Allama Iqbal Medical College/Jinnah Hospital, Lahore

Correspondence to Dr. Omer Farooq Muhammad, Senior Registrar Surgery E-Mail: omerfarooq_025@hotmail.com

Objective: 1) To evaluate the effectiveness of topical 0.2% Glyceryl Trinitrate (GTN) ointment in symptomatic relief and healing of anal fissure 2) To establish the role of GTN as a first line treatment for both acute and chronic anal fissure. 3) To elaborate the safety profile of GTN with respect to its side effects. **Design:** Prospective, randomized case control study. **Place of study:** Surgical unit II, Jinnah Hospital, Lahore. **Duration of Study:** 1 year from 1-2-2005 to 31-2-2006. **Materials and Methods:** Fifty patients of all ages and either sex with a clinical diagnosis of fissure in ano (both acute and chronic) were included in the study. Patients were randomly divided into two groups. The treatment group (Group-A) was advised 0.2% GTN ointment whereas the control group (Group-B) was prescribed a local anesthetic ointment (Lignocaine Compound® Knoll). Both groups applied the given drugs twice daily for a period of 8 weeks and follow-up at the end of first, second and eighth week was carried out. A long-term follow-up at the end of 6 months was undertaken to look for any recurrence of the disease. **Results:** 18 patients out of 50 patients presented with acute anal fissure while 32 presented with chronic anal fissure. 77% of patients with acute fissure in Group A showed fissure healing while 44% of patients with acute fissure were benefited in Group B. When the failures of group B were subjected to GTN, 80% of the patients showed healing of their fissures. 81% of patients suffering from chronic anal fissure were cured in Group A while 25% of patients showed improvement in Group B. Nonbenefited patients in group B when subjected to GTN, 66% showed fissure healing. Recurrence was seen in 8 patients in group A (24%) and 3 patients in group (38%) at long term follow-up. **Conclusion:** Anal fissure is a common general surgical problem associated with severe anal pain. Regarding conservative treatment, the advent of GTN is a healing hope for patients with anal fissure. It has revolutionized the non-surgical treatment, as it is effective, safe and economical in terms of cure of both acute and chronic anal fissures.

Keywords: Anal fissure, Acute anal fissure, Chronic anal fissure, GTN, Glyceryl Trinitrate

Anal fissure is a linear ulcer in the long axis of lower anal canal. It is a common and distressing problem, the true incidence of which is probably higher than recorded¹. It usually occurs, in young and otherwise healthy population. It is a very painful condition and causes suffering out of proportion to the size of the lesion. Classical symptoms are pain on or just after defecation, usually accompanied by bright red blood streak on the surface of the stools. Acute anal fissures have a short history and are superficial splits in the anoderm with sharply demarcated edges² while chronic fissures have a longer history (usually more than two months). Their edges are indurated and horizontal fibers of internal anal sphincter may be visible at the base. A sentinel pile may also be seen in cases of chronic anal fissure³. Many acute fissures heal, but other enters a recurring cycle of anal pain, constipation and internal anal sphincter spasm⁴. It is currently believed that high maximum resting pressure (MRP) of internal anal sphincter, due to sphincter spasm leads to impaired anodermal blood flow, which results in the formation and persistence of the anal fissure³.

There are various non-surgical and surgical methods of treating this ailment. Glyceryl trinitrate (GTN) topical application is a new entity to treat fissure in ano⁵. There is evidence that nitric oxide is the inhibitory neurotransmitter to the human internal anal sphincter⁶. GTN is an organic nitrate and donates nitric oxide. Topical GTN lowers the maximum resting pressure of internal anal sphincter. This leads to improved anodermal blood flow, which results in relief of symptoms and fissure healing^{7,8}. GTN application

is the least invasive procedure that will be accepted by the patients who are not fit or willing for surgery under anesthesia. So, topical GTN is a healing hope for patients with fissure in ano and may be used as first line of treatment⁹.

Materials & methods

This was a prospective, randomized, case-control study conducted at Surgical Unit-II of Jinnah Hospital, Lahore over a period of one year from 1-2-2005 to 31-2-2006. Fifty patients of all ages and either sex with a clinical diagnosis of fissure in ano (both acute and chronic) were included in the study. Patients with a history of anal pain on defecation for less than two months were labeled as having acute anal fissure while those with a history of more than two months were taken as suffering from "chronic anal fissure". A detailed history and clinical examination was undertaken and the diagnosis was entirely clinical. Information regarding duration of pain, severity of pain (using visual analogue scale for pain, VAS), presence or absence of constipation, streaking on stools or bleeding per rectum, history of previous treatments, any associated disease or systemic illness and the life-style of the patients were recorded. On examination, puckering of the anus, presence of sentinel tag, site of anal fissure, induration of margins of the fissure and its base were inspected. With utmost gentleness, the possibility of a digital rectal examination was evaluated.

Patients with anorectal suppuration, pruritus ani, third degree piles, fistula in ano, inflammatory bowel disease

and anal carcinoma were excluded. Patients with cardiac problems, migraine, sexually transmitted disease and women who were pregnant or considering pregnancy were also excluded from the study. Every patient was informed about the various modalities of treatment available

Patients were randomly divided into two groups. The treatment group (Group-A) was advised 0.2% GTN ointment whereas the control group (Group-B) was prescribed a local anesthetic ointment (Lignocaine Compound® Knoll), 0.2%. A pea-size quantity (0.5ml) of GTN was applied circumferentially to the anal margin and rubbed gently in a clockwise direction for 5-8 seconds as explained and demonstrated to the patient on first visit. Lignocaine ointment for the control group was also applied in the same manner. Caution was advised not to apply the ointment in the anus. The drug was asked to apply twice daily after defecation for a period of 8 weeks and a follow up at the end of first, second and eighth week was carried out. Long term follow up at the end of six months was undertaken to look for any recurrence of the disease. Patients for long-term follow-up were asked to report back to surgical outpatients. Those who failed to report were contacted on telephone and sending them questionnaire at the end of 6 months.

All patients were informed about the potential side effects of both the therapies and their remedial measures. The patients who were unable to comply with the treatment or failed to respond were asked to abandon the ongoing therapy. The treatment group (Group-A) was advised surgery while the control group (Group-B) was offered GTN for 8 weeks and then surgery, if required. Recurrence of the disease in patients previously treated with GTN was managed by another course of GTN for 8 weeks and then surgery if no improvement resulted.

The assessment criteria were subjective and objective. Visual analogue scale for pain was used for subjective assessment. A straight line was drawn between two points taken as 1 and 10. The scale was then equally divided into 10 points. Patients were asked to give 1 point to no anal pain and 10 points for the worst pain they ever experienced. VAS was recorded on first, second and eighth week or until fissure healed. Objectively, the fissure healing was assessed by looking for epithelization at the base of fissure, its length and induration of the margins. Tone of sphincter was judged by attempting a digital rectal examination. Both groups were also analyzed with respect to the range of complications. Headache was regarded as a complication of the therapy if it started within 15 minutes of application of the ointment. Perianal itching was labeled as a complication if it was not present before. Transient incontinence of flatus was described if it remained for two weeks during therapy and orthostatic hypotension was taken as a complication when after using GTN patient felt dizzy on changing posture.

Results

Fifty patients with anal fissure were included in the study. The age range of the patients was between 9 to 58 years with mean age of 31.28 years. Peak incidence of the disease was seen between 30 to 40 years of age (Table 1). Out of 50 patients, 32 were males and 18 patients were females. The male to female ratio was approximately 2:1 (Table 2).

Table 1: Age distribution of patients with anal fissure (n=50)

Age in years	=n	%age
<10	1	2
11-20	9	18
21-30	13	26
31-40	18	36
41-50	6	12
51-60	3	6

Table 2: Sex distribution of patients with anal fissure (n=50)

Sex	=n	%age
Male	32	64
Female	18	36

18 patients presented with acute anal fissure among which 6 were females while 32 patients presented with chronic anal fissure and 20 of them were males (Table 3).

Table 3: Presentation of anal fissure (n=50)

Sex	=n	%age	Grand %age
<i>Acute fissure</i>			
Male	12	24	36
Female	6	12	
<i>Chronic fissure</i>			
Male	20	40	64
Female	12	24	

Patients were randomly divided into two groups. Group A was labeled treatment group and Group B was taken as control. All patients were available for follow up at first and second visit, after one and two weeks respectively. 49 patients (98%) were available for follow up at third visit after six weeks.

77% of patients with acute fissure in Group A showed fissure healing while 44% of patients with acute fissure were benefited in Group B (P=0.015). When the failures of group B were subjected to GTN, 80% of the patients showed healing of their fissures (P=0.0000001). 81% of patients suffering from chronic anal fissure were cured in Group A while 25% of patients showed improvement in Group B (P=0.00000055). When the patients who were not benefited in Group B were subjected to GTN, 66% of them showed fissure healing (P=0.0000001). The mean time taken for fissure healing was 4.1 weeks (min.2, max.8) in Group A while it was 6.7 weeks (min.4, max.11) in Group B.

Table 4: Healing of anal fissure

Fissure	Group A	Group B	P Value*
Acute	77%	44%	<0.05*
Chronic	81%	25%	<0.05

* P ≤ 0.05 Significant, P > 0.05 Not-Significant

Recurrence was seen in 8 patients in Group A (24%) and 3 patients in Group B (38%) at the long-term follow up. Patients previously treated with GTN were prescribed another course of GTN and 4(50%) of them showed fissure healing (Table 9). Recurrence of Group B was also offered GTN and 2 of them showed healing of their anal fissures (67%). All patients who failed to respond to GTN were subjected to surgery.

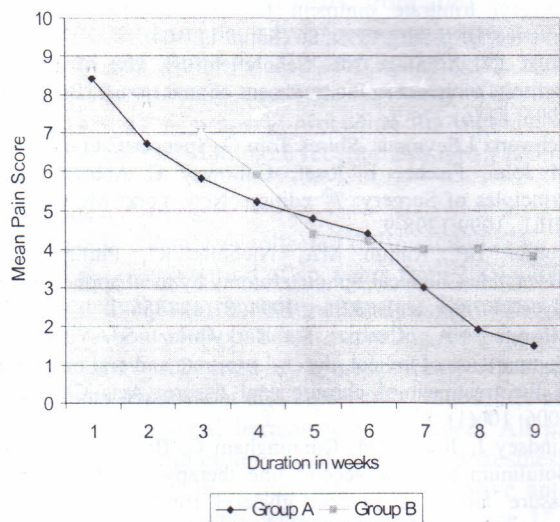
Table 5: Recurrence

Group	Percentage	P Value*
Group A	24%	0.115
Group B	38%	0.115

* P ≤ 0.05 Significant, P > 0.05 Not-Significant

Regarding subjective improvement, VAS for pain fell earlier in Group A (average 8 days) as compared to Group B (average 13 days). This fall in pain scores was maintained in those treated with GTN but pain scores returned to pre-treatment values by 5 weeks in patients with control medicine and they were then subjected to GTN (Fig. 1).

Figure 1: Plot of mean pain score:



The most common complication of GTN ointment was headache. It was mild to moderate and mostly self-limiting. Only 3 patients (12%) had to take simple analgesics like Aspirin especially at the beginning of the therapy. No patient had to stop the treatment because of headache. Perianal itching was seen in both the groups. One patient on treatment with GTN experienced mild orthostatic hypotension but that improved within a week (Table 4).

Table 6: Complications

Symptom	Group A	%	Group B	%	P value*
Headache	17	68	7	28	0.005
Perianal itching	2	8	4	16	0.38
Orthostatic hypotension	1	4	0	0	0.31

* P ≤ 0.05 Significant P > 0.05 Not-Significant

Regarding subjective improvement, VAS for pain fell earlier in Group A (average 8 days) as compared to Group B (average 13 days). This fall in pain scores was maintained in those treated with GTN but pain scores returned to pre-treatment values by 5 weeks in patients with control medicine and they were then subjected to GTN.

Discussion

Anal fissure is a tear in anoderm, which eventually becomes an ulcer. High resting anal pressure because of internal anal sphincter spasm compounded by ischemia of posterior anal commissure leads to its chronicity and increased prevalence at the posterior midline of the anal canal³. Recently, Nitric Oxide (NO) has been identified as the chemical messenger that mediates relaxation of internal anal sphincter(IAS)¹⁰. Keeping this phenomenon in view, exogenous NO donors such as nitroglycerides were introduced for local application at the perianal region as a potential treatment for anal fissure¹¹. This study was carried out to evaluate the effectiveness of local glyceryl trinitrate (GTN) application in cases of anal fissure. Fifty patients presenting to surgical out patients were taken and randomly divided into two groups. One group was offered 0.2% GTN ointment and the other was given Lignocaine ointment (as control) and their results compared. This study confirms the results of other similar studies conducted in our country and abroad as well. A successful treatment of 77% of acute fissures and 81% of chronic fissures was done with GTN as compared to 44% and 25% respectively with control medicine. This percentage of success is close to other national and international research works as they were able to achieve fissure healing in 65-90% of cases^{12,13}.

Age distribution of all cases of anal fissure was close to many other studies where mean age was 36 years^{14,15}. Schwartz¹⁶ recommended the diagnosis of anal fissure as entirely clinical. Presence of an ulcer, increased IAS tone, sentinel tag and a painful or impossible digital rectal examination were the cardinal signs to diagnose a fissure in ano and the same criteria was used here. Anterior anal fissure is seen in less than 10% of cases¹⁶ and a similar low percentage (6%) of patients presented to surgical out patients with anterior fissures.

Most of the studies tried to establish the role of GTN as an exogenous NO donor, which is an important neurotransmitter mediating IAS relaxation. Maximum resting pressure (MRP), predominantly a function of the

smooth muscles of IAS was measured before and 20 minutes after application of 0.2% GTN. Pressure decreased by a mean of 27%¹⁷. Anal manometry and the assessment of squeeze pressure were other methods to evaluate the effectiveness of 0.2% GTN. Manometry showed 20% reduction in MRP and squeeze pressure fell by 11%¹¹. This is parallel to the criteria used in this study where in place of objective evidence improvement in pain and healing of the anal fissure were used to assess the efficacy of GTN. In one study, GTN ointment and oral nifedipine were equally effective in the treatment of chronic anal fissure¹⁸. In another study botulinum toxin was proved to be affective as a second line agent failing GTN treatment¹⁹.

A mean healing time of 4.1 weeks (min 2, max 8) was observed in this study which is compatible to the results achieved by Lund¹⁵ where the healing time was between 2 to 6 weeks. The only drawback in the use of GTN is the complication of headache which was seen in 68% of cases as compared to 72% in a study conducted at St. Mark's Hospital, Middlesex²⁰. A recurrence rate of 24% was observed in patients treated with GTN at the long-term follow up and 50% of them were again benefited with another course of GTN. Lund and Scholefield also had the same findings in two different occasions in 1996¹⁵ and 1997⁵ where they had the recurrence of 20% and 13%.

Conclusion

Anal fissure is a common general surgical problem associated with severe anal pain. There are many surgical and non-surgical methods employed for its treatment. Regarding conservative treatment, use of local anesthetic ointments with good dietary control remained a favorable method for decades, but mostly the disease was recurrent and not cured. It is now concluded from this study that the advent of GTN is a healing hope for patients with anal fissure. It has revolutionized the non-surgical treatment, as it is effective, safe and economical in terms of cure of both acute and chronic anal fissure.

References

1. Abraham A, Ayantunde, Samuel A Debrah. Current concepts in anal fissure: World Journal of Surgery 2006; 30(12): 2246-60.
2. Lund JN, Scholefield JH. Aetiology and treatment of anal fissure: Br J Surg 1996; 83: 1335-44.
3. Schouten WR, Briel JW, Auwerda JJA, De Graaf EJR. Ischaemic nature of anal fissure. Br J Surg 1996; 83: 63-5.
4. Wakefield Simon, Shorthouse Andrew. Anal fissure: Surgery International 1998; 41: 9555-6.
5. Philips RKS. Progress in the management of anal disorders. In: Taylor I, Jashon CD. eds. Recent Advances in Surgery (Vol. 22) London: Churchill Livingstone; 1999: 123-34.
6. Watson SJ, Kamm MA, Nicholls RJ, Phillips RKS. Topical glyceryl trinitrate in the treatment of chronic anal fissure. Br J Surg 1996; 83: 771-5.
7. Lund JN, Scholefield JH. Internal sphincter spasm in anal fissure. Br J Surg 1997; 84: 1723-4.
8. Amin S, Lund J, Jonas M, Barrett D et al. The pharmacokinetics of glyceryl trinitrate following application to anal canal. Br J Surg 1999; 86(suppl. 1): 105.
9. Utzig MJ, Kroesen AJ, Buhr HJ. Concepts in pathogenesis and treatment of chronic anal fissure; a review of the literature. Am J Gastroentrol 2003; 98: 968-74.
10. Schouten WR, Briel JW, Auwerda JJ, Boerma MO. Anal fissure – New concepts in pathogenesis and treatment. Scand J Gastroenterol – Suppl 1996; 218: 78-81.
11. Thornton MJ, Kennedy ML, King DW. Manometric effect of topical glyceryl trinitrate and its impact on chronic anal fissure healing. Dis Colon Rectum 2005; 48(6): 1027-12.
12. Carepeti EA, Kamm MA, McDonald PJ, Chadwick SJ, Melvilled. Randomized controlled trial shows that glyceryl trinitrate heals anal fissure, higher doses are not more effective and there is a high recurrence rate. Gut 1999; 44: 727-30.
13. Ward DI, Miller BJ, Schache DJ, Cohen JR, Theile. The use of glyceryl trinitrate paste in the treatment of acute and chronic anal fissure. Aust NZ J Surg 2000; 70:19-21.
14. Wemyss Holden, Haslam P, Hemingway D. The efficacy of glyceryl trinitrate ointment for anal fissure in clinical practice. Br. J Surg 1999; 86 (Suppl 1): 104.
15. Lund JN, Armitage NC, Scholefield JH. Use of glyceryl trinitrate ointment in the treatment of anal fissure. Br. J Surg 1996; 83 (6):776-7.
16. Schwartz I Seymour, Shires Tom G, Spencer C Frank, Daly M John, Fischer E Josef, Galloway C Anbregy. eds. Principles of Surgery. 7th edition. New York: Mc GRAW-HILL, 1999:1298-9.
17. Lord BP, Kamm MA, Nicholls RJ, Phillips RK. Reversible Chemical Sphincterotomy by local application of glyceryl trinitrate. Br J Surg 1994; 81(a):1386-9.
18. Mustafa NA, Cenqiz S, Turkyilmaz S, Yucel Y. Comparison of topical glyceryl trinitrate and oral nifedipine in the treatment of chronic anal fissure: Acta Chir Belg 2006; 106(1): 55-8.
19. Lindsey I, Jones OM, Cunningham C, Bruce D, Neil M. Botulinum toxin as second line therapy for chronic anal fissure failing .2 percent glyceryl trinitrate. Dis Colon Rectum 2003; 46(3): 361-6.
20. Sinnatamby S Chummy. Last's Anatomy – Regional and applied. 10th ed. London: Churchill Livingstone, 1999: 305-8.