

## Case Report

### Duodenal Perforation in a Patient with Dengue Fever –A Rare Entity

Huzefa Jibril<sup>1</sup>, Iffat Khanum<sup>2</sup>

<sup>1,2</sup>Department of Medicine, Aga Khan University Hospital, Karachi, Pakistan

#### Abstract

A 37-year-old gentleman presented to the emergency with a history of high-grade fever for 2 days and abdominal pain for one day. On arrival at the emergency department, he was hypotensive and tachycardic, while on abdominal examination he had generalized abdominal tenderness. He was started on fluid resuscitation with intravenous crystalloids. The initial impression was of an acute abdomen. The Abdominal X-ray showed air under the diaphragm. He was rushed to the operating room and underwent an emergency laparotomy that revealed a duodenal perforation for which he underwent Graham's patch repair and washout. No obvious cause was identified. He had low platelets for which Dengue NS-1 antigen was sent that came positive. Post-procedure he recovered and was discharged home. To our knowledge, this is the first case in which dengue fever associated with a duodenal perforation is being reported. It is the first case of gastrointestinal perforation in a patient with Dengue Fever to be reported outside of India. In endemic regions, clinicians must recognize such atypical manifestations.

**Corresponding Author** | Dr Huzefa Jibril, Resident, Internal Medicine, Department of Medicine, Aga Khan University Hospital, Karachi, Pakistan **Email:** huzefa.jibril@aku.edu

**Key words:** dengue fever, intestinal perforation, acute abdomen

#### Introduction:

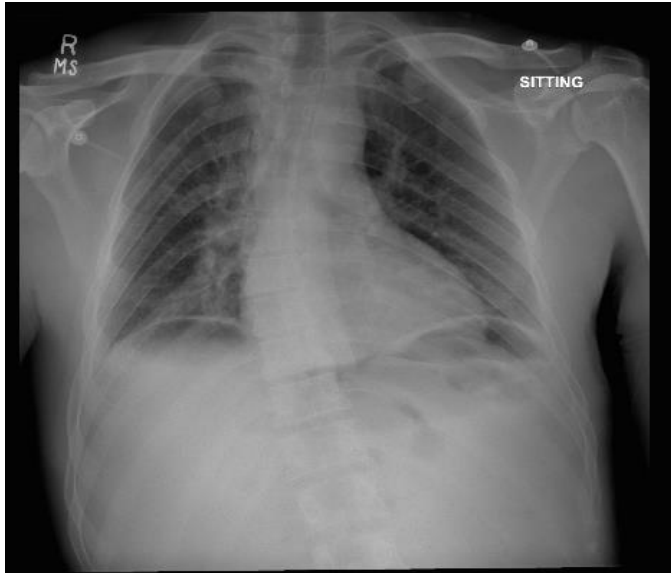
A Flavivirus that is spread mainly via the mosquitoes *Aedes aegypti* and *Aedes albopictus*. The Dengue virus is comprised of 5 serotypes<sup>1</sup> and is a common cause of vector-borne disease worldwide. It can cause a spectrum of disease that ranges from mild self-limiting fever to the potential life-threatening Dengue Hemorrhagic Fever presenting with bleeding and shock. Classically it manifests as fever, headache, rash, myalgia, and arthralgia, now increasingly being associated with atypical manifestations with abdominal, neurological, and cardiovascular system involvement. Gastrointestinal perforation is also now emerging as a potential complication of Dengue fever. Cases of dengue fever associated with gastric, jejunal, ileal, and appendicular perforation have been reported in the literature<sup>2-6</sup>. We present a case in which Dengue was associated with duodenal perforation. To our knowledge, this is the first case of such kind to be reported.

#### Case Presentation:

A 37-year-old gentleman presented to the emergency with a history of fever for 2 days and abdominal pain for one day. Fever was documented as 104 degrees Fahrenheit and associated with rigors and chills. It was intermittent and relieved with medications. Generalized body aches were also present. The next day he developed abdominal pain initially in the epigastric region with no associated nausea and vomiting. His abdominal pain then became generalized and increased in intensity for which he came to the emergency department. He has no history of Non-Steroidal Anti-inflammatory Drug (NSAID) use, history of peptic ulcer disease, or other co-morbidities. On arrival at the ER, he was hypotensive and tachycardic, while on abdominal examination he had generalized abdominal tenderness. He was started on fluid resuscitation with intravenous crystalloids. The initial impression was of an acute abdomen.

His abdominal X-ray was done (Figure 1.0) and revealed air under the diaphragm after which he was rushed to the operating room for emergency laparotomy with suspicion of bowel perforation. Perioperative, there was a 5-6 mm perforation on the anterior wall of the first part of the duodenum. He thus underwent Graham's patch repair and washout.

Initial Complete Blood Count (CBC) had shown a Hemoglobin (Hb) of 15.1 mg/dl, Total Leucocyte



**Figure 1.0** Abdominal X ray showing air under the diaphragm

Count (TLC) of  $3.8 \times 10^9/L$ , and platelet count of  $105 \times 10^9/L$ . His liver function tests were normal. His procalcitonin was 70.84 ng/mL. Postoperatively his CBC was monitored and platelet count gradually dropped and Dengue NS1 antigen was sent and came out to be positive.

He was kept on intravenous fluid hydration with crystalloids. His platelet count dropped to as low as  $12 \times 10^9/L$ . He was transfused 4 platelets during hospital admission. He was transferred to internal medicine service during the hospital stay for management of Dengue due to progressively decreasing platelet count, then shifted back to general surgery service as his platelets improved. His blood, stool, and urine culture were negative, but peritoneal fluid culture grew *Pseudomonas Stutzeri* and treated with I/V Imipenem according to culture sensitivity. His clinical condition improved, became afebrile, platelet count normalized and he was sent home after a 10-day hospital stay.

He came for a follow-up visit 2 days after discharge to the infectious disease clinic and 7 days later to the general surgery clinic and did not develop any complications. 34 days post-discharge, he presented to the emergency room with complaints of abdominal pain in the left upper quadrant region. He was discharged home on oral analgesics from the emergency room following review by the general surgery team. He came to the general surgery clinic the next day for review and again after 3 weeks with no further complications noted. He has remained healthy since then.

### Discussion:

The leading cause of duodenal perforation is peptic ulcer disease usually due to NSAID use or H.Pylori infection but other causes include duodenal ischemia, duodenal diverticula, infectious diseases, and autoimmune conditions<sup>7</sup>. The presence of thrombocytopenia prompted a Dengue NS1 antigen to be sent which came out to be positive. Malaria, Scrub Typhus, and other Rickettsial infections, meningococci, Leptospira, and certain other viruses other than Dengue may also present as fever with thrombocytopenia<sup>8</sup>. However, it is not necessary that patients with Dengue fever always have low platelets especially in the early phase of the disease. Dengue should be a consideration in the mind of clinicians when patients present with acute febrile illness with or without thrombocytopenia in endemic regions.

The reported cases of gastrointestinal perforation in patients with Dengue fever has been summarized in table 1.0.

The World Health Organization (WHO) describes the course of illness due to the Dengue virus in 3 phases namely, the febrile phase, the critical phase, and the recovery phase. The critical phase occurring as the fever settles is when complications tend to arise due to plasma leakage, hemorrhage, or organ impairment. Management of Dengue according to the WHO guidelines consists of classifying cases into three categories; namely Dengue without warning signs, Dengue with warning signs, and Severe Dengue. Patients without warning signs who have adequate oral intake and without comorbid illness can be sent home. Patients without warning signs but with comorbid illness and those with warning signs such as abdominal

**Table 1.0** Reported cases of intestinal perforation in Dengue Fever

Serial Number	Year of Publication	Reported by	Age of patient (years)	Gender	Site of Perforation	Intervention	Outcome	Country
1	2014	Jain AC et al <sup>3</sup>	64	Female	Jejunum	Exploratory Laparotomy	Left against medical advice due to financial issues	India
2	2014	Desai J et al <sup>5</sup>	Not available (3 patients)	Not available	Appendix	Exploratory Laparotomy, Exploratory Laparotomy, Appendicectomy	Discharged (All 3)	India
3	2015	Mandhane N et al <sup>2</sup>	17	Male	Stomach	Exploratory Laparotomy	Discharged	India
4	2016	Kumar P et al <sup>4</sup>	10,7 (2 patients)	Female, Male	Ileum	Exploratory Laparotomy	Discharged (Both)	India
5	2019	Pillai M, Rao G <sup>6</sup>	12	Female	Stomach	Emergency Laparotomy + Graham's Omentoplasty	Not reported	India
6	Present Case	Jibril H, Khanum I	37	Male	Duodenum	Emergency Laparotomy + Graham's Patch repair and washout	Discharged	Pakistan

pain, persistent vomiting, and an increase in hematocrit should be hospitalized. Those with warning signs should be started on I/V fluid resuscitation. Patients with signs of severe Dengue such as severe bleeding, severe organ impairment, or severe plasma leakage must also be hospitalized and require more aggressive fluid resuscitation<sup>9</sup>. In our case, the patient presented as a case of Dengue with warning signs.

How gastric and intestinal perforation develops in patients with Dengue Fever is still unclear but elevated levels of I-FABP which is a marker of intestinal mucosal injury have been demonstrated<sup>10</sup>. How this occurs though and whether it is a possible mechanism for intestinal perforation though is still a mystery yet to be solved.

Being the first case of Dengue fever associated with a

duodenal perforation to be reported is a limitation but previous reports of the virus being associated with perforations in other parts of the gastrointestinal tract strengthen our conclusion.

#### References:

1. Mustafa MS, Rasotgi V, Jain S, Gupta V. Discovery of fifth serotype of dengue virus (DENV-5): A new public health dilemma in dengue control. Med J. Armed Forces India. 2015;71(1):67-70.
2. Mandhane N, Ansari S, Shaikh T, Deolekar S, Mahadik A, Karandikar S. Dengue presenting as gastric perforation: first case reported till date. Int J Res Med Sci. 2015;3(8):2139-40.
3. Jain AC, Viswanath S. Multiple jejunal perforations in dengue. Int J Adv Med. 2014; 1(1):153-4.

4. Kumar P, Gupta A, Pandey A, Kureel SN. Ileal perforation associated with dengue in the paediatric age group: an uncommon presentation. *BMJ Case Rep.* 2016;2016(1):bcr216257.
5. Desai G, Gupta S, Ali S, Aggarwal L, Thomas S. Appendicular perforation in dengue fever: our experience. *Asian Pac. J. Trop. Dis.* 2014;4(2): 571-2
6. Pillai M, Rao G. Peptic perforation in paediatric case of dengue: rare presentation. *Int. Surg. J.* 2019; 6(9):3418-20.
7. Ansari D, Torén W, Lindberg S, Pyrhönen HS, Andersson R. Diagnosis and management of duodenal perforations: a narrative review. *Scand. J. Gastroenterol.* 2019;54(8):939-44.
8. Parikh F. Infections and Thrombocytopenia. *J Assoc Physicians India.* 2016; 64(2):11-12.
9. World Health Organization, UNICEF. Handbook for clinical management of dengue. 2012.
10. Vejchapipat P, Theamboonlers A, Chongsrisawat V, Poovorawan Y. An evidence of intestinal mucosal injury in dengue infection. *SE ASIAN J TROP MED.* 2006; 37(1):79.