

Research Article

Fornix Deepening by Using Amniotic Membrane Transplant

Qirat Qurban¹, Zeeshan Kamil², Khalid Mahmood³

¹⁻³ *Khalid Eye Clinic, Karachi*

Abstract:

Objective: To assess the cosmetic outcomes of fornix deepening by using Amniotic membrane transplant in anophthalmic sockets in terms of good retention of ocular prosthesis.

Methods: This interventional case series was carried out at Khalid eye clinic, Karachi during the period of March 2019 to August 2019. Twenty-five patients belonging to either gender between the ages of 20 to 50 years were included, having anophthalmic sockets with fornix deformities incapable of retaining ocular prosthesis due to variable causes such as cicatrization, symblepharon, cyst, or poor conjunctival suturing technique following evisceration or enucleation. Amniotic membrane was transplanted following the division of bands, excision of cyst and release of adhesions. Pre and post fornix measurements were done and each patient was followed for a duration of six months after the operation to observe the cosmetic appearance and retention of ocular prosthesis.

Results: Good cosmetic outcome with retention of ocular prosthesis was achieved in twenty-three (92%) cases, whereas two (8%) cases ended up in failure despite multiple surgeries. The mean pre-operative lower fornix depth was 3.8 ± 1.23 mm, which improved to 8.9 ± 1.10 mm (p-value < 0.001). None of the patients developed any infection or graft rejection.

Conclusion: Fornix reconstruction in an anophthalmic socket is a challenging task, but a good cosmetic outcome can be achieved using amniotic membrane transplantation together with good oculoplastic surgical expertise.

Corresponding Author | Dr. Qirat Qurban, Consultant Ophthalmologist, Khalid Eye Clinic, Karachi

Email: qirat_89@hotmail.com

Key words: Amniotic membrane transplant, Anophthalmic socket, Fornix reconstruction.

Introduction:

The incapability to retain an ocular prosthesis in an aesthetically concerned world is a sensitively overwhelming dilemma for patients¹. The secondary healing of the conjunctiva in an anophthalmic socket leads to a dysfunctional conjunctival scarring causing insufficient fornical depth for the retention of ocular prosthesis along with severe anatomical, functional and cosmetic impairment as well as adversely affecting the psyche, social and personal well-being of an individual. The primary aim of socket reconstruction is to help the patient retain an ocular prosthesis that would imitate the normal fellow eye as much as possible to maintain cosmetic appeal and prevent psychological disturbance in the

patient². A well-formed inferior fornix with adequate conjunctival length and depth is essential for the withholding of the ocular prosthesis within the anophthalmic socket³. Increasing the surface of fornical conjunctiva with the application of fornix deepening conjunctival sutures through the periosteum, buccal mucosal grafts, auricular cartilage grafts and amniotic membrane grafts can achieve this⁴.

Amniotic membrane (AM) has a similar source as the fetus and is obtained from prospective donors who are negative for communicable diseases, undergoing Caesarean section. Histologically, it comprises of a single epithelial layer, a thick basement membrane and an

avascular stroma⁵. It modulates adult wound healing via anti-inflammatory, anti-scarring and anti-angiogenic properties as testified by studies done previously, which have shown that the amniotic membrane promotes adult wound healing and regeneration with minimal inflammation and scarring mediated by growth factors such as cytokines, chemokines and nonprotein mediators⁶. Amniotic membrane has an exclusive amalgamation of properties, including the facilitation of migration of epithelial cells, strengthening basal cellular adhesions and the encouragement of epithelial differentiation. After proper processing and preservation, the semitransparent and durable amniotic membrane has been successfully used as a surgical graft for a broad range of ophthalmic complications⁷.

Owing to the abundant availability without sacrificing the patients' own tissues, trouble-free harvesting, minimal shrinking, resistance to contraction and less healing time with no donor site morbidity, makes amniotic membrane a suitable option for the formation of shallow inferior fornix in a contracted anophthalmic socket to evade inferior lid entropion⁸.

Keeping this in mind, the rationale behind this study was to assess the aesthetic outcomes after fornix deepening via amniotic membrane transplant in anophthalmic sockets followed by good retention of ocular prosthesis.

Methods:

This case series was carried out at Khalid eye clinic, Karachi, from March 2019 to August 2019. Twenty-five patients belonging of either gender with an age range from 20 to 50 years and having anophthalmic sockets and incapable of retaining ocular prosthesis due to variable causes such as cicatrization, symblepharon, cyst, or poor conjunctival suturing technique following evisceration or enucleation were included. Ethical review committee approval was taken (Ref #: ERC-10-20) and informed verbal consent was taken from each patient. All the procedures were performed under general anesthesia by a single oculoplastic surgeon. Before starting the surgery, pre-operative central forniceal depth was measured among all the patients using a thin dimensioned non-invasive, round-edge fine plastic ruler having millimeter markings. The sub-conjunctival fibrous scar tissue was incised using 11 no. blade and dissected using Wescott scissors to separate the bands and libera-

tion of the forniceal adhesions. The required pre-operative central fornix depth was measured and compared with the normal fellow eye in all the patients. Amniotic membrane graft, varying between 5mm to 15mm depending upon the size needed, with the epithelial side facing upwards was placed over the bare tissue and sutured with 6-0 Vicryl along two third of the entire eyelid thickness. (Picture 1) Following which, adequately sized conformers as per the individual patient forniceal requirement were placed in the fornices to avert postoperative scarring and fibrosis in all the patients. Both the upper lids and lower lids were sutured and adhered to the contra lateral side onto the forehead and cheeks with surgical tape. The post-surgical treatment comprised of oral antibiotics and analgesics for 7 days along with antibiotic steroid eye drops and lubricating ointment for 2 weeks, followed by gradual tapering. The lubricating eye drops were continued for the next 3-4 months with placement ad regular cleaning of the conformers for 6-8 weeks. Three months after the procedure, patients were advised ocular prosthesis following measurement of post-operative central forniceal depth in both eyes. The total follow-up period for this study was six months during which the patients were observed for cosmetic appearance, maintenance of forniceal depth, retention of ocular prosthesis and presence of any complications. The surgical success was taken as the anatomical reconstruction of a deep fornix together with cosmetically appealing placement of the ocular prosthesis with the patient wearing and holding the ocular prosthesis in position at ease under all conditions with complete and comfortable eyelid closure. The criteria for good cosmetic accomplishment was defined as anatomical re-establishment of a deep fornix with ocular prosthesis retention, whereas fair cosmetic accomplishment was defined as the focal reappearance of scarred tissue along with symblepharon but enough to hold the ocular prosthesis. Recurrence of contracture with inability to retain the ocular prosthesis; along with graft rejection or infection were defined as failure.

Data was analyzed using IBM SPSS version 25. Mean \pm standard deviation of continuous variables was computed while frequencies and percentages were calculated for others. Paired sample t- test was applied to assess the change in lower fornix depth after surgery. The level of significance was kept at 0.05.

Table 1: *Patient-wise results*

Patient	Age (years)	Gender	Eye	Pre-operative forniceal depth (mm)	Post-operative forniceal depth (mm)	Outcome
1	43	Male	Right	2.7	9.8	Success
2	41	Male	Right	4.9	9.1	Success
3	39	Male	Right	2.9	8.4	Success
4	43	Male	Right	3.9	9.8	Success
5	44	Male	Right	5.3	9.6	Success
6	42	Male	Right	3.8	9.8	Success
7	39	Male	Right	2.2	9.4	Success
8	32	Male	Right	3.4	8.8	Success
9	40	Male	Left	2.5	5.3	Fail
10	48	Male	Right	2.7	9.7	Success
11	42	Male	Right	4.8	9.6	Success
12	45	Female	Left	3.7	9.7	Success
13	41	Female	Left	5.7	7.8	Success
14	41	Female	Left	4.9	9.7	Success
15	43	Male	Right	2.7	8.4	Success
16	42	Male	Right	2.9	9.5	Success
17	40	Female	Left	2.5	9.7	Success
18	41	Male	Left	5.0	6.9	Fail
19	43	Male	Left	2.5	9.8	Success
20	48	Female	Left	5.9	8.7	Success
21	41	Male	Right	4.7	7.8	Success
22	45	Female	Left	2.8	9.7	Success
23	45	Female	Right	3.1	9.5	Success
24	40	Male	Left	2.5	8.3	Success
25	39	Female	Right	5.8	8.9	Success

Results:

The mean follow-up duration of this study was 182 ± 6.2 days and included seventeen (68%) males and eight (32%) females (total of 25 patients; median = 42.0 years; interquartile range (25-75%) = 3.50 years). Fifteen (60%) out of twenty-five had right eye involvement whereas, the remaining ten (40%) had involvement of the left eye. Sufficient forniceal depth with good retention of ocular prosthesis was achieved in twenty-three (92%) patients. (Picture 2) The mean pre-operative lower fornix depth was 3.8 ± 1.23 mm, which improved to 8.9 ± 1.10 mm post operatively (p -value < 0.001). Due to prior history of alkali burns, two (8%) out of the twenty-five patients resulted in failure of formation of an adequate forniceal depth despite multiple attempts resulting in a cosmetically poor

outcome. None of the patients ended up with infection or graft failure.

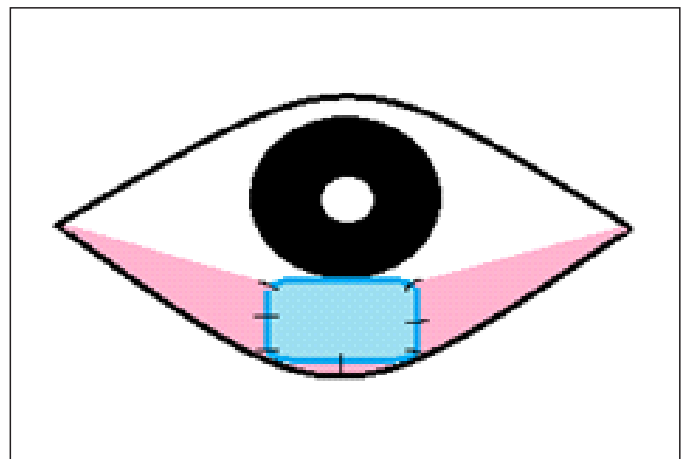
**Figure 1:** *Schematic diagram showing placement of amniotic membrane graft.*

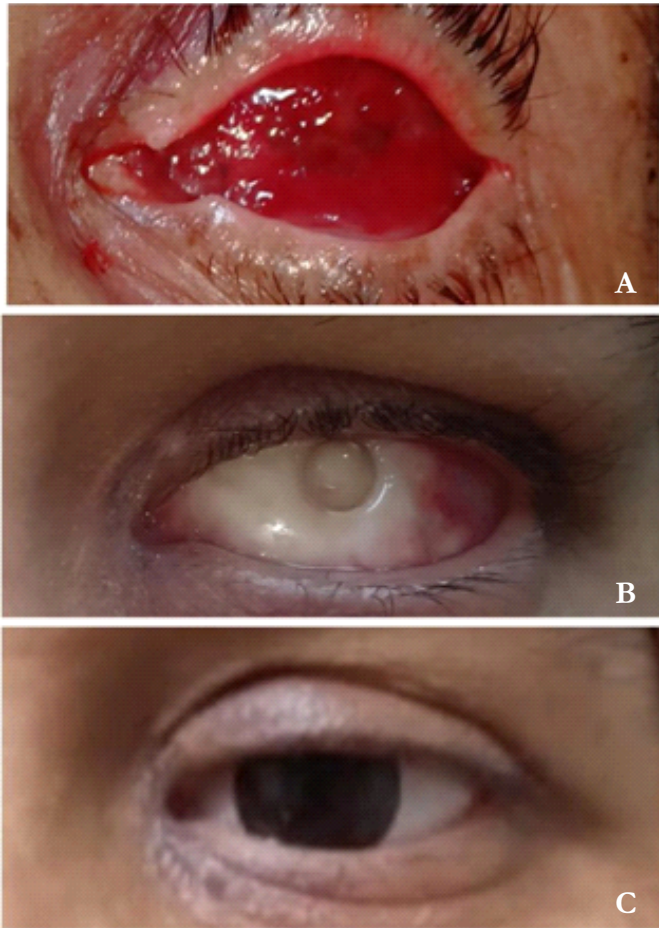

Figure 2 (A, B, C): Pre and post-operative pictures showing anophthalmic contracted socket, conformer in the newly formed fornix and ocular prosthesis in place with good aesthetic outcome.

Discussion:

In anophthalmic sockets, due to the absence of a globe, the inferior orbital fat migrates anteriorly along with the elevation of the inferior rectus muscle and lower lid retractors. This results in prolapsed forniceal conjunctiva causing anterior turning of the inferior border of the prosthesis⁹. The treatment of fornix deformity is aimed at fundamental aetiology. Compared to an anophthalmic socket, the contracted socket is characterized by insufficient conjunctival tissue with cicatrization of the lower fornix, hence requiring additional tissue grafting along with deepening of the inferior fornix¹⁰. As mentioned previously, all the grafting materials, with the exception of amniotic membrane, come with a set of major drawbacks of requiring additional surgical skills, manipulation and instrumentation together with longer duration which may be troublesome if the patient needs repeated surgeries in order to preserve the socket sufficiently for the ocular prosthesis¹¹. Hence, the use

of amniotic membrane grafts is found to be superior. Multiple techniques have been described for the fixation of amniotic membrane such as using interrupted suturing, continuous suturing, or a combination of these techniques. Recently, sutureless techniques using tissue adhesives have also been introduced and tested in different studies^{12,13}. In this study we used amniotic membrane grafts for deepening of the shallow lower fornix in 25 cases. Out of the twenty-five patients, seventeen (68%) were males, and eight (32%) were females. All patients underwent fornix deepening using amniotic membrane transplant under general anesthesia. Contrary to this, a study was conducted using central split-medium thickness skin graft for the formation of deep fornix in contracted anophthalmic sockets and demonstrated that 38.9% of the participants resulted in lagophthalmos with 5.6% having entropion¹⁴. This was not found in this current study since amniotic membrane grafts were used instead of the skin grafts. Another study was done which used silicone spheres to expand, widen and deepen the severe contracted conjunctival sacs among five patients and found them to be a good surgical substitute for contracted anophthalmic socket repair with sphere loss and recurrence of cicatrization in one patient¹⁵. In this study, in order to prevent scarring and fibrosis, conformers were placed in all the patients. A subciliary approach was used by Lee et al, in patients with shallow, anophthalmic inferior fornices with enough conjunctiva having lax forniceal attachment to the underlying tissue resulting in shallow fornices, to fasten the conjunctival fornix with the periosteum posterior to the inferior orbital rim¹⁶. In the present study, conjunctival approach was used for the formation of adequately deep fornix. Another study using a similar approach as this study, achieved 80% success rate following fornix reconstruction with the retention of the conformer¹⁷. This was comparable to the results of this study where 23 out of the 25 patients (92%) achieved sufficient forniceal depth with good retention of ocular prosthesis. A failure rate of 11.11% was reported in a study in the patients having large symblepharon formation⁸. The present study failed to achieve good cosmetic retention in 8% despite undergoing multiple attempts of fornix deepening due to prior chemical burns. Recently, a novel technique using cryopreserved ultra-thick human amniotic membrane for the

reconstruction of contracted anophthalmic sockets was performed among three females and showed excellent results with a good prosthetic fit at the conclusion of follow up duration with no subsequent complications¹⁸.

Conclusion:

Amniotic membrane transplant is an innovative alternative for fornix deepening in anophthalmic sockets. If done by a skilled surgical hand, it is a safe, simple and effective surgical technique having a successful aesthetic outcome with good retention of ocular prosthesis.

Study limitation:

This study was limited in terms of having a small sample size and short duration of study. Further large-scale trials are required to establish the cosmetic outcomes following the application of amniotic membrane graft for fornix deepening.

Ethical Approval: Given

Conflict of Interest: The authors declare no conflict of interest.

Funding Source: None

References:

1. Goiato MC, De Caxias FP, Santos DM. Quality of life living with ocular prosthesis, *Expert Rev Ophthalmol* 2018;13(4):187-189.
2. Ibrahim M, Abdelaziz S. Shallow Inferior Conjunctival Fornix in Contracted Socket and Anophthalmic Socket Syndrome: A Novel Technique to Deepen the Fornix Using Fascia Lata Strips. *Jour of Ophth*. 2016;19(7):1-6.
3. Dasgupta D, Das K, Singh R. Rehabilitation of an ocular defect with intraorbital implant and custom-made prosthesis using digital photography and gridded spectacle. *J Indian Pros-thodont Soc*. 2019;19(4):266-71.
4. Kheirkhah A, Blanco G, Casas V, Hayashida Y, Raju VK, Tseng SC. Surgical strategies for fornix reconstruction based on symblepharon severity. *Am J Ophthalmol*. 2008;146(2):266-275.
5. Makhlof M. Characterization of the Human Amniotic Membrane: Histological, Immunohistochemical and Ultrastructural Studies. *Life Sci J*. 2013;10(4):3701-3710.
6. Malhotra C, Jain AK. Human amniotic membrane transplantation: Different modalities of its use in ophthalmology. *World J Transplant*. 2014;4(2):111-121.
7. Jirsova K, Jones GLA. Amniotic membrane in ophthalmology: properties, preparation, storage and indications for grafting—a review. *Cell Tissue Bank*. 2017;18(6):193–204.
8. Thatte S, Jain J. Fornix Reconstruction with Amniotic Membrane Transplantation: A Cosmetic Remedy for Blind Patients. *J Ophthalmic Vis Res*. 2016;11(2):193-197.
9. Dhillon H K, Raj A, Dhasmana R, Bahadur H. Anophthalmic socket- A cosmetic dilemma. *IP Int J Ocul Oncol Oculoplasty*. 2018;4(1):6-11.
10. Serin D, Karslioglu S, Akbaba M, Buttanri IB, Fazil K. Clinical Evaluation of 188 Patients with Contracted Socket. *Surgery Curr Res*. 2014;4(2):203.
11. Sangwan VS, Burman S, Tejwani S, Mahesh SP, Murthy R. Amniotic membrane transplantation: A review of current indications in the management of ophthalmic disorders. *Indian J Ophthalmol*. 2007;55(7):251-260.
12. Panda A, Kumar S, Kumar A, Bansal R, Bhartiya S. Fibrin glue in ophthalmology. *Indian J Ophthalmol*. 2009;57(5):371-379.
13. Liu BQ, Wang ZC, Liu LM. Sutureless fixation of amniotic membrane patch as a therapeutic contact lens by using a polymethyl methacrylate ring and fibrin sealant in a rabbit model. *Cornea*. 2008;27(1):74-79.
14. Hassan SA, Alicia G, Rajiv K, Ossama A, Schellini S. Deepening Fornix Technique Using Central Split-Medium Thickness Skin Graft to Treat Contracted Anophthalmic Sockets. *J Craniofac Surg*. 2018;29(6):1607-1611.
15. Lukáts O. Contracted anophthalmic socket repair. *Orbit*. 2002;21(4):125-130.
16. Lee TS, Hwang SJ, Oh JH. Forniceal reconstruction through subciliary approach in a patient with shallow inferior fornix. *J Korean Ophthalmol Soc*. 2007;48(6):611-617.
17. Poonyathalang A, Preechawat P, Pomsathit J, Mahaisaviriya P. Reconstruction of contracted eye socket with amniotic membrane graft. *Ophthalm Plast Reconstr Surg*. 2005;21(5): 359–362.
18. Slentz, D, Nelson C. Novel Use of Cryopreserved Ultra-thick Human Amniotic Membrane for Management of Anophthalmic Socket Contracture. *Ophthalm Plast Reconstr Surg*. 2019;35(2):193-6.