

Case Report

Ischemic Colitis induced by COVID-19: A Case Report

Unaib Rabbani¹, Abdulrhman Aldukhayel², Abdulhamid F Alresheedi³

¹Senior Registrar, Family Medicine Academy, Qassim Health Cluster, Kingdom of Saudi Arabia; ²Associate Professor, Department of Family Community Medicine, College of Medicine, Qassim University; ³Consultant Intensive Care Unit, King Fahad Specialist Hospital Buraidah, Kingdom of Saudi Arabia

Abstract

COVID-19 has been associated with coagulation disorders which add further to the morbidity and mortality caused by the disease itself. Ischemic colitis can result from hypercoagulable states. In this report we present a rare case of ischemic colitis induced by COVID-19 in 27-year-old male. Patient presented with severe generalized abdominal pain. CT abdomen showed filling defects, absent enhancement indicating venous bowel ischemia. CT-angiograph revealed complete thrombosis of portal, splenic, superior and inferior mesenteric veins. Patient was shifted to intensive care unit and kept nothing per orum. He was given Heparin, tramadol and paracetamol intravenously. COVID-19 Reverse transcription-polymerase chain reaction (RT-PCR) was positive. He was then given Favipiravir through nasogastric (NG) tube. On 4th day NG was removed and patient was subsequently discharged on 9th day. COVID-19 may lead to hypercoagulable states and gastrointestinal complications. COVID-19 patients with gastrointestinal symptoms should be evaluated carefully for possible ischemia.

Corresponding Author | Dr. Unaib Rabbani, Family Medicine Academy, Qassim Health Cluster, Kingdom of Saudi Arabia **Email:** rabbaniunaib@gmail.com

Key Words: COVID-19, Complication, Gastrointestinal, Ischemic Colitis

Introduction:

Corona Virus Disease-2019 (COVID-19) being highly contagious spread across the globe in short span of time and has affected millions of people across the globe. Fever, cough and dyspnea are common symptoms¹. COVID-19 patients have also been reported to present with gastrointestinal symptoms. Blood coagulopathy with increased levels of D dimer and fibrinogen has also been reported which may lead to ischemic colitis where blood supply of colon is blocked due to blood coagulation in the arteries². Such unusual manifestations are likely to be missed if not evaluated properly and can result in poor prognosis. Here we report a rare case of ischemic colitis from Saudi Arabia.

Case Report:

A 27-year-old Sudanese non-smoker single male presented to emergency department of King Fahad Specialist hospital Buraidah, Qassim with complaints of generalized severe abdominal pain for five days in

September 2020. The pain was stabbing in nature, non-radiating and not related to food intake. The pain was also associated with nausea and vomiting on the day of admission. There was no history of fever, hemoptysis, hematemesis, melena, headache or contact with a sick person. Past medical and surgical history was unremarkable and there was no family history of blood disorders, venous thrombosis or autoimmune disease. Patient was not taking any medication before presenting to the hospital. He was a storekeeper in warehouse, living with his family and had no addiction history. Informed consent was obtained from the patient for publication and no photograph or personal identifiers were included or obtained for this case report.

At the time of presentation, he was conscious and well oriented and afebrile. His pulse was 110 beats per minute, blood pressure 121/88 mmHg and sPO₂ 96%. Systemic examination was unremarkable for chest, cardiovascular and central nervous system and there was

no lower limb edema. Abdomen was tense and there was guarding and tenderness all over the abdomen. Bowel sounds were audible. On the day of admission his total WBC count was raised $13.1 \times 10^3/\mu\text{L}$ ($4-10 \times 10^3/\mu\text{L}$) with Neutrophils 11.3% (1.8 – 7.7). Hemoglobin was 15.4 g/d: (13-17 g/dL) and MCV was 90.5 fL (83-100 fL). Platelets were $156 \times 10^3/\mu\text{L}$ (150-450 μL). Biochemistry showed raised creatinine kinase (CK) 1884U/L (20-190U/L). Serum albumin was 22.6 g/L (34-50 g/L). ALP was 29 U/L (50-140 U/L) and ALT was 42U/L (5-56U/L). Total Bilirubin was 6.6 $\mu\text{mol/L}$ (0-21 $\mu\text{mol/L}$) while direct Bilirubin was 6.4 $\mu\text{mol/L}$ (0-5 $\mu\text{mol/L}$). Serum Potassium was 3.3 mmol/L (3.5-5.3 mmol/L) and LDH was 376 U/L (125-220 U/L). PT was found to be raised 16.6 seconds (13.3 -15.8 seconds) and INR was 1.33% (0.9 – 1.3%). Chest radiograph showed non-homogenous infiltration in the left lung. ECG was unremarkable. Nasopharyngeal swab for COVID-19 was sent to the laboratory.

CT scan of abdomen revealed extensive filling defects with in the portal, splenic, superior mesenteric and inferior mesenteric veins. There was bowel wall thickening and absent enhancement and target sign representing venous bowel ischemia (Figure 1). No sign of bowel perforation was observed. Multiple hypodense splenic lesions were seen indicating splenic infarcts. Abdominal aorta and its major branches were patent. CT angiogram showed complete thrombosis of portal, splenic,

Figure Legends

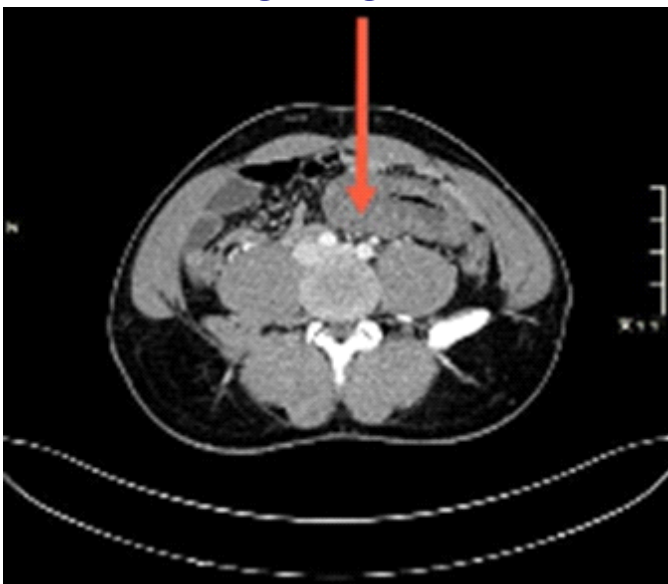


Figure 1: CT image of abdomen showing bowel wall thickening indicating ischemia

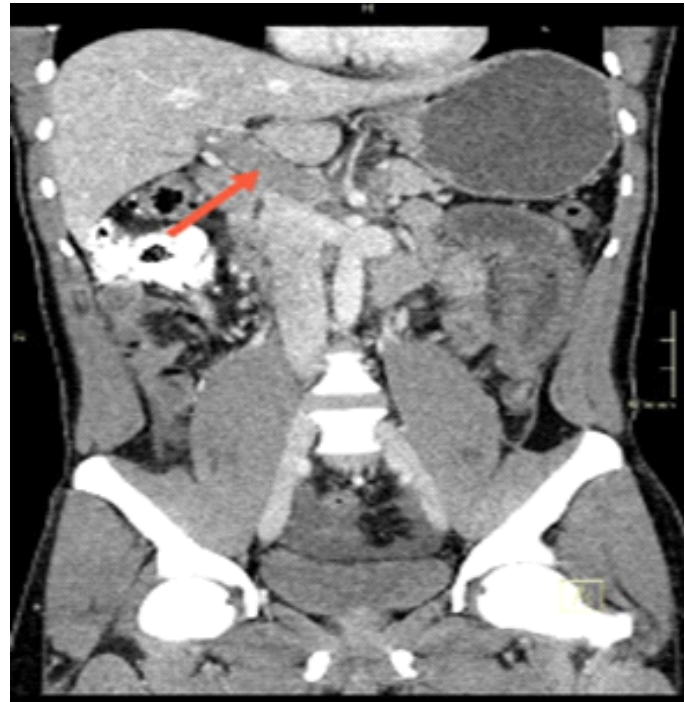

Figure 2: CT image showing portal vein thrombosis

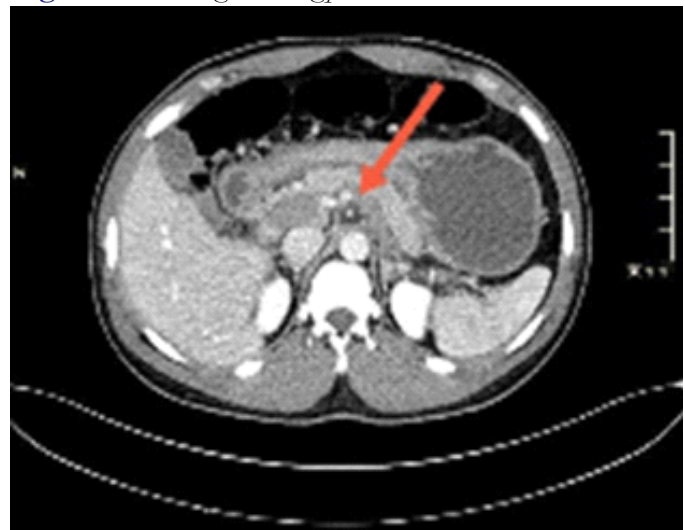


Figure 3: CT image showing splenic vein thrombosis

superior mesenteric and inferior mesenteric veins (Figures 2,3,4). Features of spleen were indicative of splenic infarcts. Doppler ultrasound of lower limb veins showed patents veins in both lower limbs indicating no deep vein thrombosis.

Colorectal surgeon advised to keep patient *Nothing per orum* (NPO) and Nasogastric intubation (NGT). Heparin Intravenous (IV) (adjustment for APTT), Tramadol 50mg Intramuscular eight hourly and Paracetamol 1gm IV eight hourly were started. Patient was then shifted to Intensive care unit (ICU) on the same day. On the second day of admission results of COVID-19 were

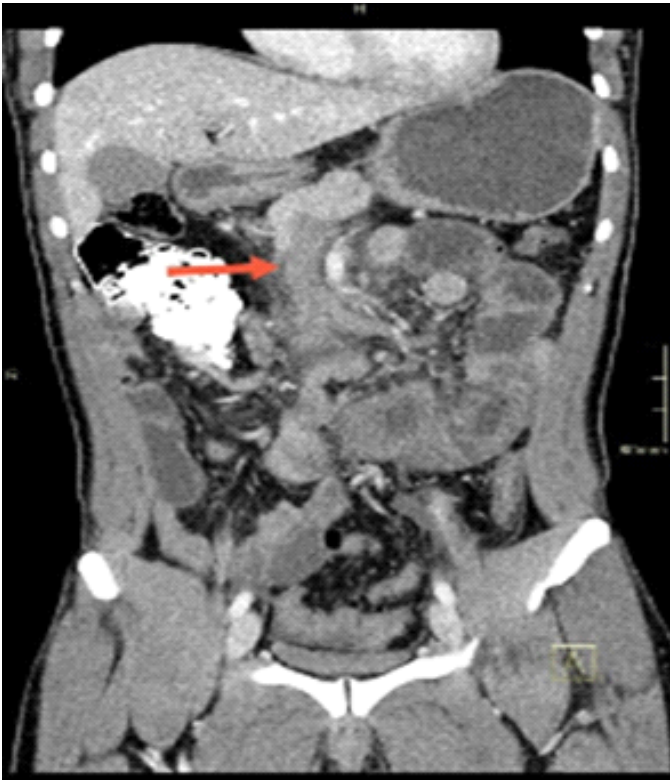

Figure 4: CT image showing superior mesenteric vein thrombosis

received and found to be positive. Favipiravir 1800 mg BID and then 800 mg BID and Dexamethasone 6 mg once a day though NGT were started. On 4th day of admission NGT was removed and soft diet was started. On 5th day, biochemical examination was repeated. PT was 13.6 seconds and INR was 1.16. CK was 115 U/L and WBC count was $12.7 \times 10^3/\mu\text{L}$. Direct Bilirubin was $4.4 \mu\text{mol/L}$. On 6th day, patient was given normal diet. On 7th day patient improved clinically and passed bowel. Analgesics were given only if needed. On 9th day, patient was discharged from the hospital with Paracetamol as needed, Apixaban 5mg orally BID.

Discussion:

Primarily COVID-19 is a respiratory tract infection but involvement of other systems specially gastrointestinal is not uncommon³. Unlike other cases^{4,6}, our case presented exclusively with GI symptoms without respiratory symptoms.

Decreased blood supply due to occlusion or any other cause may lead to ischemia and necrosis of mucosal cells in the GI tract. One of the risk factors of ischemic colitis is hypercoagulable state. COVID-19 has been reported to affect the coagulation where D-dimer and

Fibrinogen are markedly raised leading to poor prognosis. It is proposed that hypercoagulability in SARS CoV-2 infection is related to inflammatory state due to Cytokine surge rather than disseminated intravascular coagulation (DIC). Unlike cases reported earlier⁷⁻⁸, our patient had no risk factor of ischemic colitis. This further indicates that the ischemic colitis may be caused by COVID-19 related hypercoagulable state. Additionally, our patient was stable hemodynamically before and throughout the hospital stay which precludes the hypoperfusion resulting in ischemic colitis. Ischemic colitis is generally treated conservatively with close observation. Other cases reported however needed surgical intervention^{4,5,8-9}. Surgical intervention is required when there is colonic infarction or necrosis. We also treated our patient conservatively with anticoagulation therapy as per venous thrombosis/embolism protocol⁶.

Conclusion:

We presented a rare but serious case of ischemic colitis induced by SARS-CoV-2 infection. This will add to the scarce literature on hypercoagulable states in COVID-19 and its gastrointestinal complications. COVID-19 patients with gastrointestinal symptoms should be evaluated carefully for possible ischemia.

References:

1. Rodriguez-Morales AJ, Cardona-Ospina JA, Gutiérrez-Ocampo E, Villamizar-Peña R, Holguín-Rivera Y, Escalera-Antezana JP, et al. Clinical, laboratory and imaging features of COVID-19: A systematic review and meta-analysis. *Travel Med Infect Dis.* 2020;34(3):101623.
2. Tsimperidis AG, Kapsoritakis AN, Linardou IA, Psychos AK, Papageorgiou AA, Vamvakopoulos NC, et al. The role of hypercoagulability in ischemic colitis. *Scand J Gastroenterol.* 2015;50(7):848-55.
3. Wu Z, McGoogan JM. Characteristics of and Important Lessons From the Coronavirus Disease 2019 (COVID-19) Outbreak in China: Summary of a Report of 72314 Cases From the Chinese Center for Disease Control and Prevention. *Jama.* 2020;323(13):1239-42.
4. Chiu C-Y, Sarwal A, Mon A, Tan Y, Shah V. Gastrointestinal: COVID-19 related ischemic bowel disease. *J Gastroenterol Hepatol.* 2021;36(4):850.

5. Karna ST, Panda R, Maurya AP, Kumari S. Superior mesenteric artery thrombosis in COVID-19 pneumonia: an underestimated diagnosis—first case report in Asia. *Indian J Surg.* 2020;82(6):1235-7.
6. Paul T, Joy AR, Alsoub HARS, Parambil JV. Case Report: Ischemic Colitis in Severe COVID-19 Pneumonia: An Unforeseen Gastrointestinal Complication. *Am J Trop Med Hyg.* 2021;104(1):63.
7. Chan KH, Lim SL, Damati A, Maruboyina SP, Bondili L, Hanoud AA, et al. Coronavirus disease 2019 (COVID-19) and ischemic colitis: An under-recognized complication. *Am J Emerg Med.* 2020;38(12):2758.
8. Lázaro PG, Meneses AL, del Val Zaballos F, Rivas AM. Ischemic colitis and short bowel disease due to coronavirus disease 2019 (COVID 19). *Clin Nutr ESPEN.* 2020;40(3):406-7.
9. Norsa L, Bonaffini PA, Indriolo A, Valle C, Sonzogni A, Sironi S. Poor Outcome of Intestinal Ischemic Manifestations of COVID-19. *Gastroenterology.* 2020;159(4):1595-7.