

Research Article

Metamorphopsia and Optical Coherence Tomography Findings After Pars Plana Vitrectomy with Gas Tamponade

Madiha Waseem¹, Zaheer Sultan², Muhammad Muneer Quraishy³, Ummalqura Parekh⁴, Abdul Sami⁵

^{1,5} *Ophthalmology Department, Dow University of Health Sciences and Dr. Ruth K. M. PFAU Civil Hospital, Karachi*

Abstract:

Background: Rhegmatogenous retinal detachment (RRD) affects 1 in 10,000 populations per year. It is characterized by neurosensory retinal detachment from the retinal pigment epithelium due to a retinal break. Retinal detachment is present in 0.5 to 1% eyes after cataract surgery.

Objective: To evaluate metamorphopsia and its association with Optical Coherence Tomography (OCT) findings after Rhegmatogenous Retinal Detachment surgery by Pars Plana Vitrectomy using gas tamponade (Sf6).

Methods: Prospective, interventional study was carried out in Ophthalmology unit, Dow University of Health Sciences and Dr. Ruth K. M. PfaU Civil Hospital, Karachi from 22nd February 2021 to 1st August 2021. Thirty patients aged between 30 to 60 years, either gender and pseudophakic that underwent Pars Plana Vitrectomy for Rhegmatogenous Retinal Detachment using 20% sulfur hexafluoride tamponade were included. Metamorphopsia was assessed using Amsler grid and OCT was performed to evaluate retinal images 2 months postoperatively. Fisher's exact test was used for association between metamorphopsia and OCT findings.

Results: The mean age of the patients was 47.43 ± 8.39 years. At 2 months of surgery, metamorphopsia was present in 16/30 (53.3%) patients of which 11/16 (69%) had abnormal macula on OCT (disruption of photoreceptor junction (4 eyes, 26%), epiretinal membrane (2 eyes, 13%), subretinal fluid (2 eyes, 13%), retinal folds (1 eye, 6%), cystoid macular edema (1 eye, 6%) and macular hole (1 eye, 6%) and 5/16 (31%) exhibited a normal macula. In the non-metamorphopsia group of 14 patients, 3/14 (21%) showed abnormal macula and 11/14 (79%) had normal macula on OCT ($p = 0.014$; Fisher's exact test)

Conclusion: Metamorphopsia after pars plana vitrectomy with gas tamponade is more common in patients with abnormal retinal morphology on OCT.

Corresponding Author | Dr. Madiha Waseem, Ophthalmology Department, Dow University of Health Sciences and Dr. Ruth K.M PFAU Civil Hospital, Karachi **Email:** madiha.waseem@gmail.com

Introduction:

Rhegmatogenous retinal detachment (RRD) affects 1 in 10,000 populations per year.¹ It is characterized by neurosensory retinal detachment from the retinal pigment epithelium due to a retinal break.² Retinal detachment is present in 0.5 to 1% eyes after cataract surgery. Pseudophakic rhegmatogenous retinal detachment is associated with retinal breaks near ora serrata at the posterior vitreous base.³ Pars plana vitrectomy with gas tamponade is being used as the first line management for rhegmatogenous retinal detachment.^{4,5} It includes sulfur hexafluoride (SF₆), perfluoroethane (C₂F₆) and perfluoropropane (C₃F₈). Due to

high surface tension, fluid does not enter the retinal break.⁶ Metamorphopsia is a prevalent symptom after retinal detachment surgery with incidence of 39-88%.⁷ It is due to altered retinal anatomy which affects the photoreceptors orientation postoperatively.⁸ Amsler grid chart is used to detect metamorphopsia.⁹ Optical coherence tomography (OCT) imaging is a noninvasive modality for the assessment of retina.¹⁰ Postoperative epiretinal membrane, cystoid macular edema, subretinal fluid and disruption of ellipsoid zone were observed in patients with metamorphopsia on optical coherence tomography.¹¹

The purpose of our study is to determine the presence of

metamorphopsia and whether it is associated with postoperative OCT changes of retina. We also describe the different types of findings seen on the optical coherence tomography.

Methods:

This prospective, interventional study was conducted in the Department of Ophthalmology, Dow University of Health Sciences and Dr. Ruth K. M. Pfau Civil Hospital, Karachi from 22nd February 2021 to 1st August 2021. This study adhered to the Declaration of Helsinki. Written and informed consent was obtained. Sample size was calculated using prevalence of metamorphopsia (88%).⁷ It included 30 individuals aged 30 to 60 years, both gender, pseudophakic, with recent onset rhegmatogenous retinal detachment of less than two weeks duration and macular status off who were treated with pars plana vitrectomy with gas tamponade 20% sulfur hexafluoride (SF6). The fovea is involved in macula-off retinal detachment. All subjects underwent complete ocular examination including refraction, slit lamp biomicroscopy, measurement of intraocular pressure and fundoscopy. Exclusion criteria included patients with glaucoma, uveitis, amblyopia, diabetic retinopathy, vitreous hemorrhage, previous vitreoretinal surgery, macular disorders, traumatic or recurrent retinal detachment, retinal detachment duration of more than two weeks and best corrected visual acuity of $<6/36$ on snellen's chart. Amsler grid for the presence of metamorphopsia and OCT for postoperative retinal structure findings were performed 2 months after surgery.

Pars plana vitrectomy was performed by an experienced vitreoretinal surgeon using Constellation system. It included 23 gauge complete pars plana vitrectomy with perfluorodecaline, subretinal fluid drainage, air-fluid exchange, endolaser and gas tamponade with 20% sulfur hexafluoride (SF6) gas.

Amsler grid chart 1 with white lines on a black background was used for the presence of metamorphopsia. It has 400 squares of 5 mm. Each square subtends 1° angle. All patients were instructed to cover the non-operated eye and maintain fixation on the central dot on the Amsler grid chart and to report if the lines are wavy or not. Any distortion of the lines was labeled as metamorphopsia.

Optical Coherence Tomography (Heidelberg engineering, Germany, Spec-TR-04859) was performed by a single technician. It uses spectral (Fourier) domain OCT technology in which super luminescence diode beam of 870nm wavelength scans across the retina to produce cross sectional images. The patient is seated with head against the machine's

head band and chin on the chin rest and asked to look at the fixation point and images of retina are taken. The presence of postoperative findings such as subretinal fluid, cystoid macular edema, disruption of photoreceptor inner and outer segment junction, retinal folds, epiretinal membrane and macular hole was assessed.

Data analysis were done on SPSS version 23. Qualitative data including gender, site of eye, metamorphopsia, postoperative OCT findings was presented as frequency and percentage. Mean \pm standard deviation (SD) was calculated for age of the patients. Fisher's exact test was used to assess association between metamorphopsia and optical coherence tomography findings. $P \leq 0.05$ was considered significant statistically.

Results:

The mean age of the patients was 47.43 ± 8.39 years. 20 (66.7%) were males and 10 (33.3%) were females. 17 (56.7%) were right eyes and 13 (43.3%) were left eyes. After 2 months of follow-up, metamorphopsia on Amsler grid chart was present in 16/30 (53.3%) patients of which 11/16 (69%) had abnormal macular findings on OCT and 5/16 (31%) exhibited a normal macula. Whereas in the nonmetamorphopsia group of 14 patients, 3/14 (21%) showed an abnormal structure of macula and 11/14 (79%) had a normal appearing macula on OCT ($p = 0.014$; Fisher's exact test, two-sided) as shown in Table 1. Postoperative abnormal OCT findings of macula were disruption of photoreceptor inner segment and outer segment junction (4 eyes, 26%), epiretinal membrane (2 eyes, 13%), subretinal fluid (2 eyes, 13%), retinal folds (1 eye, 6%), cystoid macular edema (1 eye, 6%) and macular hole (1 eye, 6%) in patients with metamorphopsia as shown in Figure 1.

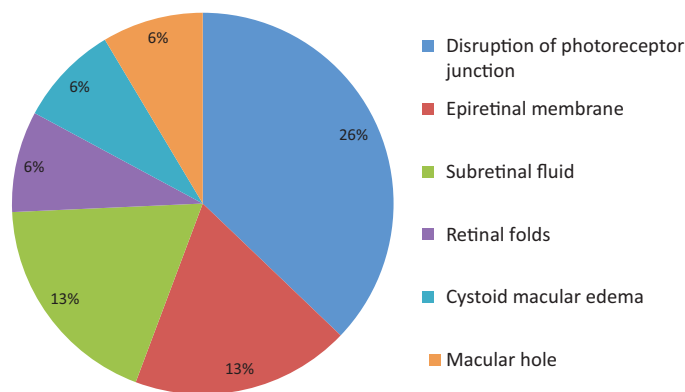


Figure 1: Postoperative OCT Findings in Patients with Metamorphopsia

Table 1: Correlation of OCT Findings in Patients with Metamorphopsia Versus No Metamorphopsia

	Abnormal Macula	Normal Macula
Metamorphopsia (53.3%)	11 (69%)	5 (31%)
No Metamorphopsia (46.7%)	3 (21%)	11 (79%)

(Fisher's exact test, two-sided; $p = 0.014$)

Discussion:

In our study, metamorphopsia and OCT findings were assessed in patients after Pars plana vitrectomy (PPV) with 20% SF6 gas due to macula-off rhegmatogenous retinal detachment in pseudophakic eyes at 2 months of the follow-up period. We included macula-off retinal detachments as metamorphopsia is more prevalent postoperatively in these eyes.

PPV is a preferred surgical technique for retinal detachment repair in pseudophakic eyes, as this procedure releases traction on retina and produces effective intraocular tamponade³. Metamorphopsia is the most common symptom seen after vitreoretinal surgery. The Amsler grid test is used for qualitative assessment of metamorphopsia⁵. In the present study, we found 53.3% metamorphopsia on Amsler grid test at 2 months of pars plana vitrectomy in pseudophakic macula-off rhegmatogenous retinal detachment patients. Borowicz reported 54% postoperative abnormality on Amsler test in patients with macula-off RRD which is similar to our result⁵. Another study demonstrated 56.69% metamorphopsia in macula-off RRD postoperatively¹². There are studies which reported postoperative metamorphopsia in 69.7% and 53% subjects^{13,14}. Metamorphopsia may persist in eyes of macula-off RD surgery suggesting micro structural macular damage that is not detected on standard funduscopy¹⁵. Optical Coherence Tomography (OCT) is a noninvasive and diagnostic procedure that detects any change in the morphology of macula after surgery.

There are only few studies demonstrating the correlation of metamorphopsia with OCT abnormalities. In our study, patients having metamorphopsia exhibited abnormal macula on OCT in 69% which included disruption of photoreceptor inner segment and outer segment junction (26%), epiretinal membrane (13%), subretinal fluid (13%), retinal folds (6%), cystoid macular edema (6%) and macular hole (6%). Normal macula on OCT was present in 31% eyes with metamorphopsia. In a study by Lina et al, OCT scans showed subretinal fluid, epiretinal membranes and macular edema resulting in visual distortion after vitrectomy for retinal detachment¹⁶.

Wakabayashi observed disruption of the photoreceptor inner and outer segments junction in 43%, epiretinal membrane in 12%, subretinal fluid in 11% and macular edema in 4% of the cases after retinal detachment surgery¹⁷. Borowicz noted 47% eyes had OCT macular changes after vitrectomy such as macular edema, epiretinal membrane and subretinal fluid⁵. Benson et al concluded subretinal fluid in 15% of RRD patients after vitrectomy with gas tamponade¹⁸. In a study by Okamoto, 39% patients had metamorphopsia with disruption of the photoreceptor inner and outer segment junction, subretinal fluid, epiretinal membrane, macular hole or cystoid macular edema on OCT¹⁹. Zhou and co-authors described OCT changes in macula after vitreoretinal surgery for RRD including disrupted inner segment/outer segment (35.00%), Subretinal fluid (26.84%), epiretinal membrane (11.58%), macular hole (2.37%) and cystoid macular edema (1.58%)¹². Another study concluded that postoperative metamorphopsia is due to epiretinal membrane, subretinal fluid, macular hole, retinal edema or normal OCT²⁰. The strength of our study is the ability to correlate the presence of metamorphopsia with macular pathology on OCT after vitrectomy that is important for the postoperative management of complications. The limitation was that our data was single centered and small sample size.

Conclusion:

Metamorphopsia after pars plana vitrectomy with gas tamponade is more common in patients with abnormal retinal morphology on optical coherence tomography.

Ethical Approval: Given

Conflict of Interest: The authors declare no conflict of interest.

Funding Source: None

References:

1. Kanski J, Bowling B. Clinical ophthalmology. 8th ed. Elsevier; 2016.
2. An Introduction to Metamorphopsia Following Retinal Detachment Repair for Ophthalmology Residents [Internet]. Eyes On Eyecare. 2022 [cited 6 August 2022]. Available from: <https://covalentcareers.com/resources/metamorphopsia-for-ophthalmology-residents>
3. Qadeem A, Fattah A. Outcome of rhegmatogenous retinal detachment surgery in uncomplicated pseudophakic eyes. Pak J Ophthalmol. 2012;28(1);38-42.
4. Gozawa M, Kanamoto M, Ishida S, Takamura Y, Iwasaki K, Kimura H, et al. Evaluation of intra-ocular gas using

- magnetic resonance imaging after pars plana vitrectomy with gas tamponade for rhegmatogenous retinal detachment. *Scientific Reports*. 2020;10(1):1-7.
5. Borowicz D, Nowomiejska K, Nowakowska D, Brzozowska A, Toro M, Avitabile T, et al. Functional and morphological results of treatment of macula-on and macula-off rhegmatogenous retinal detachment with pars plana vitrectomy and sulfur hexafluoride gas tamponade. *BMC Ophthalmol*. 2019;19(1):1-8.
 6. Kanclerz P, Grzybowski A. Complications Associated with the Use of Expandable Gases in Vitrectomy. *J Ophthalmol*. 2018;2018:1-7.
 7. Xu S, Wang L, Kong K, Li G, Ni Y. Metamorphopsia and Morphological Changes in the Macula after Scleral Buckling Surgery for Macula-Off Rhegmatogenous Retinal Detachment. *J Ophthalmol*. 2021;2021:1-7.
 8. Van de Put MA, Vehof J, Hooymans JM, Los LI. Postoperative metamorphopsia in macula-off rhegmatogenous retinal detachment: associations with visual function, vision related quality of life, and optical coherence tomography findings. *PLoS One* 2015;10(4):e0120543.
 9. Watanabe A, Arimoto S, Nishi O. Correlation between metamorphopsia and epiretinal membrane optical coherence tomography findings. *Ophthalmology*. 2009;116(9):1788-1793.
 10. Coppola M, Marchese A, Cicinelli M, Rabiolo A, Giuffrè C, Gomasasca S, et al. Macular optical coherence tomography findings after vitreoretinal surgery for rhegmatogenous retinal detachment. *Eur J Ophthalmol*. 2020;30(4):805-816.
 11. Murakami T, Okamoto F, Sugiura Y, Okamoto Y, Hiraoka T, Oshika T. Changes in metamorphopsia and optical coherence tomography findings after successful retinal detachment surgery. *Retina*. 2018;38(4):684-691
 12. Zhou C, Lin Q, Chen F. Prevalence and predictors of metamorphopsia after successful rhegmatogenous retinal detachment surgery: a cross-sectional, comparative study. *Br J Ophthalmol*. 2017;101(6):725-729.
 13. Yamada H, Imai H, Tetsumoto A, Hayashida M, Otsuka K, Miki A, et al. The contribution of the proximity of the retinal detachment to the fovea for postoperative metamorphopsia after 27-gauge pars plana vitrectomy for the primary rhegmatogenous retinal detachment. *PLOS ONE*. 2021;16(10):e0258775.
 14. Fu Y, Zhang YL. Analysis of factors of metamorphopsia after vitrectomy for rhegmatogenous retinal detachment. *Guoji Yanke Zazhi (Int Eye Sci)* 2021;21(5):906-909.
 15. Cheng KC, Cheng KY, Cheng KH, Chen KJ, Chen CH, Wu Wc. Using optical coherence tomography to evaluate macular changes after surgical management for rhegmatogenous retinal detachment. *Kaohsiung J Med Sci*. 2016;32(5):248-254.
 16. Lina G, Xuemin Q, Qinmei W, Lijun S. Vision-related quality of life, metamorphopsia, and stereopsis after successful surgery for rhegmatogenous retinal detachment. *Eye*. 2015;30(1):40-45.
 17. Wakabayashi T, Oshima Y, Fujimoto H, Murakami Y, Sakaguchi H, Kusaka S, et al. Foveal microstructure and visual acuity after retinal detachment repair: imaging analysis by Fourier-domain optical coherence tomography. *Ophthalmology*. 2009;116(3):519–28.
 18. Benson SE, Schlottmann PG, Bunce C, Xing W, Charteris DG. Optical coherence tomography analysis of the macula after vitrectomy surgery for retinal detachment. *Ophthalmology*. 2006;113(7):1179–83.
 19. Okamoto F, Sugiura Y, Okamoto Y, Hiraoka T, Oshika T. Metamorphopsia and optical coherence tomography findings after rhegmatogenous retinal detachment surgery. *Am J Ophthalmol*. 2014;157(11):214–220.
 20. Thesis G. Analysis of The Causes of Postoperative Metamorphopsia After Successful Surgery For Rhegmatogenous Retinal Detachment [Internet]. *Globethesis* 2022 [cited 6 August 2022]. Available from: <https://www.globethesis.com/?t=2334330515974385>