

## Research Article

# Our Experience of Lid Shortening (Kuhnt -Szymanowski Technique) in Lower Lid Blepharoplasty to Reduce Ectropion Formation

Muhammad Osama<sup>1</sup>, Shehab Afzal Beg<sup>2</sup>

<sup>1,2</sup>Plastics and Reconstructive Surgery, Liaquat National Hospital, Karachi

### Abstract:

**Background:** Lower eyelid bags, tear trough deformity and lax eye lid skin are a few aging conditions for which people seek plastic surgeon's consultation. These cosmetic concerns can be effectively addressed by lower lid blepharoplasty but this procedure alone may predispose patient to lid malpositioning and ectropion later. Including the Kuhnt Szymanowski technique with lower lid blepharoplasty, in which wedge resection of lateral posterior lamella is done, can reduce ectropion formation specially in patients with lid distraction of more than 6mm away from the globe.

**Objective:** The objective of our study is to reduce the chances of ectropion formation and scleral show specially in elderly patients undergoing lower eyelid blepharoplasty for the correction of lower eyelid laxity and to evaluate patient's outcome.

**Methods:** This is a retrospective case series with 2 years duration from January 2019 to December 2020. All patients with lid distraction > 6mm were operated and bilateral lower lid blepharoplasty and Kuhnt Szymanowski technique was performed under L.A. Mean duration of follow-up was 6 months post-operatively and patients' surgical outcomes were assessed.

**Results:** In our study, total 20 patients were included. Total number of eye surgeries performed were 40. Majority of patients were female (64%) were female. None of the patients (0%) reported ectropion formation post-operatively.

**Conclusion:** In our experience, Kuhnt Szymanowski technique addresses lower eyelid laxity effectively. This technique when added in selected group of patients, reduces chances of temporary or permanent ectropion, hence reduces morbidity and redo procedures.

**Corresponding Author** | Prof. Dr Shehab Afzal Beg, Plastics and Reconstructive Surgery, Liaquat National Hospital Karachi **Email:** shehabbeg@hotmail.com

**Keywords:** lower eyelid blepharoplasty, lid laxity, lid distraction test, Kuhnt Szymanowski technique, ectropion

### Introduction:

Aging is a normal physiological phenomenon in the body as we grow older. As people age, skin tone and eyelids also show signs of aging. Decreased skin laxity and increased orbital fat is thought to be responsible for noticeable changes in the eyelids. These changes include lower eyelid bags, prominent tear trough, crow feets and malar fat pads.<sup>1</sup>

Due to decreased tone of lower eyelids, horizontally skin laxity is noted gradually and predisposes the lids to be positioned more inferiorly.<sup>2,3</sup> This condition can be assessed clinically by lid distraction test or “snap” test.<sup>4</sup> Lower eyelid skin is held by examiner and then it is

moved away from the globe and distance between the globe and lower eyelid margin measured and if the distance is 6mm or greater then it is considered positive.<sup>2,5</sup>

Eyelids rejuvenation procedures are one of the challenging procedures in cosmetic surgery. Each technique is tailored according to the presenting complain of the particular individual. Lower eyelid blepharoplasty is the surgical procedure to address these concerns.<sup>1</sup> Subciliary incision is preferred cosmetically due to its deeper approach to structures and cantholysis can be performed simultaneously if needed.<sup>6</sup> One of the sequelae of lower lid blepharo-

plasty is that post-operatively, there is risk of lid malpositioning and chances of ectropion formation<sup>7,8</sup> in some patients especially those with  $\geq 6$ mm lid distraction. Therefore, it is important that such patients should undergo additional maneuver to reduce the risk of ectropion formation post-operatively.

Tightening of lower eyelid horizontally while performing blepharoplasty has shown to reduce chances of ectropion formation post-operatively. Traditionally, Kuhnt Szymawoski<sup>9,10</sup> described a technique of shortening the lid and later modified. After performing subciliary blepharoplasty to excise excess skin and orbital fat, a full thickness wedge of lateral posterior lamella is resected, thus surgically tightening the lid horizontally.<sup>2,11</sup>

The rationale of this study is to share our clinical experience in correction of lower eyelid laxity and reducing chances of ectropion formation post-operatively especially in elderly population when Kuhnt Szymanowski technique is combined with lower lid blepharoplasty.

### Methods:

This is a retrospective case series conducted in the Department of Plastics and Reconstructive Surgery, Liaquat National Hospital, Karachi. The duration of study is 02 years i.e. from January 2019 to December 2020. Consecutive sampling was done and all patients who presented with lower eyelid bags, and loose skin tone with lid distraction of more than 6mm away from the globe with no previous intervention done were included in the study. Patient with prior lower eyelid surgery either cosmetic or tumor resection or with medial or lateral canthus laxity on examination were also excluded.

Sample size was calculated using WHO online sample size calculator. Effect size was taken as large (0.9),  $\alpha$  error probability was taken as 0.05. Power (1- $\beta$  error probability) was taken as 0.8. Based on above values the total sample size was calculated to be 20.

All patients who met the inclusion criteria underwent lower eyelid blepharoplasty with Kuhnt- Szymanowski procedure. Data was collected using a proforma and post-operatively ectropion and other post-surgical outcomes were assessed. Follow up period in all patients

was 06 months.

Data were analyzed using SPSS version 20.0 statistical package.

### Surgical Technique:

After all aseptic measures, patient prepped and draped, local anesthesia is infiltrated in concentration of 1:1 ratio of 2% lidocaine and adrenaline in the operative area. Then a subciliary incision is given in the lower eyelid just short of the lacrimal punctum and extending 1cm laterally from the lateral canthus.

Skin flaps are retracted and dissection proceeds in line of incision, orbicularis oculi muscle fibers are divided and dissection continues until orbital septum is reached. The septum is opened to reach the suborbicularis oculi fat (SOOF).

By gentle pressure with finger on upper eyelid, excess fat is displaced anteriorly in lower eyelid which is exposed and held in artery forceps and excised via electrocautery. This maneuver is repeated until the desired excess fat is removed to achieve the cosmetic contour.

In order to perform Kuhnt Szymanowski technique (see fig 1a-d), full thickness wedge excision is done in lateral aspect of posterior lamella of the lower eyelid (including skin, tarsal plate, conjunctiva). Hemostasis is secured and margins are overlapped to determine the excess tissue which is loosely excised and in incremental fashion until the desired result is achieved and incision reapproximated with Vicryl 6.0. Then the hanging lax skin is redraped over the subciliary incision margin, marked and excised and wound is closed with prolene 6.0 in subcutaneous fashion.

### Results:

During the 2-years study period, a total of 20 patients (n=20) underwent lower lid blepharoplasty. Majority of patients were female 65% (n=14) with mean age 60 (range= 41 – 75). Total 40 cases were operated for lower lid laxity. Table 1 describes the basic demographics of study population.

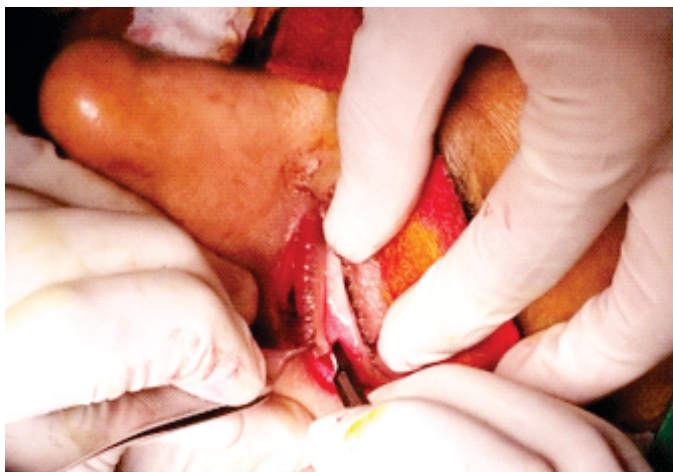
Average follow-up was 6 + 2 months Few of the patients developed minor complications after the procedure. Fig 1 demonstrates the rate of post-operative complications observed on subsequent

follow up of patients.

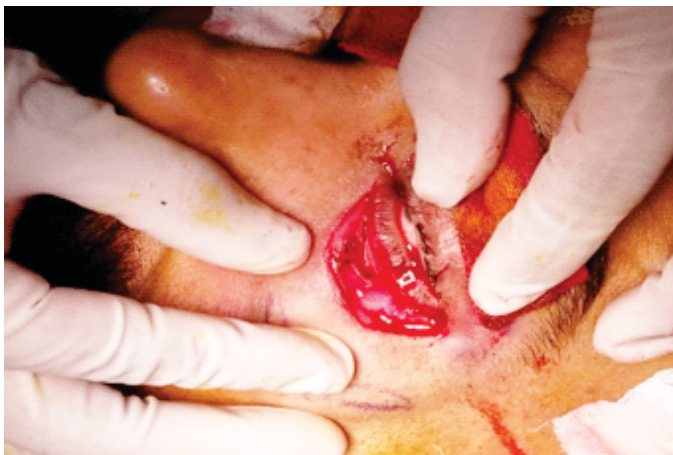Out of 20 patients, 4 patients (20%) developed chemosis which resolved spontaneously. Other 4 patients (20%) also developed minor bruising in early post-operative period which did not need any further treatment. None of the patients developed ectropion or scleral show in 6 monthly follow up duration. Edema at the operative site was a common sequela in all operated patients and hence not taken as a specific complication in the study.

**Table 1:** Patient Demographics

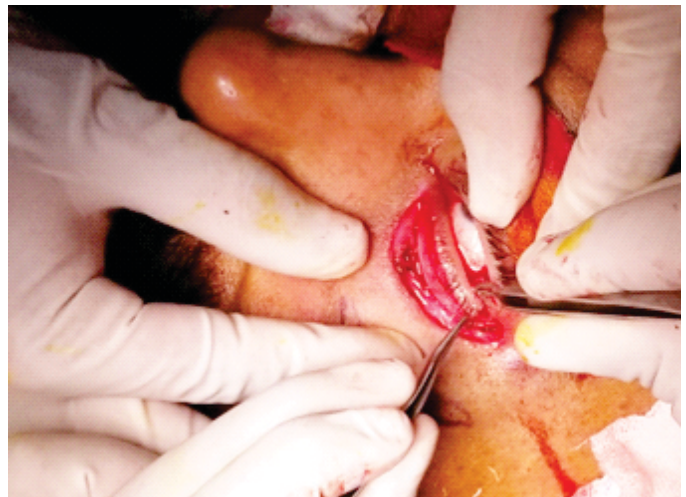Mean age at operation (range)	60 years (41-78)
Gender	Male= n-08 Female= n-14
Total number of eye surgeries	40
Average time in months to follow-up (range)	6 ± 2



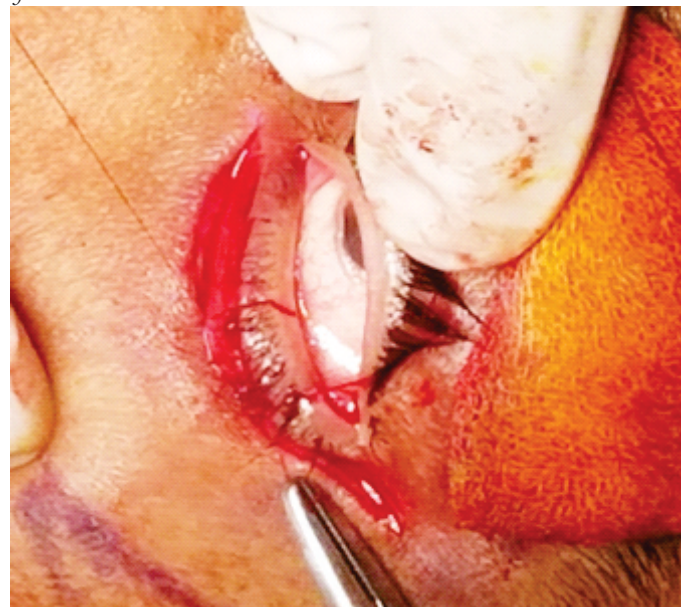**Figure 1a:** Intra-operative View of Full Thickness Incision on Posterior Lamella (Kubnt-Szymanowsky)



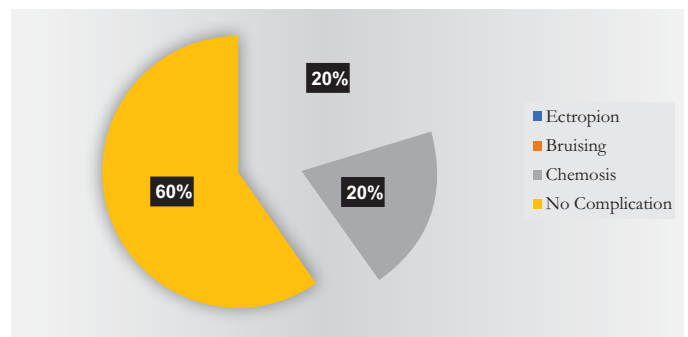
**Figure 1c:** Intra-operative View of Lower Lid after Excision of Excess Margins



**Figure 1b:** Overlapping of Lid Margins to Assess Laxity of Lower Lid



**Figure 1d:** Wound Closure in Layers



**Figure 2:** Post-Operative Complications Rate

### Discussion:

Eyelid rejuvenation is a challenging task for plastics and cosmetics surgeons. With evolution of procedures in recent years, horizontal skin laxity and lower lid

malpositioning can be addressed effectively. Many treatment options have been described in literature including lateral canthopexy, canthoplasty or wedge resection etc. to correct the laxity and malposition.<sup>1</sup>

Rees in 1983<sup>4</sup> first described wedge resection of lower lid to correct skin laxity with the technique still followed by many surgeons with favorable results.<sup>5,12</sup> Resecting the posterior lamella of the lower lid in wedge shape leads to shortening of the lower lid and reduces the chances of ectropion formation. This technique was first described by Kuhnt<sup>9</sup> and Szymanowski<sup>10</sup> in which the wedge excision was done laterally and later modified by Smith.<sup>13</sup>

In our study, we performed the Kuhnt Szymanowsky technique to address lower eye lid laxity as well as lid malpositioning in patients in order to address age related changes in lower lid skin with globe to lid margin distance of  $\geq 6$ mm while performing lid snap test. We found 85% favorable outcome in patients as evaluated on Visual analogue scale. The other group reported less favorable outcome, partly due to ectropion formation in 4 patients as a result of scarring post-operatively.

None of the patients, however, in group B reported lower lid displacement on follow up visits. We believe wedge resection of lateral posterior lamella during surgery played a role in alleviating this complication later on.

Apart from ectropion, chemosis and bruising were two most common complications presented by our patients on follow up. These are some common problems that have been reported in literature.<sup>14,15,16</sup> Both these complications resolved spontaneously and did not require any intervention. Those patients who developed ectropion later underwent revision surgery for correction, thus subjecting them to another procedure with revisit to theatre.

**Conclusion:** In light of the above mentioned findings, we experienced that combining Kuhnt Szymanowsky technique with lower lid blepharoplasty results in favorable outcome and overall satisfaction in patients in addressing their aesthetic concerns. This technique not only takes into account lower lid laxity efficiently but also when added in selected group of patients, reduces chances of temporary or permanent ectropion, hence

reduces morbidity and redo procedures.

**Ethical Approval:** Given

**Conflict of Interest:** The authors declare no conflict of interest.

**Funding Source:** None

#### References:

1. Branham GH. Lower Eyelid Blepharoplasty. *Facial Plastic Surgery Clinics of North America*. 2016;24(2): 129–138. doi:10.1016/j.fsc.2015.12.004
2. Van Slyke AC, Carr LA, Carr NJ. The KS-Pexy: a novel method to manage horizontal lower eyelid laxity. *Plastic and Reconstructive Surgery*. 2020 Feb 1;145(2):306e-15e.
3. Shore JW. Changes in lower eyelid resting position, movement, and tone with age. *Am J Ophthalmol*. 1985;99(4):415-423.
4. Rees TD. Prevention of ectropion by horizontal shortening of the lower lid during blepharoplasty. *Ann Plast Surg*. 1983;11(1):17-23.
5. Hester TR, Douglas T, Szczerba S. Decreasing complications in lower lid and midface rejuvenation: the importance of orbital morphology, horizontal lower lid laxity, history of previous surgery, and minimizing trauma to the orbital septum: A critical review of 269 consecutive cases. *Plast Reconstr Surg*. 2009;123(3): 1037-1049
6. Bhoutekar P, Winters R. Blepharoplasty subciliary approach.; 2021 Jan–. PMID: 32491591.
7. Murri M, Hamill EB, Hauck MJ, Marx DP. An Update on Lower Lid Blepharoplasty. *Semin Plast Surg*. 2017 Feb;31(1):46-50.
8. McGraw BL, Adamson PA. Postblepharoplasty ectropion. Prevention and management. *Arch Otolaryngol Head Neck Surg*. 1991;117(8):852-856.
9. Suzuki S, Dawson RA, Chirila TV, Shadforth AM, Hogerheyde TA, Edwards GA, et.al. Treatment of silk fibroin with poly (ethylene glycol) for the enhancement of corneal epithelial cell growth. *Journal of functional biomaterials*. 2015 May 29;6(2):345-66.
10. Fox SA. A Modified Kuhnt-Szymanowski Procedure: for ectropion and lateral canthoplasty. *American Journal of Ophthalmology*. 1966 Sep 1;62(3):533-6.
11. McGraw BL, Adamson PA. Postblepharoplasty ectropion. Prevention and management. *Arch Otolaryngol Head Neck Surg*. 1991;117(8):852-856.

12. Hayashi A, Mochizuki M, Kamimori T, Horiguchi M, Tanaka R, Mizuno H. Application of Kuhnt-Szymanowski Procedure to Lower Eyelid Margin Defect after Tumor Resection. *Plast Reconstr Surg Glob Open*. 2017 Feb 22;5(2):e1230. doi: 10.1097/GOX.0000000000001230. PMID: 28280671; PMCID: PMC5340486.
13. Pacella SJ, Codner MA. Minor complications after blepharoplasty: Dry eyes, chemosis, granulomas, ptosis, and scleral show. *Plast Reconstr Surg*. 2010;125(2):709-718.
14. Prischmann J, Sufyan A, Ting JY, Ruffin C, Perkins SW. Dry eye symptoms and chemosis following blepharoplasty: A 10-year retrospective review of 892 cases in a single-surgeon series. *JAMA Facial Plast Surg*. 2013;15(1):39-46.
15. Weinfeld AB, Burke R, Codner MA. The comprehensive management of chemosis following cosmetic lower blepharoplasty. *Plast Reconstr Surg*. 2008;122(2):579-586.