

Research Article

Outcome of Recto Anal Repair (RAR) without Doppler Transducer for Symptomatic Grade II, III and IV Internal Haemorrhoids

Wasif Majeed Chaudhry¹, Hania Aamir², Amber Mohsin³, Salman Majeed Chaudhry⁴, Samar Ghufraan⁵, Maryam Jamil⁶

^{1,2,3,6}Lahore Medical and Dental College/ Ghurki Trust Teaching Hospital, Lahore; ⁴Rabbar Medical & Dental College, Lahore; ⁵Akhtar Saeed Medical College, Lahore

Abstract:

Background: Haemorrhoidal illness causes around 4% of illness around the world. Internal haemorrhoids are painful and need surgical correction. Haemorrhoidectomy involves excision of haemorrhoidal tissue through transfixion of the arterial supply.

Objective: To assess the outcome of recto-anal repair without doppler transducer for the treatment of grade II, III and IV internal hemorrhoids.

Methods: This descriptive case series was conducted at Ghurki trust teaching hospital, Lahore, Pakistan, between January 2016 to December 2021. Using a convenience sampling technique, 100 patients who attended the outpatient department of the hospital were recruited for this study. These patients presented in the Outpatients Department with grade-II, III or IV symptomatic internal haemorrhoids. Surgical intervention was conducted in the form of recto-anal repair without doppler transducer at the three primary sites of internal haemorrhoids in all patients and outcome was measured in terms of mean operating time, length of hospital stay, post-operative pain score, recurrence of prolapse and bleeding, and early and late post-operative complications with one year follow up for all patients.

Results: Amongst the study sample, 60% patients were male and 40% were female. The mean age of the patients was 45 years and the mean operating time was 39 minutes. The mean duration of hospital stay was 26 hours. The mean postoperative pain score calculated by visual analogue scale (VAS), twenty-four hours after the surgery was 2.54. Six patients complained of excessive pain persisting for one week, two patients developed anal fissures with bleeding after the procedure. Long term follow-up spanning over one year, showed recurrence of prolapse in one patient. No patient suffered from wound infection, anal stenosis and fecal incontinence due to anal sphincter dysfunction.

Conclusion: Recto-anal repair without doppler transducer is an effective method for the treatment of grades-II, III and IV internal haemorrhoids, with very low post-operative pain scores, good relief of symptoms and low recurrence rates. The added advantage is a very low cost because the doppler probe is not required.

Corresponding Author | Dr. Wasif Majeed Chaudhry, Associate Professor, Department of General Surgery, Lahore Medical and Dental College/ Ghurki Trust Teaching Hospital, Lahore

E-mail: drwasifchaudhry@gmail.com

Introduction:

Haemorrhoidal illness is so frequent that it affects around 4% of the world's population, according

to the World Health Organization.² Haemorrhoids are a frequent anorectal condition in which intensely vascular venous cushions consisting of fibrous elastic tissue,

muscle fibres, and arteriovenous connections enlarge and prolapse distally out of the anal canal".^{1,2} Internal haemorrhoids occur when the supporting tissues of the anal cushions weaken, causing them to bulge outward.^{3,4} Internal haemorrhoids are most commonly found in patients who strain during defecation as a result of persistent constipation.¹ Anoderm thinning and internal sphincter spasm are two of the most important factors in the pathophysiology of internal haemorrhoids.³ Internal haemorrhoids are most commonly located in the 3, 7, and 11 o'clock positions, which correspond to the three major anal cushions, with a few minor anal cushions found in between these three primary sites.⁴ Goligher's classified internal haemorrhoids according to the degree of prolapse into the following four categories: grade-I haemorrhoids that bleed but do not prolapse outside the anal canal, grade-II haemorrhoids that bleed and the anal cushions prolapse through the anus on straining but reduce spontaneously, grade-III haemorrhoids that bleed with the anal cushions prolapsing through the anus on straining or exertion but do not reduce spontaneously, and grade-IV haemorrhoids are permanently prolapsed and may be thrombosed.⁴ Treatment for haemorrhoidal illness varies depending upon the severity of the condition. For grade I and II haemorrhoids, non-operative treatment is usually successful; however, for grade III and IV haemorrhoids, surgical treatment is frequently required.⁵

Haemorrhoidectomy is a surgical procedure that involves the excision of the excess haemorrhoidal tissue through transfixion of the arterial supply.¹ Despite the fact that haemorrhoidectomy has been the gold standard procedure for the treatment of symptomatic grade III and IV haemorrhoids for many years, it is associated with a number of serious complications, including severe post-operative pain, anal stenosis, incontinence due to internal and external sphincter damage and anal sepsis.¹ The presence of bleeding, sepsis, rectovaginal fistulae, and rectal perforation are related with stapled haemorrhoidectomy.² The use of minimally invasive surgical treatments have been increasingly popular in the last two decades, with the goal of minimising the number of complications associated with conventional haemorrhoidectomy and stapled haemorrhoidectomy.² This method was first

published by Moringa et al. in 1995, and the basic idea behind it was to ligate the branches of the superior rectal artery while using ultrasound guidance to do so.⁷ Eventually, this causes fibrosis and shrinking of the haemorrhoids as a result of a reduction in the blood flow to the anal tissue.⁵ For the past two decades, this approach has been used all over the world with great outcomes in a variety of research studies.⁵ This treatment is now carried out using a variety of different equipment, including Haemorrhoidal artery ligation and recto anal repair (HAL & RAR[®]) and trans-anal haemorrhoidal dearterialization (THD[®]), all of which are expensive for developing countries to afford.⁸ Many studies have demonstrated that recto-anal repair may be performed for grade II, III, and IV internal haemorrhoids without the use of doppler guidance and that the results are equivalent, resulting in lower treatment costs for the patients.^{8,9}

The purpose of this observational study was to evaluate the outcomes of recto-anal repair without the use of a doppler transducer for the treatment of internal haemorrhoids of grades II, III, and IV. The outcome of this study were measured in terms of mean operating time, length of hospital stay, post-operative pain score, recurrence of prolapse and bleeding, and early and late post-operative complications through multiple follow ups.

Methodology:

During the period of January 2016 to December 2021 the research was carried out at the Ghurki Trust and Teaching Hospital in Lahore, Pakistan. Ethical approval for this research was taken from the institution's ethical review board (ERB). The first patient was enrolled on the 10th of January 2016 and the last patient was enrolled on 25th of December, 2020. The last follow-up visit of the last enrolled patient was completed on 21st of December, 2021. One hundred patients who presented in the outpatient department and fulfilled the inclusion criteria were counseled and explained in detail about this study. Patients willing to give informed consent for the recto-anal repair procedure and fulfilling the grade requirement of II, III or IV were included in the study. Bleeding and non-bleeding haemorrhoids were selected through convenience sampling. Patients who were declared unfit to undergo general anesthesia were

excluded from this study. Patients who had thrombosed haemorrhoids, renal failure and immunosuppression were also excluded.

All the data was recorded on a predesigned proforma. Symptoms and signs including itching, perianal discharge, degree of prolapse, quantity of bleeding, associated anal fissure, perianal skin tags were recorded for every patient. A detailed history of the patient was taken by the surgical residents. A thorough clinical examination was performed by one consultant surgeon. Each patient had their laboratory investigations conducted which were required for general anaesthesia. All patients underwent recto-anal repair without doppler guidance at the three primary sites i.e., 3, 7 and 11' O clock. Post-operative follow-ups were also conducted by the same surgeon to eliminate bias.

Surgical procedure:

The sample population was given intravenous

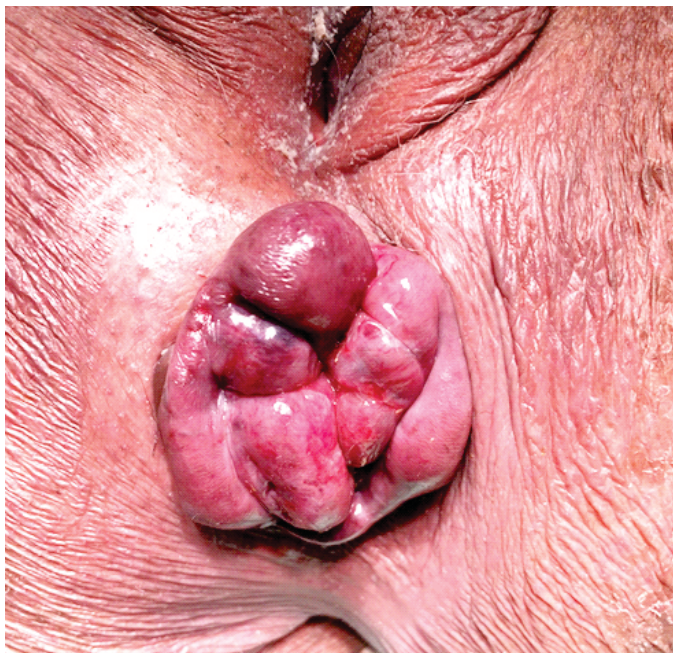

Figure 1.2: *Grade-IV haemorrhoids before RAR*

Amoxicillin with Clavulanic acid, 1.2 gram and intravenous Metronidazole, 500mg at induction of anaesthesia and continued postoperatively till the patient was discharged. All these surgeries were performed under general anaesthesia in the lithotomy position. Under aseptic measures, digital rectal examination and proctoscopy were performed in every patient and preoperative examination findings and any

additional pathology were confirmed. An anoscope with a window for suturing was introduced into the anal canal and recto-anal repair were performed at 3, 7 and 11 O' clock positions in all patients with Polyglactin (Vicryl 2/0) suture on a 31mm round body needle. The first stitch was taken at a distance of 5 cm from the anal verge and multiple interlocking continuous stitches were taken 1cm apart distally, the last stitch being just above the dentate line. The mucosal haemorrhoidal prolapse was lifted when the last stitch was ligated with the proximal end of the suture. Hemostasis was secured wherever required and anal canal was packed with a liquid paraffin-soaked roll gauze to apply pressure which was removed six hours after the procedure. All patients were discharged on oral Amoxicillin - Clavulanic acid and Oral Metronidazole for three days. Postoperative follow ups were conducted at 1 week 6 weeks, 6 months and 1-year intervals. In all these follow-up visits, clinical examination was performed and questions were asked about the resolution of symptoms like bleeding, prolapse, anal fissure, fecal incontinence, perianal fistula, time required to resume normal daily activities after surgery, and overall satisfaction of the patient with the procedure and documented on the proforma.

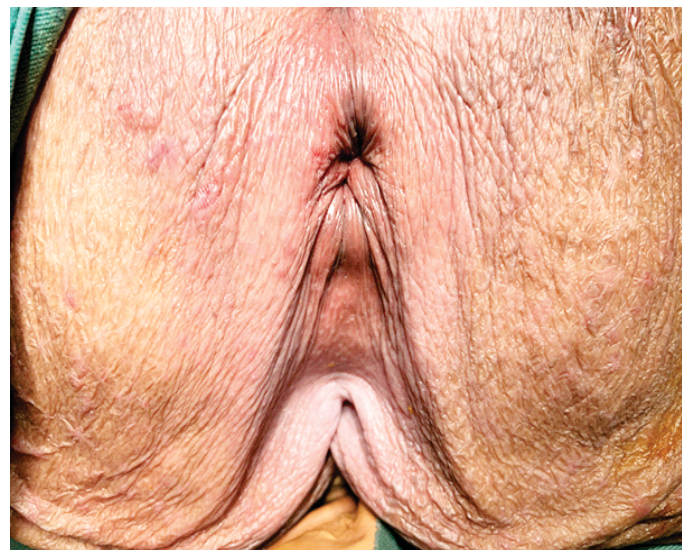


Figure 1.2: *Grade-IV haemorrhoids after RAR*

Statistical analysis:

The collected data was entered in the SPSS version 20.0 and analysis was completed. Numerical variables i.e., age, operating time, postoperative pain and length of

hospital stay were presented by mean \pm standard deviation. Gender was presented as frequency and percentages.

Results:

A total of 100 patients underwent recto-anal repair without doppler probe in this study. The patients age ranged between 14 years to 85 years. The mean age was 45.05 ± 15.47 years. 60 patients (60 %) were men and 40 patients (40 %) were women. Majority of the patients (53%) presented with third degree prolapse, 32 % patients had second degree prolapse and only 15% patients had fourth degree prolapse without thrombosis. 85 % patients had bleeding from the haemorrhoids on presentation and 15 % patients had no bleeding on presentation.

The outcome measures are presented in table. 1 and table. 2. The mean operating time was 38.55 ± 11.37 minutes, the minimum being 15 minutes and the maximum being 60 minutes. The mean duration of hospital stay was 26.40 ± 8.69 hours, the minimum being 24 hours and the maximum being 72 hours. The mean postoperative pain score calculated by VAS, twenty-four hours after the surgery was 2.54 ± 1.74 (Table.1). 8 patients had no pain at all after surgery i.e., VAS of 0, 76 patients (76%) had mild pain with a VAS between 1-3. 12 patients (12%) suffered from moderate pain with a VAS between 4-6. Five patients (5%) had severe pain ranging between 7 to 9 on VAS. These 5 patients required narcotic analgesia during their hospital stay but

Table 1: Mean operating time, Duration of hospital stay and Postoperative pain score

Outcome Variable	Min. value	Max. value	Mean \pm Standard deviation
Operating time (minutes)	15	60	38.55 ± 11.37
Duration of hospital stays (hours)	24	72	26.40 ± 8.69
Postoperative pain score at 24 hours after surgery (VAS)	0	9	2.54 ± 1.74

they had no pain after seven days of the procedure.

No patient suffered from postoperative complications

like surgical site infection, anal stenosis, and fecal incontinence due to sphincter damage (Table. 2). Two patients developed anal fissure approximately one week after the procedure and presented with pain and bleeding mixed with stool. One patient presented with recurrence of prolapse within a period of one year of follow-up. Overall, 92% of the patients had resolution of the complaints of bleeding and prolapse after one year follow-up. The remaining two percent of patients who developed anal fissure due to overstretching of the anal canal were treated with conservative measures and the fissures healed completely without any surgical intervention.

Table 2: Outcomes of Mucopexy without Doppler

Outcome Variable	Percentage
Surgical site infection	0%
Anal stenosis	0%
Fecal incontinence due to anal Sphincter damage	0%
Post-operative anal fissure	2%
Perianal fistula	0%
Recurrence of bleeding	1 %
Recurrence of prolapse	1 %

Discussion:

Many minimally invasive techniques have been employed in the last two decades to treat various grades of internal haemorrhoids. Doppler guided haemorrhoidal artery ligation was initially established in the year 1995 by Moringa et al. and since then it is being utilised successfully over the world.⁷ In Pakistan, HAL & RAR[®] was launched in the past ten years and is being used successfully by numerous surgeons for some time.^{10,11,12} The efficacy of this approach without the use of doppler equipment has been proved in several researches and has been accepted by the National institute of Health and Care excellence of the United Kingdom (NICE).^{8,13,14} The method with doppler is not accessible for the general people of Pakistan because of the costly doppler equipment.^{8,14} The current research was designed to analyse the outcomes of the recto-anal repair without the need of doppler guidance keeping in view several previous such researches completed in different parts of the world.^{8,9,13,14} Success of recto-anal

repair without doppler guidance is proven in several researches for grade II and III haemorrhoids but is not very typically used for grade IV haemorrhoids.^{8,9,10,11,12}

In this research, patients with grade-II haemorrhoids not responding to injectable sclerotherapy or banding, grade-III and grade-IV haemorrhoids were included. The outcomes of this study are comparable to past similar researches.^{8,9,10,11,12} About 92% of the patients did not have any complains during the immediate post-operative time and over the complete follow up period of one year. Five patients suffered from moderate anal pain (VAS 4-6) which lasted for one week and resolved spontaneously after a week. The mean postoperative pain score was 2.54, twenty-four hours after the surgery, which is fairly low as compared to open hemorrhoidectomy.^{12,15,16} Majority of the patients felt modest discomfort (VAS 1-3) after 24 hours of surgery.

The mean operative time of thirty eight minutes is comparably better than the HAL and RAR approach with doppler probe.¹² The mean length of hospitalisation was 26.40 hours, which is much shorter than the average length of hospitalisation for open hemorrhoidectomy reported in literature.¹⁰ No patient experienced any postoperative complications such as surgical site infection, anal stenosis, perianal fistula, or faecal incontinence as a result of sphincter injury, which demonstrates the safety of this procedure.

A limitation of this approach was that no comparison trial with the technique of open haemorrhoidectomy was conducted. As open haemorrhoidectomy results in higher rates of complication, the procedure is not preformed frequently in practice.^{12,15,16} Therefore, an adequate comparison could not be achieved between the two procedures.

In this study, the most significant finding was that only one patient appeared with both haemorrhoidal prolapse and post-operative bleeding at the one-year follow-up period that was set aside for each patient. This was an important outcome as it is superior to the results of many earlier studies in which doppler was utilised.^{10,11,12}

Another factor that can be addressed in this procedure is that in contrast to other researches the pulsation of the haemorrhoidal artery was not felt.¹⁰ The primary surgeon believes that this has no relevance in

conducting recto-anal repair.

Conclusion:

Recto-anal repair without doppler transducer is an effective method for the treatment of grades II, III and IV internal haemorrhoids, with very low post-operative pain scores, good relief of symptoms, high patient satisfaction level, and very low recurrence rates. The added advantage is a very low cost due to not using the doppler probe.

Ethical Approval: Given

Conflict of Interest: The authors declare no conflict of interest.

Funding Source: None

References:

1. Lohsiriwat V. Hemorrhoids: from basic pathophysiology to clinical management. *World J Gastroenterol.* 2012;18(17):2009-17. doi: 10.3748/wjg.v18.i17.2009.
2. Cerato MM, Cerato NL, Passos P, Treigue A, Damin DC. Surgical treatment of hemorrhoids: a critical appraisal of the current options. *Arq Bras Cir Dig.* 2014; 27(1):66-70. doi: 10.1590/s0102-67202014000100016. PMID: 24676303;
3. Yamana T. Japanese Practice Guidelines for Anal Disorders I. Hemorrhoids. *J Anus Rectum Colon.* 2018; 1(3):89-99. doi: 10.23922/jarc.2017-018.
4. Goligher JC, ed. Hemorrhoids or piles. In: *Surgery of the Anus, Rectum and Colon.* 4th ed. London: Bailliere Tindall;1980:93-135.
5. Roka S, Gold D, Walega P, Lancee S, Zagriadsky E, Testa A, et al. DG-RAR for the treatment of symptomatic grade III and grade IV haemorrhoids: a 12-month multi-centre, prospective observational study. *Eur Surg.* 2013 ;45(1):26-30. doi: 10.1007/s10353-012-0182-8.
6. Wilkerson PM, Strbac M, Reece-Smith H, Middleton SB. Doppler-guided haemorrhoidal artery ligation: long-term outcome and patient satisfaction. *Colorectal Dis.* 2009;11(4):394-400. doi: 10.1111/j.1463-1318.2008.01602.x.
7. Morinaga K, Hasuda K, Ikeda T. A novel therapy for internal hemorrhoids: ligation of the hemorrhoidal artery with a newly devised instrument (Moricorn) in conjunction with a Doppler flowmeter. *Am J Gastroenterol.* 1995;90(4):610-3.
8. Gupta PJ, Kalaskar S, Taori S, Heda PS. Doppler-guided

- hemorrhoidal artery ligation does not offer any advantage over suture ligation of grade 3 symptomatic hemorrhoids. *Tech Coloproctol.* 2011 ;15(4):439-44. doi: 10.1007/s10151-011-0780-7.
9. Saxena P, Bhakuni YS. A prospective study on suture ligation of internal hemorrhoids without Doppler guidance for the treatment of symptomatic hemorrhoid disease. *International Surgery Journal.* 2017;4(2):671
 10. Hussain SM, Azim MT, Saleem MM, Sajid MT, Mughal MA, Ahmed A. Experience with Haemorrhoidal artery ligation under direct vision at a tertiary care hospital: A case series. *J Pak Med Assoc.* 2020 ;70(6):1089-1093. doi: 10.5455/JPMA. 300504.
 11. Shabbir H, Majeed F A, Raza A, Bashir U, Cheema M S, Shabbir A, et.al. Effectiveness of haemorrhoidal artery ligation via palpatory. *Pak Armed Forces Med J* 2020; 70 (4): 944-48.
 12. Qamar Naqvi SR, Qamar Naqvi SS, Rashid MM, Sheikh IA, Ali M, Nafees AUA. Haemorrhoidal Artery Ligation Operation Without Doppler Guidance. *J Ayub Med Coll Abbottabad.* 2018 ;30(Suppl 1)(4):S664-S667.
 13. Nash GF, Cowie A, Godfrey AD. Haemorrhoidal artery ligation operation (HALO); Is doppler necessary? *Tech Coloproctol.* 2011;15:1123–6337.
 14. Schuurman JP, Borel Rinkes IH, Go PM. Hemorrhoidal artery ligation procedure with or without Doppler transducer in grade II and III hemorrhoidal disease: a blinded randomized clinical trial. *Ann Surg.* 2012 ;255(5):840-5. doi: 10.1097/SLA.0b013e31824e2bb5.
 15. Yeo D, Tan KY. Hemorrhoidectomy - making sense of the surgical options. *World J Gastroenterol.* 2014 ;20(45):16976-83. doi: 10.3748/wjg.v20.i45.16976.
 16. Avital S, Itah R, Skornick Y, Greenberg R. Outcome of stapled hemorrhoidopexy versus doppler-guided hemorrhoidal artery ligation for grade III hemorrhoids. *Tech Coloproctol.* 2011 ;15(3):267-71. doi: 10.1007/s10151-011-0699-z.