

Indicators of a Poor Outcome after Temporary Pacing in Patients with Complete Atrioventricular Block

Uzma Kazmi¹, Syed Najam Hyder ², Abdul Malik Sheikh³, Ahmed Usaid Qureshi⁴, Hina Sattar⁵, Masood Sadiq⁶

Abstract:

Background: Temporary pace maker (tpm) implantation is an emergency procedure, performed in symptomatic patients with AV block. We report our experience of temporary pacing at a tertiary care center. It is the first study of its type from a local center.

Objectives: To study the clinical course of patients after tpm implantation and to determine indicators of a poor outcome after tpm implantation.

Methods: This was descriptive retrospective study. Data of all tpm procedures performed at Children Hospital from 2006 to 2012 was retrieved. We excluded patients with surgically placed tpm leads. All patients receiving transvenous tpm were included in our study.

Results: Total of 12 patients received tpm, 8 were male (66.6%) and 4 were female (33.3%). Median age was 6 years (range 1.4 - 13 year). Mean weight was 30kg, (range 8.7 - 50kg). All of them presented with complete heart block.

Sadiq M⁶

Children Hospital Lahore, Pakistan.

One patient each had post diphtheria cardiomyopathy, unknown poisoning. The rest had congenital heart block. The mean period between tpm to ppm implantation was 5 days, (range 1 - 30 days). One patient spontaneously reverted to sinus rhythm (8.3%), 6 had ppm implantation (58.3%), 5 patients expired (33.3%). A low Ejection Fraction was found to be associated with a poor outcome ($p < 0.01$). Variables that were associated with a poor outcome (mortality), were SOB ($p < 0.015$), weak pulses ($p < 0.015$), and hepatomegaly ($p < 0.01$).

Conclusion; Low Ejection Fraction and Heart failure is associated with a poor outcome and increased mortality in patients with complete AV block. We suggest that pacing should be considered in patients earlier, before they develop signs or symptoms of cardiac dysfunction.

Keywords; children, complete heart block, temporary pace making

K Uzma¹

Children Hospital Lahore, Pakistan.

Hyder SN²

Children Hospital Lahore, Pakistan.

Sheikh A.M.³

Children Hospital Lahore, Pakistan.

Qureshi A.U.⁴

Children Hospital Lahore, Pakistan.

Sattar H⁵

Children Hospital Lahore, Pakistan.

Introduction:

Temporary pace maker (tpm) implantation is an emergency procedure⁽¹⁾. It is indicated in⁽²⁾ patients with third degree AV block (also called complete heart block), advanced second degree AV block, or sinus node dysfunction who develop symptoms, like dizziness, syncope, shortness of breath, and heart failure⁽³⁾ if permanent pace maker (ppm) is not immediately available. Cardiac pacing relieves symptoms and improves working capacity.⁽⁴⁾

Patients with complete heart block are otherwise scheduled for ppm implantation, when indicated. We report our experience of temporary pacing from a tertiary care center. It is the first study of its type from a local center.

Objectives:

1. To study the clinical course of patients after tpm implantation
2. To determine indicators of a poor outcome after tpm implantation.

Material and methods:

This was descriptive retrospective study. Data of all tpm procedures performed at CH & ICH from 2006 to 2012 was retrieved. We excluded those patients who received transcutaneous surgically placed tpm leads. Those who received permanent pace maker electively were also excluded. All those patients who received transvenous tpm were included in our study. We received details of 12 such patients, which formed the studied cohort. The clinical records of these patients were reviewed to document demographics, presentation, pre-procedure state, pre procedure investigations (ECG and echocardiography) procedural detail and post procedure course.

Statistical analysis:

Percentages and median with range were calculated for continuous variables. The chi square test was used for comparative analysis where appropriate. A p value of less than 0.05 was taken as significant.

Procedural Detail:

All the procedures were performed under fluoroscopic control. Right subclavian vein was used for access in 10 patients and right femoral vein in 2 patients. tpm lead was anchored in rvot in 3 patients and RV wall in 2 patients. In the

rest, RV apex was the site where tpm lead was placed.

Results:

Total 12 patients received tpm. 8 were male (66.6%) and 4 were female (33.3%). Their mean age was 6 years with a range of 1.4 to 13 years. Their mean weight was 30kg, with range of 8.7 to 50kg. (Table 1) All of them presented with third degree heart block secondary to various etiologies. One patient had post diphtheria cardiomyopathy, one came with unknown poisoning. The rest of the patients had congenital heart block. Eleven patients had structurally normal hearts (84%), 1 had an additional atrial septal defect (8.3%). The mean period between tpm to ppm implantation was 5 days, ranging from 1 to 30 days. One patient developed infection (tip of tpm lead culture was positive for E coli), 1 had accidental removal of tpm lead, 1 patient who presented with unknown poisoning spontaneously reverted to sinus rhythm (8.3%), 6 had ppm implantation (50%) while 5 patients expired (41.6%) (Figure 1) Continuous variables included age, weight, time period between tpm and ppm implantation and ejection fraction on echocardiogram. It was not significantly affected by weight, age or the procedure technique. A low EF was found to be associated with a poor outcome ($p < 0.01$). The categorical variables included neurological signs and symptoms (fits, syncope, altered conscious level) hemodynamic features (weak pulse, hepatomegaly, SOB), and ECG features (QRS morphology). Neurological signs and symptoms and ECG features were not found to be significantly affecting the outcome. Variables that were associated with a poor outcome (mortality), were SOB ($p < 0.015$), weak pulses ($p < 0.015$), and hepatomegaly ($p < 0.01$) (Table 2 and Table 3)

Table 1: General characteristics of patients receiving tpm

characteristic	median	Range
Age(years)	6	1.4-13
Weight(kg)	30	8.7-50
Duration b/w tpm to ppm(d)	5	1-30

Figure 1: Outcome of Patients

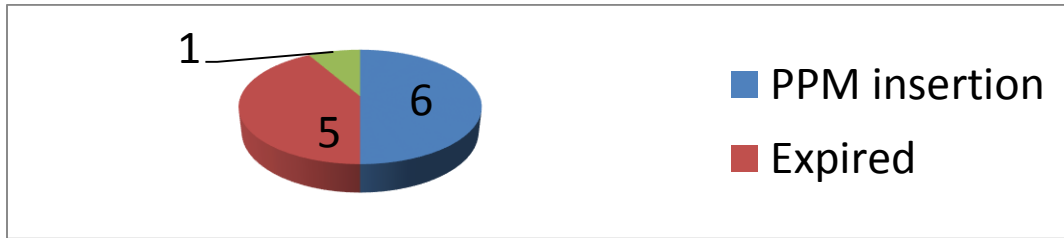


Table 2: Correlation of categorical variables with outcome

Symptoms		Outcome			P.Value
		Expired	PPm	Reverted sinus	
Liver	Not palpable	1(11.1%)	6(77.8%)	1(11.1%)	0.01
	Enlarged	4(100%)	0 (0%)	0(0%)	
Pulse	Normal volume	1(11.1%)	7(77.8%)	1(11.1%)	0.01
	Low volume	4(100%)	0 (0%)	0(0%)	
SOB	Yes	1(12.5%)	7(77.8%)	1(11.1%)	0.01
	No	4(100%)	0 (0%)	0(0%)	
Irritable	Yes	3(27.3%)	7(63.6%)	1(9.1%)	0.15
	No	2(100%)	0 (0%)	0(0%)	
Conscious	Normal value	3(33.0%)	6(66.7%)	0	0.18
	altered	2(50.0%)	1(25.0%)	1(25.0%)	
Fits	Yes	4(40%)	5(50%)	1(10%)	0.80
	No	1(33.3%)	2(66.7%)	0(0%)	
Syncope	Yes	2(40%)	3(60%)	0(0%)	0.70
	No	3(37.5%)	4(50%)	1(12.5%)	

Table 3: Correlation of Ejection Fraction with Outcome

		outcome			Total
		expired	ppm	reverted sinus	
EF	>56%	1	7	1	9
		11.1%	77.8%	11.1%	100.0%
	<56%	4	0	0	4
		100.0%	.0%	.0%	100.0%
Total		5	7	1	13
		38.5%	53.8%	7.7%	100.0%

P value is 0.01 significant

Discussion:

Pediatric cardiac pacing has evolved into its own subspecialty over the past decade.⁽⁵⁾With advancement in our expertise in diagnosis, management and icu care an increasing number of patients is receiving temporary and permanent pace makers. Pacemakers have been implanted in pediatric patients since the late 1960s. Indications for cardiac pacing in infants and children have evolved to include controlling symptoms as well as providing a life-sustaining

cardiac rhythm. In pediatric patients , especially with a structurally normal heart, symptoms related to primary bradycardia are relatively uncommon, except when there is limited ability to increase the ventricular rate during stress or exercise. Beyond neonatal age patients may present with varying degrees of exercise limitation or syncope. In pediatric patients, especially with a structurally normal heart, symptoms related to primary bradycardia are relatively uncommon, except when there is

limited ability to increase the ventricular rate during stress or exercise. . Some patients with isolated complete AV block develop dilated cardiomyopathy.⁽⁶⁾ Beyond neonatal age patients may present with varying degrees of exercise limitation or syncope. The aim of our study was to observe the post procedure clinical course of those patients who received temporary trans venous pacemaker, with reference to complications and outcome in our setup. Only one patient spontaneously reverted to sinus rhythm. This patient developed complete AV block secondary to poisoning. Her history was strongly suggestive of drug ingestion. Many studies suggest that drug induced AV block can be reversible, once the offending drug is removed.⁽⁷⁾ The use of antibiotics and ultrasound probes must be contemplated for all wire insertions.⁽⁸⁾ The same patient developed infection. E coli growth was obtained from tpm wire tip after removal. The patient was treated with systemic antibiotics and remained vitally stable and in sinus rhythm throughout stay(after reversion).6 patients received ppm. Their clinical course was uneventful. And no significant morbidity was detected. 5 patients expired. . One of them had tpm lead displacement, the lead was readjusted. This patient waited for nearly a month before ppm could be arranged and implanted. Four of them had signs and symptoms suggestive of cardiac failure. Ejection fraction was subnormal on echo. There are other studies also showing that predictors of complications in cases receiving tpm were restlessness, cardiovascular risk factors, and insertion through the jugular or subclavian vein.⁽⁹⁾ Other studies show that Congestive heart failure prior to implantation portend a poor survival.^{(10),(11)}

Conclusion:

Low ejection fraction and Heart failure is associated with a poor outcome and increased mortality in patients with complete AV block. We suggest that pacing should be considered in patients earlier, before they develop signs or symptoms of cardiac dysfunction.

References:

1. Prince JK, Frank AF. Atrioventricular Block. In: Allen HD, Shaddy RE, Driscoll

MD (ed). Moss and Adams Heart Disease in Infants, children and adolescents. Lippincot, Philadelphia 2008. pp 303-6.

2. Kouchoukos NT, Blackstone EH, Doty DB, et al Bradycardia. In Cardiac Surgery orphology, diagnostic criteria, natural history, techniques, results, and indications. 3rd ed. Philadelphia 2003. pp 1630-33
3. Drochner U. Indications spectrum for temporary and permanent cardiac pacemaker therapy. *Z Gerontol.* 1994 Sep-Oct;27(5):337-40.
4. Ceconi M, Renzi R, Bettuzzi MG, Colonna P et al Congenital isolated complete atrioventricular block: long-term experience with 38 patients *G Ital Cardiol.* 1993 Jan;23(1):39-53.
5. Sliz NB Jr, Johns JA Cardiac pacing in infants and children *Cardiol Rev.* 2000 Jul-Aug;8(4):223-39.
6. Fazio G, Silveti MS, Drago F Pacemaker implantation in children: is this a therapy or a pathogenetic mechanism for ventricular dysfunction?]. *G Ital Cardiol (Rome).* 2006 Sep;7(9):612-7.
7. Osmonov D, Erdinler I, Ozcan KS Pacing *Clin Electrophysiol.* Management of patients with drug-induced atrioventricular block. . *Pacing Clin Electrophysiol.* 2012 Jul;35(7):804-10.
8. McCann P. A review of temporary cardiac pacing wires. *Indian Pacing Electrophysiol J.* 2007 Jan 1;7(1):40-9.
9. Muñoz Bono J, Prieto Palomino MA, Macías Guarasa I *Med Intensiva.* Efficacy and safety of non-permanent transvenous pacemaker implantation in an intensive care unit *Med Intensiva* 2011 Oct;35(7):410-6.
10. Stangl K, Wirtzfeld A, Alt E 30 years cardiac pacemaker therapy: a status evaluation *Z Kardiol.* 1990 Jun;79(6):383-95.
11. Simon AB, Janz N Pacing Symptomatic bradyarrhythmias in the adult: natural history following ventricular pacemaker implantation. *Clin Electrophysiol.* 1982 May;5(3):372-83.