

Research Article

Semitendinosus Tendon Graft for Hand Tendon Reconstruction

Hassan Tahir,¹ Shehab Afzal Beg²

^{1,2}Department of Plastic and Reconstructive Surgery, Liaquat National Hospital, Karachi

Abstract

Background: Hand tendon reconstruction is required in both acute and chronic tendon injuries. A number of donor sites have been described; one such novel donor site is semitendinosus tendon used a graft for hand tendon reconstruction. Based on data reviewed, only a few cases are described up till now.

Objective: Utility of semitendinosus tendon graft with adequacy of tendon material for hand tendon reconstruction and minimal donor site morbidity

Methods: Semitendinosus tendon was utilized in total of 18 patients undergoing tendon reconstruction for chronic tendon injuries and for tendon transfer to achieve adequate length. All cases were performed during January 2019 To December 2020. Full length uni/bilateral semi-tendinosus tendon was harvested using a tendon harvester. Tendon was used as a single slip or was split into further slips as needed for tendon reconstruction. Post operatively splints were continued as per protocol (keeping splint for 6 weeks, encouraging active physiotherapy at 8 weeks, continuing night splintage for total of 10 weeks and advising patient to avoid lifting heavy weight for at least 12 weeks). Patients were followed with assessment of strength via MRC (Medical Research Council) grading scale, and tendon excursion measurements via tip to palm distance.

Results: Patients had a mean age for 27.5 ± 2.3 with a predominant male population (72.2%). Post-operative assessment showed finger strength of MRC 5 in twelve patients and MRC 4 in three and MRC 3 in three patients. Tendon excursion was documented measuring a tip to palm distance. Three patients developed tendon adhesions which were treated with tenolysis.

Conclusion: Semitendinosus is a recommended option for hand tendon (both flexor & extensor) reconstruction, providing adequate length & strength for reconstruction with high predictable availability and reliability. Although Palmaris longus remains the recommended option for single tendon reconstruction, it is absent in a few cases or is rudimentary, making it difficult to be utilized.

Corresponding Author | Dr. Hassan Tahir, Department of Plastics and Reconstructive Surgery, Liaquat National Hospital Karachi. **Email:** h.tahir1992@gmail.com

Keywords | Semitendinosus, tendon reconstruction, tendon graft, MRC, tip to palm distance.

Introduction:

Hand trauma is a common presentation to emergency room, constituting between 6.6 and 28.6% of all musculoskeletal injuries^{1,2,3,4} leading to extreme morbidity to the patient and their families. Tendon and ligamentous injuries are commonly seen after trauma. Many of these injuries which cannot be repaired primarily

and so need reconstruction with a tendon graft. Few of these include biceps tendon reconstruction, rotator cuff reconstruction, ACL & PCL of knee reconstruction.^{5,6} In many of such cases, patients encounter tendon injuries to both flexors and extensors of hand. In patients with nerve injuries (including both direct/indirect and acute/chronic) tendon transfers are routinely performed to restore hand function.^{7,8} These always need to be recon-

structed with either autologous or artificial tendon grafts. Of the available autologous options include Palmaris longus, plantaris, and Tensor fascia lata.⁹ Hand tendon reconstruction is required in both acute and chronic tendon injuries. For multiple tendon reconstruction there comes a need for multiple tendon graft of adequate length and strength. This cannot be done using conventional tendon grafts as these do not provide adequate length, strength and size.¹⁰ Although Artificial graft for ligament reconstruction are commonly used in orthopedic practice for knee and shoulder ligament reconstruction, there are a number of ongoing studies on tendon reconstruction using hydrogel polymers, synthetic and natural fibers processed via different techniques.^{11,12,13} Apart from these conventional options available for tendon reconstruction recently semitendinosus tendon is gaining popularity for both flexor and extensor tendon reconstruction.^{14,15} Tendon graft of good length & strength as defined by M.Ozbydar et al was, a minimum length of 15cm with diameter of 3mm or length of 30cm with a diameter of 1.5mm.¹⁵ To our knowledge only a few cases our described up till now.^{14,15,16} We utilized semitendinosus tendon with the aim that it will replace other option due to its reliability in means of length, strength & size, and availability in all patients.

Methods:

This Case series was conducted at the Department of Plastic and Reconstructive surgery, Liaquat National Hospital, Karachi, Pakistan. All patients undergoing hand tendon reconstruction during January 2019 to December 2020 with acute/chronic tendon injuries of either flexor or extensor tendon presenting to us were included in the study via convenience sampling technique. Patients with complex injuries, crush injuries etc. to the hand were excluded from the study. Data were collected on a routine OPD audit proforma & operative notes, relevant pictures were taken after taking written and informed consent from patients, keeping patient identity and details confidential.

Full length semitendinosus tendon was harvested either unilaterally or bilaterally as required for hand tendon (flexor & extensor) reconstruction for acute/chronic tendon injuries and for tendon transfer to achieve adequate length. All cases were performed by the same surgeon, using same technique. Small oblique skin incision is made mid-way between the tibial tubercle

and the posterior edge of the tibia. After careful dissection semitendinosus tendons was identified and harvested proximally using a tendon stripper (Figure 1). Tendon was then used as a single slip or divided into further slips as needed for tendon reconstruction. Post operatively splints were continued as per protocol (keeping splint for 6 weeks, encouraging active physiotherapy at 8 weeks, continuing night splintage for total of 10 weeks and advising patient to avoid lifting heavy weight for at least 12 weeks). Patients were followed with proper documentation of strength via MRC grading (Table 1), and tendon excursion via tip to palm distance. Mean MRC grade and tip to palm distance (Figure 2) were calculated.

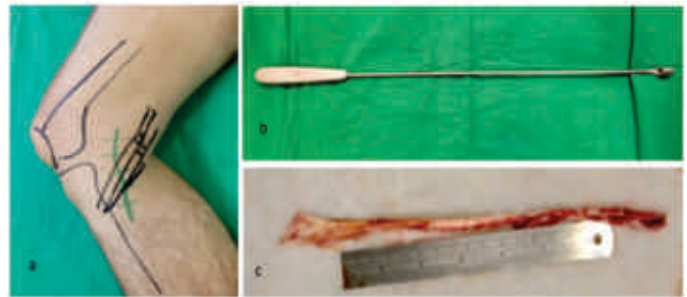


Figure 1: Demonstrates a) Marking for Tendon Harvest, b) Tendon Harvester, c) Harvested Semitendinosus Tendon

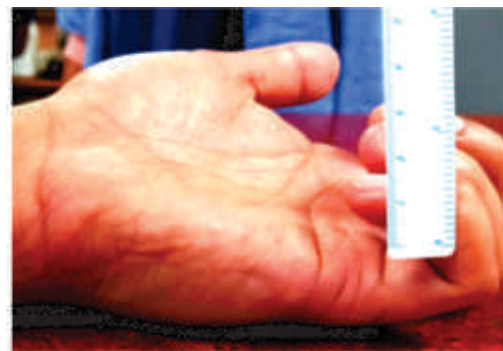


Figure 2: Demonstrating Method of Measuring Tip to Palm Distance

Results:

Patients included in our study had a mean age for 27.5 ± 2.3 with a predominant male population (72.2%). Among the study population 72.2% were right hand dominant and 27.8% were left hand dominant, which were the involved limbs in respective patients. Occupations that encountered hand tendon injuries in our study population were driver, athletes, laborer, carpenter and machine operators. Injury mechanism included

Table 1: MRC grades for motor strength

MRC grade	Description
Grade 0	No contraction
Grade 1	Flicker or trace of contraction
Grade 2	Active movement with gravity eliminated
Grade 3	Active movement against resistance
Grade 4	Active movement against gravity and resistance
Grade 5	Normal power

both nerve and tendon injuries secondary to sharp cut injuries, sports injuries, underlying bone fracture leading to nerve injury, gunshot injuries causing both nerve and tendon injuries. In grossly contaminated wounds or wounds with obvious risk of infection reconstruction was done once wounds were healthy with documented evidence of negative wound cultures. Unilateral semitendinosus tendon was harvested in 12 patients and bilateral in 6 patients. Mean tendon length harvested was around 27cm(\pm 1.5cm) (Table 2).

Table 2: Patient demographics

Gender	Male	13
	Female	5
Age		27.5 \pm 2.3
Injured hand	Right	15
	Left	3
Co-morbid conditions		None
Occupation	Driver	2
	Athlete	3
	Laborer	4
	Carpenter	2
	Machine operator	4
	Butcher	3
Mechanism of injury	Underlying bone fracture	3
	Sports injury	1
	Fall of heavy object	2
	Gunshot injury (nerve injury)	4
	Sharp cut injury	8
Time since injury		28 days (SD \pm 5days)
Zone of injury	Flexor	4 and 5
	Extensor	6,7 and 8
Nerve Injury		6
Tendon transfer		3
Tendon harvest	Unilateral	06
	Bilateral	12

Post-operative assessment showed finger strength of MRC 5 in twelve patients, MRC 4 in three and MRC 3

in three patients. Mean MRC strength was 4.5 (Table 3).

Table 3: MRC grade achieved after tendon reconstruction.

MRC grade	No. of patients	Percentage of patients
Grade 1	0	0
Grade 2	0	0
Grade 3	3	16.66%
Grade 4	3	16.66%
Grade 5	12	66.66%
Mean MRC strength = 4.5		

Tendon excursion was documented measuring a tip to palm distance (Table 4). Three patients developed tendon

Table 4: Tip to palm distance pre-operatively and post operatively

Tip to palm distance [cm]	Pre operatively	3.0cm (SD\pm0.75)
		Post operatively

adhesion which was treated with tenolysis. Fortunately, there were no drop outs from the study and all patients were compliant to follow up on outpatient basis up till 12 weeks post-operatively on weekly basis and then on fortnightly basis for next 3 months.

Discussion:

Tendon reconstruction has always been a challenge to reconstructive surgeon, in means of availability and reliability of donor options. Donors such as plantaris and Palmaris longus are most commonly used but these are not reliable option, both in means of availability and strength.

Our study demonstrated that utilizing semitendinosus tendon graft can be feasible for reconstruction in a number of cases whether it be interposition graft in tendon transfer or tendon reconstruction in cases with chronic retracted tendon injuries. Semitendinosus tendon provides excellent length, strength and ease of harvest with minimal donor site morbidity.¹⁴ Tendon was harvested in a conventional manner with the aim to harvest maximum length.¹⁷ Tendon reconstruction was done as described previously. Twelve patients achieved MRC grade 5, three patients achieved MRC grade 4 and three patients achieved MRC grade 3 (mean MRC 4.5) which suggests that it is also a good tendon graft in means of strength.

Tip to palm distance was also measured, showing that

there was no loss of strength/lengthening of the tendon graft. Only three patients developed tendon adhesions which were treated with tenolysis. There was no donor site morbidity in our study. All patients were followed as per the defined protocol.

When compared to other available autologous and alloplastic options used now a days for single or two stage reconstruction of the tendons, the semitendinosus tendon provides predictable length & strength, and less chances of infection when compared to alloplastic options.¹⁸

As already mentioned, that there were no drop outs from the study and all patients were compliant to follow up, the results are strengthened by the fact that we achieved 100% results in all means i.e. availability, reliability, length and strength with no donor site morbidities. In light of these benefits, semitendinosus tendon graft can be preferentially used for tendon reconstruction where feasible. As this was a single center study, it is limited in means of data and number of grafts used in patients. Also, the need to harvest the semitendinosus tendon from another anatomical site may add to morbidity to the patient, although there were no donor site morbidities reported in our study.

Conclusion:

Semitendinosus is a recommended option for hand tendon (both flexor & extensor) reconstruction, providing adequate length & strength for reconstruction with high predictable availability & reliability with minimum donor site morbidity. Although *Palmaris longus* remains the recommended option for single tendon reconstruction, it is absent in a few cases or is rudimentary, making it difficult to be utilized. When compared to other available autogenous and alloplastic options, semitendinosus tendon appears to be the most feasible option. Although it is a well defined option in knee ligament (ACL/PCL) reconstruction, further studies are needed to highlight its usefulness in hand tendon reconstruction, especially in cases multiple tendon injuries.

Ethical Approval: Given

Conflict of Interest: The authors declare no conflict of interest.

Funding Source: None

References:

1. Junqueira GD, Lima AL, Boni R, Almeida JC, Ribeiro RS, Figueiredo LA. Incidence of acute trauma on hand and wrist: a retrospective study. *ActaOrtop Bras*. 2017; 25(6):287-90
2. de Jong JP, Nguyen JT, Sonnema AJ, Nguyen EC, Amadio PC, Moran SL. The incidence of acute traumatic tendon injuries in the hand and wrist: a 10-year population-based study. *Clinics in orthopedic surgery*. 2014 Jun 1; 6(2):196-202.
3. Arroy-Berezowsky C, Quinzanos-Fresnedo J. Epidemiology of hand and wrist injuries treated in a reference specialty center over a year. *Acta Ortop Mex*. 2021; 35(5): 429-435. <http://dx.doi.org/10.35366/104570>.
4. Ahmad A, Memon SF, Khan AA, Memon SA, Jalees S, Khan S, Shaukat B. Patterns of peripheral nerve and tendon injury in hand trauma patients in a tertiary care hospital of Pakistan. *Cureus*. 2021 Jan 24;13(1).
5. McCarty LP, Alpert JM, Bush-Joseph C. Reconstruction of a chronic distal biceps tendon rupture 4 years after initial injury. *Am J Orthop (Belle Mead NJ)*. 2008 Nov 1;37(11):579-82.
6. Hang DW, Bach BR, Bojchuk J. Repair of chronic distal biceps brachii tendon rupture using free autogenous semitendinosus tendon. *Clinical Orthopaedics and Related Research*. 1996 Feb 1;323:188-91.
7. Abd-Almuktader Abdel-Kreem MA. Evaluation of tendon transfer for radial nerve palsy. *Al-Azhar International Medical Journal*. 2020 Aug 1;1(3):113-20.
8. Tanis PJ, Poelhekke LM, Schreuders TA, Hovius SE. Tendon transfers to restore hand function following peripheral nerve injury in the arm. *Nederlands tijdschrift voor geneeskunde*. 2000 Apr 1;144(18):825-30.
9. Alagoz MS, Uysal AC, Tuccar E, Tekdemir I. Morphologic assessment of the tendon graft donor sites: palmarislongus, plantaris, tensor fascia lata. *Journal of Craniofacial Surgery*. 2008 Jan 1;19(1):246-50.
10. Jakubietz MG, Jakubietz DF, Gruenert JG, Zahn R, Meffert RH, Jakubietz RG. Adequacy of palmarislongus and plantaris tendons for tendon grafting. *The Journal of hand surgery*. 2011 Apr 1;36(4):695-8.
11. Abdullah S. Usage of synthetic tendons in tendon reconstruction. *BMC Proceedings*. 2015;9(S3):1-2
12. Santos ML, Rodrigues MT, Domingues RM, Reis RL, Gomes ME. Biomaterials as tendon and ligament substitutes: current developments. *Regenerative strategies for the treatment of knee joint disabilities*. 2017:349-71.
13. Hua M, Wu S, Ma Y, Zhao Y, Chen Z, Frenkel I, et al. Strong tough hydrogels via the synergy of freeze-casting and salting out. *Nature*. 2021 Feb;590(7847):594-9.
14. Low N, Fahy ET, Frisken J, Mann N. An alternate graft for staged flexor tendon reconstruction. *Hand*. 2015

- Mar;10(1):152-4.
15. Ozbaydar M, Orman O, Ozel O, Altan E. Multiple extensor tendons reconstruction with hamstring tendon grafts and flap coverage for severe dorsal hand injuries. *Hand surgery and rehabilitation*. 2017 Dec 1; 36(6): 410-5.
 16. Tym Frank, Anna Selter, Ruby Grewal, Graham J.W. King, George s. Athwal, management of Chronic distal biceps tendon ruptures: primary repair vs. semitendinosus autograft reconstruction, *Journal of Shoulder and Elbow Surger* 2019;28(6):1104-1110, ISSN 1058-2746, doi.org/10.1016/j.jse.2019.01.006.
 17. Stergios PG, Georgios KA, Konstantinos N, Efthymia P, Nikolaos K, Alexandros PG. Adequacy of semitendinosus tendon alone for anterior cruciate ligament reconstruction graft and prediction of hamstring graft size by evaluating simple anthropometric parameters. *Anatomy research international*. 2012;2012:1-5
 18. Bansal A, Lamplot JD, VandenBerg J, Brophy RH. Meta-analysis of the Risk of Infections After Anterior Cruciate Ligament Reconstruction by Graft Type. *Am J Sports Med*. 2018 May;46(6):1500-1508. doi: 10.1177/0363546517714450. Epub 2017 Jul 24. PMID: 28737955.