

Case Report

An Adult Male with Bochdalek Hernia—A Case Report

Fakiha Bukhari,¹ Hajrah Hilal Ahmed,² Kanwal Irshad,³ Muhammad Jamaluddin⁴

¹⁻⁴Abbasi Shaheed Hospital, Karachi

Abstract

Bochdalek hernia results due to failure of pleuroperitoneal membranes to fuse completely before birth, resulting in a defect in left posterior diaphragm through which abdominal organs can herniate into thorax. It is a congenital condition and is common in infants and children. It is rarely present in adults. We present a case of a twenty five year old adult male presenting with a 2 day history of sharp epigastric and left hypochondriac pain and 1 month history of non-bloody, non-projectile vomiting. An X-ray Abdomen was done showing signs of small bowel obstruction (SBO) with eventration of diaphragm and mediastinal shift. Upon surgical approach, a Bochdalek hernia defect was seen in left posterolateral diaphragm. Patient was successfully treated with laparotomy and mesh repair without any perioperative and postoperative complications.

Corresponding Author | Dr. Hajrah Hilal Ahmed, Abbasi Shaheed Hospital, Karachi, **Email:** hajrahilal@gmail.com

Keywords | Bochdalek hernia, Congenital Diaphragmatic Hernia, Surgical mesh repair, Laparotomy

Introduction

Bochdalek hernia, a type of Congenital Diaphragmatic hernia (CDH), results due to intrauterine failure of pleura-peritoneal membranes to fuse completely, resulting in a defect in posterolateral part of diaphragm. It is common in infants and children but its presentation in adults is rare.¹

Features of this type of hernia are different in both children and adults, with children presenting with acute respiratory distress and adults complaining of chronic history of recurrent and intermittent GI problems. However, some adults are diagnosed accidentally on routine workup.²

Treatment is mainly surgical intervention. A reduced morbidity has been seen in cases where minimal invasive surgeries have been performed.³

Case Report:-

A twenty five year young adult male presented to Emergency department of Abbasi Shaheed Hospital on 6th June' 2021 with abdominal pain since 2 days, non-bloody, non-projectile vomiting since 1 month. He complaint

of sharp epigastric and left hypochondriac pain aggravated by eating spicy foods relieved by taking omeprazole. He had experienced similar pain few times in last 2 years which were relieved when he took analgesics. However, the pain increased in severity 1 month ago, associated with intermittent constipation, postprandial bloating, heartburn, on and off chest pain, vomiting and nausea. There was no history of abdominal or thoracic trauma, abdominal surgery and no complain of fever, cough, dyspnea, and melena or weight loss.

On Examination, a normal built person was seen, lying uncomfortably in his bed. He was vitally stable. Abdominal distension was seen, upper abdomen was guarded and tender. Gut sounds were audible. Respiratory examination was unremarkable.

Abdominal X-ray was suggestive of Small bowel obstruction. An NG tube decompression was performed which resulted in passage of stools. Post-decompression X-ray showed eventration of left diaphragm (Figure 1) for which further investigations were done. CT scan chest, abdomen and pelvis showed a defect on left posterior part of the left hemidiaphragm with herniation

of abdominal organs into thorax (Figure 2). The diagnosis of left Bochdalek Hernia (BH) was made.

As the patient was vitally stable without any active complaints, an elective transabdominal laparotomy with prolene mesh repair was planned. On exploration, a 12×12 cm sized defect was observed suggestive of Bochdalek hernia. The hernial contents consisting of omentum, stomach, spleen, transverse colon, splenic flexure and left kidney, were reduced with 15×15cm prolene mesh placed between thorax and abdomen. A drain was placed in abdominal cavity and left sided chest. The post-operative period was unremarkable, drain was removed on 5th POD and patient was discharged on 6th POD. Post-op follow up was unremarkable. Postoperative CXR was normal. (Figure 3).

Discussion

There are 2 types of congenital diaphragmatic hernia, Bochdalek and Morgagni hernia. Although Morgagni Hernia is common in adults, we report a case of Bochdalek hernia in a 25-year-old man. 2 BH is the most common type of CDH with its incidence in newborns being 1 in 2200 to 1 in 12,500 live births however, its occurrence in adults is rare with its incidence reported as 0.17%.³ Asymptomatic BH occurs in adults in 6% of cases.¹ However, our patient was symptomatic and presented with SBO which was relieved by NG tube decompression in ED.

Left BH is 80-90% more common than right sided hernia. This may be because the left pleuroperitoneal canal closes later than right side or it may be due to presence of liver on right side which occludes the foramen of Bochdalek (if present).⁴

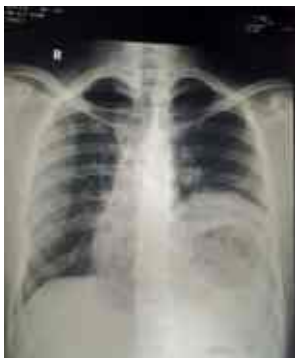

Figure 1: Preop CXR showing eventration of left diaphragm

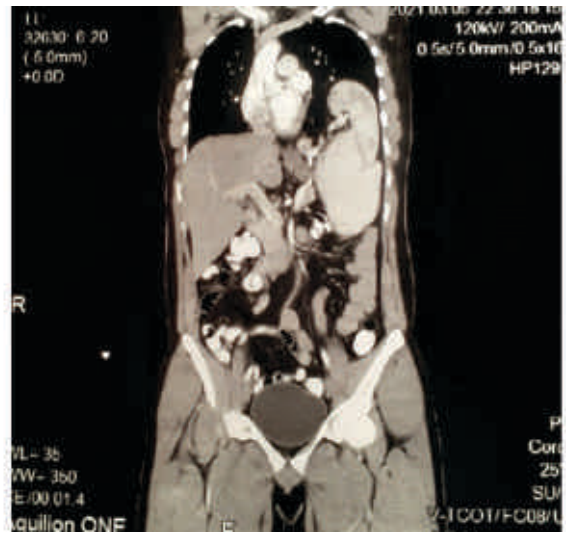


Figure 2: CT Scan Chest, Abdomen & Pelvis showing abdominal organs in thorax

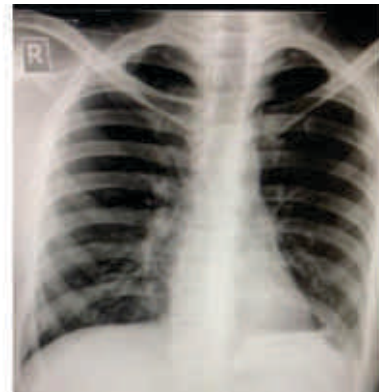

Figure 3: Post-Op CXR showing normal diaphragm

The hernia sac may contain colon (in half of the cases), small bowel, stomach, omentum and liver.¹ Our patient also had a spleen in his hernia which is an uncommon finding.³ Intra-operatively, left kidney was found in our patient's hernia sac which is extremely rare with it forming <5% of all causes of ectopic kidneys.⁵

Our patient presented with a 2 year history of chronic, intermittent abdominal pain. Adults with BH are mostly asymptomatic or present with chronic atypical GI and respiratory problems such as abdominal and chest pain, postprandial fullness, shortness of breath.⁶ Our patient presented with symptoms of SBO which can occur in 36% cases.³ The respiratory symptoms observed were non-specific.

Prognosis of BH in adults and neonates is different with adults having a higher chance of being cured than neonates as the underdeveloped lung may get compressed by abdominal organs leading to pulmonary hypoplasia.⁴

Definitive treatment of Bochdalek hernia is surgery. Immediate surgery should be done in patients in order to avoid development of grave complications such as intestinal obstruction,⁷ and bowel necrosis.¹ Strangulation of herniated organ occurs in 18% cases and is considered the most deadly complication of BH.⁴

Transabdominal, transthoracic or combined approaches are recommended. Abdominal approach is usually done when respiratory complications are absent⁸ and it is preferred by most surgeons as it allows identification of any malformation of prolapsed viscera before its reduction.⁹ In cases of intestinal problems or SBO, abdominal approach is preferred over thoracic as it helps in rechecking and reconstructing the ischemic organs (if any).¹⁰ As our patient had minor respiratory complaints and presented with SBO, he was treated transabdominally. Not one approach has any benefit over the other approach as excellent results have been observed in all approaches.⁷

Principles of surgery involve identification of sac, reduction of abdominal contents and repair of defect by placement of mesh or muscle flap, application of sutures or simple primary repair. A prolene mesh was used in our patient due to easy availability and presence of a large defect. It was stitched with non-absorbable suture which is associated with less recurrence rates.⁸ Other mesh materials such as Physiomesh,⁶ Polytetrafluoroethylene and dual mesh³ are also used.

Diagnosis of adult BH is difficult as it is uncommon with 38% cases being misdiagnosed due to vague symptoms.³ The disease can be misdiagnosed as hydropneumothorax,⁹ eventration of diaphragm, pleural effusion and lung cysts.⁷ CXR should be done normally as it is sensitive in 70% cases. However, absence of abnormality does not exclude diagnosis.² Lateral and PA CXR views should be done.⁶ Chest CT is considered the most accurate.⁷ CT has a 78% sensitivity for left sided hernias and 50% sensitivity for right sided hernias.¹¹ Multi-dimensional CT Scan with multiplanar and three-dimensional imaging is preferred over normal CT scan as it helps in locating focal small sized defects.¹²

Conclusion

Occurrence of bochdalek hernia in adults is rare. Proper investigations should be carried out in symptomatic

patients before development of complications. Early surgical treatment is associated with low morbidity and mortality and must be carried out as soon as diagnosis is made.

References

1. Al-Dugdugi M, Alhazmi A, Khaliel A, Perez L. Bochdalek Hernia in an Adult with Upper Gastrointestinal Bleeding. *Case Rep Gastroenterol*. 2017;11(2):284-292.
2. Sharma B, Gupta D. Right Sided Bochdalek Hernia in Adult: A Case Report & Review of Literature. *Nepalese Journal of Radiology*. 2018 Jun 30;8(1):44-7.
3. Machado NO. Laparoscopic Repair of Bochdalek Diaphragmatic Hernia in Adults. *N Am J Med Sci*. 2016; 8(2):65-74.
4. Ohtsuka Y, Suzuki TH. Right-sided Bochdalek hernia in an elderly patient: a case review of adult Bochdalek hernias from 1982 to 2015 in Japan. *Acute Med Surg*. 2016;4(2):209-212.
5. Sarac M, Bakal U, Tartar T, Canpolat S, Kara A, Kazez A. Bochdalek hernia and intrathoracic ectopic kidney: Presentation of two case reports and review of the literature. *Niger J Clin Pract*. 2018;21(5):681-686.
6. Sutedja B, Muliani Y. Laparoscopic repair of a Bochdalek hernia in an adult woman. *Asian J Endosc Surg*. 2015;8(3):354-356.
7. Navakishore K, Sharma D, Gondu GR, Thumma VM, Gunturi SV, Reddy JM, et al. Surgical management of adult diaphragmatic hernia—an Institutional experience. *Int J Contemp Med Surg Radiol*. 2018;3:B54-7
8. Moro K, Kawahara M, Muneoka Y, et al. Right-sided Bochdalek hernia in an elderly adult: a case report with a review of surgical management. *Surg Case Rep*. 2017; 3(1):109.
9. Arya S, Shahab S, Kumar R, Garg PK. Adult Bochdalek Hernia with Organo-Axial Gastric Volvulus: Misdiagnosed as Hydropneumothorax. *Acta Medica (Hradec Kralove)*. 2018;61(3):108-110.
10. Toda M, Yamamoto A, Iwata T. Right-sided Bochdalek hernia containing retroperitoneal fat in the elderly: report of a case. *Surg Case Rep*. 2019;5(1):81.
11. National Center for Biotechnology Information [Internet]. [cited 2023 Apr 29]. Available from: <https://www.ncbi.nlm.nih.gov/books/NBK539767/>
12. Fazi J, Patel V, Bryan C. Bilateral Bochdalek Hernias Associated with Arnold-Chiari I Malformation. *Case Rep Radiol*. 2020;2020:1931879.