

Case Report

Transverse and Sigmoid Venous Thrombosis Presenting as Proptosis and Acute Loss of Vision: An Unreported Association

Uzma Malik,¹ Samavia Munir,² Muhammad Umer Mukhtar,³ Zahid Kamal,⁴ Sadaf Iftikhar⁵

^{1,3,4,5}KEMU/ Mayo Hospital, Lahore; ²Postgraduate Resident, Abington Hospital–Jefferson Health, USA

Abstract

Cerebral venous sinus thrombosis is a rare disorder characterized by thrombosis in the venous channels of the brain. Nonspecific symptoms such as headache, focal neurologic deficits and seizures make this condition difficult to diagnose. We describe a case of cerebral venous thrombosis in the sigmoid and transverse sinuses which presented as reversible, rapid-onset proptosis and loss of vision in a patient of subclinical hypothyroidism. Such an occurrence of proptosis due to thrombosis of the sigmoid and transverse sinuses has never been reported in literature. The diagnosis of cerebral venous thrombosis in this patient was arrived at in a stepwise fashion. Thus, this case in addition to reporting a novel finding, stresses by example, the importance of acute suspicion on part of the physician for timely diagnosis and treatment of this eluding yet reversible disease.

Corresponding Author | Dr. Muhammad Umer Mukhtar, King Edward Medical University, Lahore

Email: m.umermukhtar@kemu.edu.pk

Keywords | cerebral venous thrombosis, proptosis, subclinical hypothyroidism, case report

Introduction:

Cerebral venous sinus thrombosis (CVT) is a rare disorder caused by thrombosis in the cerebral venous channels. Symptoms of CVT include headache, focal neurologic deficits, and papilledema. Historically, such nonspecific symptoms made CVT notoriously difficult to diagnose, but now neuro-imaging techniques are present for diagnosis. CVT might cause ocular symptoms like papilledema and loss of vision but the occurrence of proptosis in CVT is extremely rare and has never been seen in association with thrombosis in the sigmoid and transverse sinuses. Here, we discuss a case of thrombosis in the sigmoid and transverse sinuses which presented as rapid onset, reversible proptosis, an association that has never been reported in literature.⁽¹⁾ Our case is also unique in the sense that it involves a patient of subclinical hypothyroidism presenting with proptosis, which is an unusual presentation.

Case Report:

A 32-year-old female patient presented with bulging and loss of vision in the left eye for three days. Affected eye had visual acuity of 6/60 and papilledema. The patient had been suffering from subclinical hypothyroidism and was being treated with thyroxine. Graves' ophthalmopathy can occur in hyperthyroid, euthyroid, or hypothyroid states and can manifest as proptosis and vision loss. On the basis of proptosis and vision loss, the patient was hastily misdiagnosed with Graves' ophthalmopathy by the ophthalmologist and therapy with methylprednisolone was started.

The patient had no alleviation of symptoms by the prescribed therapy and was referred to the endocrine clinic. The endocrinologist pointed out that a rapid onset of proptosis and vision loss is not consistent with Graves' ophthalmopathy which is characterized by a gradual development of ocular symptoms. MRI was obtained. MRI revealed normal extraocular muscles and no retro-orbital fat deposition (Figure 1). Swollen extraocular

muscles and retro-orbital fat are hallmarks of Graves' ophthalmopathy and so the results of MRI were inconsistent with the diagnosis of Graves' ophthalmopathy. B-scan showed tram track sign (Figure 2). Lumbar puncture showed a raised intracranial pressure (ICP). Rapid presentation of proptosis and loss of vision without a history of headache excluded idiopathic intracranial hypertension (IIH) as the cause of increased ICP. MRV showed left sigmoid sinus and left transverse sinus thrombosis in the brain. Enoxaparin and warfarin were started. Acetazolamide was administered and ventriculo-peritoneal shunting was done. These measures resulted in resolution of thromboses and lowering of ICP. The proptosis resolved and improvement of visual activity up to 6/9 was seen.

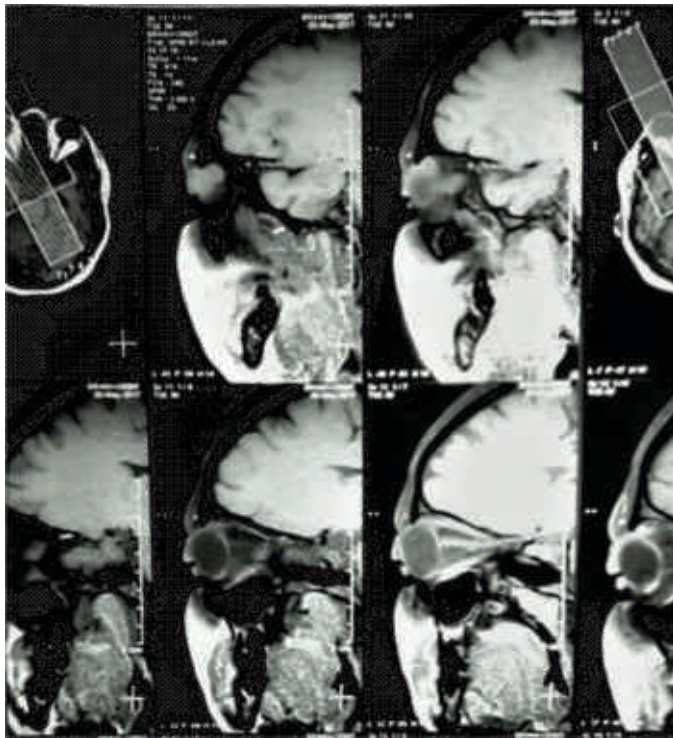


Figure 1: MRI Imaging Showing Normal Extraocular Muscles and Absence of Retro-Orbital Fat Deposition

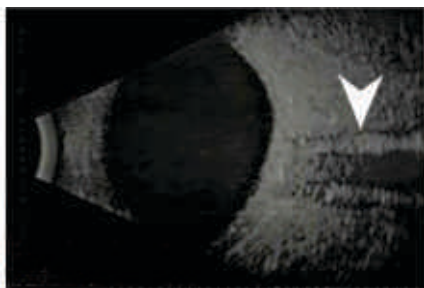

Figure 2: B-Scan. White Arrowhead Indicates Tram Track Sign

Discussion:

Headache is the most common symptom of CVT. Ocular symptoms include papilledema, loss of vision, and visual field defects. The mechanism of neuro-ophthalmic symptoms of CVT is related to the anatomical features of the eye: CVT results in blockage in the drainage of cerebral cortical veins leading increased ICP. At the same time, if superior sagittal sinus and transverse sinus are also thrombosed, the drainage of CSF via arachnoid granulations is also interrupted resulting in increased ICP. The raised ICP reflects onto the optic nerve and stops flow in the axoplasm causing inflammation and swelling. These pathogenic events caused by increased ICP ultimately lead to optic nerve dysfunction and neuro-ophthalmic findings.

Acute and reversible loss of vision as seen in our case has rarely been reported in literature. Yadegari et al. found an association between cavernous sinus thrombosis and proptosis. Past literature has established this same association between cavernous sinus thrombosis and proptosis. Besides this, there is no evidence of association of proptosis with thrombosis in any other venous sinus in the brain. Our patient had thrombosis in the left sigmoid and left transverse sinuses. Our case report is the first of its kind to report the occurrence of proptosis due to thrombosis in any sinus other than the cavernous sinus.

Our case highlights the fact that the physician must be vigilant about CVT, otherwise its diagnosis may be missed or delayed. In our case, the proptosis prompted the ophthalmologist to make a misconceived diagnosis of Graves' ophthalmopathy. Such rash diagnoses are common in countries like ours where the patient load is overwhelming and this practice needs to be discouraged. The rapid onset proptosis and vision loss was inconsistent with Graves' ophthalmopathy prompting the use of neuroimaging techniques like MRI, MRV and B-scan that ultimately led to the diagnosis of CVT. Anticoagulation therapy remains the mainstay of treatment of CVT and resulted in complete recovery in our patient.

Conclusion:

Our case is unique in the way that cerebral venous thrombosis presented as reversible, rapid-onset proptosis and loss of vision secondary to raised intracranial pressure

causing optic nerve dysfunction in a patient with sub-clinical hypothyroidism. Our case is the first to report the occurrence of proptosis in cerebral venous thrombosis of the sigmoid and transverse sinuses. Our case stresses the importance of acute suspicion on part of the physician for timely diagnosis and treatment of this awful yet reversible disease.

References:

1. Yadegari S, Jafari AK, Ashrafi E. Association of ocular findings and outcome in cerebral venous thrombosis. *Oman Journal of Ophthalmology*. 2017;10(3):173.
2. Aaron S, Arthur A, Prabakhar AT, Mannam P, Shyamkumar NK, Mani S, et al. Spectrum of visual impairment in cerebral venous thrombosis: importance of tailoring therapies based on pathophysiology. *Annals of Indian Academy of Neurology*. 2017 Jul;20(3):294.
3. Hayreh SS. Pathogenesis of optic disc edema in raised intracranial pressure. *Progress in retinal and eye research*. 2016 Jan 1;50:108-44.
4. Ray S, Khanra D, Sonthalia N, Saha M, Talukdar A. A case of cerebral venous thrombosis presenting as acute reversible visual loss: a rarely reported association. *Annals of Neurosciences*. 2013 Jul;20(3):124.
5. Bousser MG, Ferro JM. Cerebral venous thrombosis: an update. *The Lancet Neurology*. 2007 Feb 1;6(2):162-70.
6. Luo Y, Tian X, Wang X. Diagnosis and treatment of cerebral venous thrombosis: a review. *Frontiers in aging neuroscience*. 2018 Jan 30;10:2.