

## Research Article

### Outcome of Haemorrhoidal Artery Ligation and Recto Anal Repair (HAL-RAR) with Doppler Guidance for Symptomatic Grade-II, III and IV Internal Haemorrhoids

Wasif Majeed Chaudhry,<sup>1</sup> Hania Aamir,<sup>2</sup> Amber Mohsin,<sup>3</sup> Salman Majeed Chaudhry,<sup>4</sup> Samar Ghufuran,<sup>5</sup> Maryam Jamil<sup>6</sup>

<sup>1,2,3,6</sup>Department of General Surgery, Lahore Medical and Dental College/ Ghurki Trust Teaching Hospital, Lahore; <sup>4</sup>Department of General Surgery, Rahbar Medical and Dental College, Lahore; <sup>5</sup>Department of General Surgery, Akhtar Saeed Medical and Dental College, Lahore

#### Abstract

**Background:** Internal haemorrhoids are very common all around the world and the classical surgical treatment is open haemorrhoidectomy for a long time. This procedure has a lot of complications and is very painful for the patient. Doppler guided HAL-RAR has shown satisfactory results in the literature with minimal pain and a significantly lower rate of complications compared to open haemorrhoidectomy.

**Objective:** To assess the outcome of a relatively new surgical procedure (HAL-RAR) using doppler guidance for the treatment of grade-II, III and IV internal haemorrhoids.

**Methods:** This case series was conducted at Surgimed hospital, Lahore, Pakistan, between May 2015 to December 2021. One hundred patients who attended the outpatient department of the hospital were recruited for this study. These patients presented with grade-II, III or IV symptomatic internal haemorrhoids. Surgical intervention in the form of HAL-RAR was performed in all patients and outcome was measured in terms of mean operating time, length of hospital stays, post-operative pain, recurrence of prolapse and bleeding, and early and late post-operative complications with one year follow up for all patients.

**Results:** Out of these 100 patients, 72 were males and 28 were females. On average, seven haemorrhoidal artery ligations and three recto anal repairs were performed in each patient. The average hospital stay was 31 hours with a range between 24 hours to 72 hours. Early post-operative pain was minimum and only twelve patients required narcotic analgesics. Three patients complained of excessive pain lasting for five days. Seven patients had self-limiting bleeding, two patients had post-operative bleeding which was controlled by re-ligation of the bleeding point and one patient developed a perianal fistula. In the long term follow up, one patient had recurrence of prolapse six months after the surgery.

**Conclusion:** HAL-RAR with doppler was a safe and efficient method for treatment of grade-II, III and IV internal haemorrhoids, with very low post-operative pain scores, satisfactory relief of symptoms, and low recurrence rates.

**Corresponding Author** | Dr. Wasif Majeed Chaudhry, Associate Professor, Department of General Surgery, Lahore Medical and Dental College/ Ghurki Trust Teaching Hospital, Lahore **Email:** drwasifchaudhry@gmail.com

**Keywords** | Haemorrhoids; Doppler-guided Haemorrhoidal Artery Ligation; Recto Anal Repair; Trans anal rectal mucopexy; Prolapse; Rectal bleeding.



#### Production and Hosting by KEMU

<https://doi.org/10.21649/akemu.v29i2.5445>  
2079-7192/© 2023 The Author(s). Published by Annals of KEMU on behalf of King Edward Medical University Lahore, Pakistan.  
This is an open access article under the CC BY4.0 license <http://creativecommons.org/licenses/by/4.0/>

#### Introduction

Haemorrhoids are one of the most common diseases of the anorectal region causing significant impact on daily life.<sup>1,2,16</sup> It is estimated that the rate of

disease is higher in the Subcontinent however no known figures exist in literature.<sup>11,16</sup>

Goligher's classification grades internal haemorrhoids according to their appearance and degree of prolapse.<sup>3</sup> Grade-I haemorrhoids bleed but do not prolapse outside the anal canal, grade-II haemorrhoids bleed and the anal cushions prolapse through the anus on straining but reduce spontaneously, grade-III haemorrhoids bleed with the anal cushions prolapsing through the anus on straining or exertion and require manual reduction into the anal canal, and grade-IV haemorrhoids are permanently prolapsed and are irreducible.<sup>3</sup> Thrombosed haemorrhoids with circumferential mucosal prolapse are also classified under grade-IV haemorrhoids.<sup>3</sup>

In 1995, Morinaga introduced a new concept that haemorrhoidal disease is caused by increased blood flow to the haemorrhoidal plexus and decreased venous return from the anal cushion.<sup>6</sup> This unidirectional flow was corrected by ligation of feeding vessels which are branches of the superior rectal artery resulting in Morinaga performing the first doppler-guided haemorrhoidal artery ligation.<sup>6</sup> Ten years later, Aigner F. et al. supported the Morinaga theory.<sup>7</sup> GE Theodoropoulos et al. in their clinical trial, gave a satisfying result of doppler-guided haemorrhoidal artery ligation for advanced grades of haemorrhoids.<sup>8</sup> This new modification with HAL-RAR addressed the two main pathophysiological mechanisms of haemorrhoidal disease development by ligating the feeding vessel to decrease the blood flow to recto-anal submucosa.<sup>8</sup> This was followed by sutures at haemorrhoidal sites that elevated the prolapsed tissue and supported the lax mucosa.<sup>8</sup>

Haemorrhoidal disease treatment varies according to its different grades. Non-operative approach is usually successful for grade-I and grade-II haemorrhoids but surgery is the treatment of choice for grade-III and grade-IV haemorrhoids.<sup>4</sup> Grade-II haemorrhoids that have failed to be medically treated can also be considered for the HAL-RAR procedure.<sup>4</sup> Even though Milligan Morgan (open haemorrhoidectomy) or Ferguson (closed haemorrhoidectomy) are the gold standard procedures for the treatment of advanced stage symptomatic haemorrhoidal disease, they are very painful for the patient because of the associated cutting of the haemorrhoidal tissue.<sup>10</sup>

Haemorrhage, scarring and anal stenosis are reported complications of open haemorrhoidectomy.<sup>9</sup> Stapled haemorrhoidectomy has higher rates of complications and reoperation rates reaching up to 10% make it an unfavourable procedure.<sup>9</sup> The stapled method can be considered a relatively obsolete approach, seldomly practiced in the West.<sup>9</sup> HAL-RAR procedure has shown better results as compared to open haemorrhoidectomy with decreased post-operative pain, excellent relief of symptoms, reduced hospital stay and low recurrence rates.<sup>5</sup>

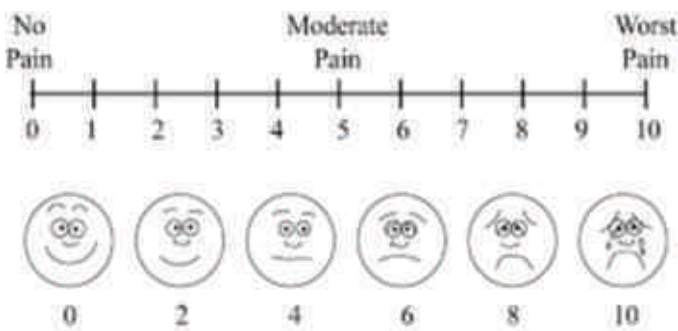
Therefore, this study was designed to assess the outcome of a relatively new surgical procedure in Pakistan for the treatment of grade II, III and IV internal haemorrhoids in terms of post-operative complications, post-operative pain, operative time, and hospital stay.

## Methodology

This case series was conducted at Surgimed hospital, Lahore, Pakistan between May 2015 till December 2021. Ethical approval for this research was taken from the institutions ethical review board. One hundred patients who attended the outpatient department of the hospital were recruited for this case series using non-probability convenience sampling. The first patient was enrolled on the 10<sup>th</sup> of May 2015 and the last patient was enrolled on 23<sup>rd</sup> of December 2020. The last follow-up visit of the last enrolled patient was completed on 25<sup>th</sup> of December 2021. All patients were admitted through the outdoor clinic and detailed information about the HAL-RAR procedure was given to them by the admitting consultant along with the associated benefits and risks of the procedure. Patients were also informed about the risks and complications associated with open haemorrhoidectomy and the cost difference between the two procedures and only those patients who voluntarily opted to undergo HAL-RAR procedure were recruited for this research. Patients with grade II, III, and IV internal haemorrhoids with bleeding, prolapse, and itching were included in the study. Patients who were considered unfit for general or spinal anaesthesia based on laboratory investigations, comorbidities and preoperative assessment by the anaesthesia team were excluded from the study. Informed consent was signed by the patients. Each patient underwent haemorrhoidal artery ligation and

recto anal repair under general or spinal anaesthesia. All surgeries were performed by one surgeon who was trained from a teaching hospital in Germany to do these procedures.

Data were collected during the study period by a specifically designed printed proforma. This questionnaire was filled by the operating consultant before the surgery and completed at one week, six weeks, six months and one year follow-up visits after the surgery. The proforma contained questions about the post-operative complications of the haemorrhoidal disease, including itching, bleeding, prolapse, pain, discomfort in daily life, and difficulty with defecation. Post-operative pain was calculated using Visual Analogue Score (VAS), Figure.1. The mean VAS, mean hospital stay and post-operative complications were taken as the outcome variables.

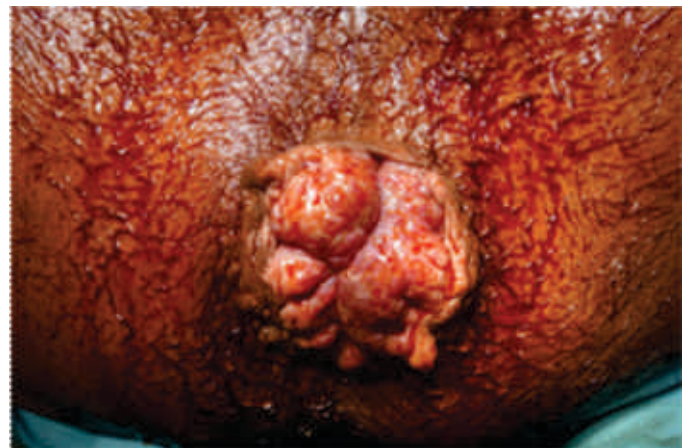

**Figure.1.** Visual Analogue Score (VAS)

All patients were given intravenous Amoxicillin with Clavulanic acid, 1.2 gram and intravenous Metronidazole, 500mg at induction of anaesthesia and continued postoperatively till the patient was discharged. All these surgeries were performed under general or spinal anaesthesia in the lithotomy position. Under aseptic measures, digital rectal examination and proctoscopy were performed in every patient and preoperative examination finding and any additional pathology were confirmed. After inserting the HAL-RAR doppler probe along with the anoscope into the anal canal for approximately 5 to 6 cm, the pulsations of the branches of the haemorrhoidal artery were detected by the doppler and multiple haemorrhoidal artery ligations were performed with Polyglactin (vicryl 2/0) 31mm round body needle figure of eight sutures. A rotation of such ligations was performed between 12 o clock to 12 o clock position. The doppler probe was subsequently pulled out for approximately 1.5 cm distally and a similar round of ligations were performed wherever the pulsations were detected. Recto

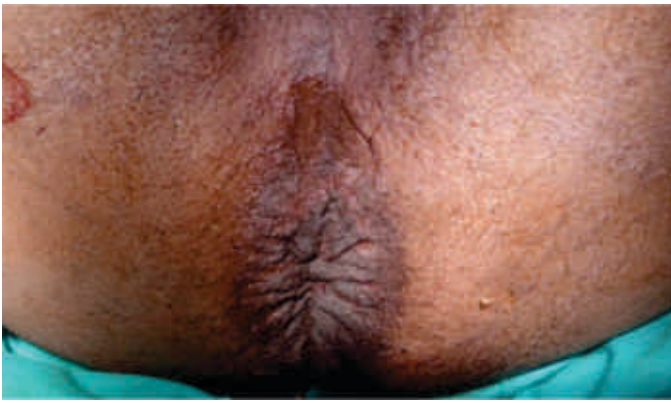anal repairs were performed in each patient at 3, 7 and 11, O clock positions with Vicryl 2/0 suture on a 31 mm round body needle. For recto anal repair the first stitch was taken at 5 cm from the anal verge and multiple interlocking continuous stiches were taken 1cm apart distally, the last stitch being just above the dentate line. The mucosal haemorrhoidal prolapse was lifted when the last stitch was ligated with the proximal end of the suture. Haemostasis was secured and anal canal was packed with a liquid paraffin-soaked roll gauze to apply pressure which was removed six hours after the procedure. All patients were discharged on oral Amoxicillin - Clavulanic acid and oral Metronidazole for three days. Figures. 2 and Figure. 3 shows the preoperative and postoperative photographs of a patient with grade IV internal haemorrhoids who underwent HAL-RAR. Postoperative follow ups were conducted at one week, six weeks, six months and one-year intervals. In all these follow-up visits, clinical examination was performed to assess all the complications of the procedure like anal fissure, perianal fistula and fecal incontinence. Questions were asked about the resolution of symptoms like bleeding, prolapse, time required to resume normal daily activities after surgery, and overall satisfaction of the patient with the procedure. All this information was documented on the proforma.

**Figure 2:** Grade IV Haemorrhoids before HAL and RAR



**Figure 3:** Grade-IV haemorrhoids after HAL and RAR

The collected data was entered in SPSS version 20.0 and analysed. Age is presented as a range and gender



as frequency and percentages. Numerical variables i.e., operating time, postoperative pain and length of hospital stay are presented by mean  $\pm$  standard deviation (Table. 1). Outcome variables are presented with percentages in Table. 2 and explained in detail in the results section.

## Results

Out of these 100 patients, 72 (72%) were males and 28 (28%) were females. The mean age of the patients was 45 years with a range between 27 to 75 years. 97% of the patients presented with rectal bleeding and 76% patients presented with bleeding and prolapse of varying degrees. The mean operating time for the procedure was  $45 \pm 16.84$  minutes with a range between 25 to 65 minutes (Table.1). The average number of arteries ligated were seven. Recto-anal repairs were conducted at the 3,7 and 11 o'clock positions. 27 grade-II, 69 grade-III and 4 grade-IV prolapses were treated by HAL-RAR method.

The sample had five patients suffering from chronic liver disease due to the hepatitis C virus. These patients had excellent results with the HAL-RAR procedure as no excessive blood loss occurred despite of deranged bleeding and clotting profile. Three patients with pre-existing ischemic heart disease were taking aspirin and warfarin for many years and could not withhold them for the procedure were also part of the sample. Four patients presented with diabetes, with three on long-term insulin therapy. No patient with these co-morbidities suffered significant post-operative bleeding or complications, demonstrating that this procedure was suitable for immunocompromised patients as well.

Five patients had acute anal fissures pre-operatively associated with internal haemorrhoids and lateral anal internal sphincterotomy was also added along with

HAL-RAR. Post-operative pain assessment was conducted using an internationally recognised pain scoring method known as VAS. 12% of patients had no post-operative pain. 78% of the patients had minimum pain with a VAS of less than 4 in which one dose of intramuscular nonsteroidal anti-inflammatory drug (NSAID) was given post operatively. 45% of patients experienced a VAS of 2 and 22% had a VAS between 3 and 5, which was relieved by one dose of analgesic use. Five patients had moderate pain lasting for 5 days VAS (6-7). None of these five patients had any associated comorbidities. The average hospital stay was thirty-one hours, ranging from 24 hours to 72 hours. Seven patients had mild self-limiting bleeding within one week of the procedure. 99% of the patients were satisfied with the treatment method at one year after the procedure with resolution of all the symptoms. None of the patients developed surgical site infection, anal stenosis, and faecal incontinence due to anal sphincter damage post operatively. This was assessed by a series of clinical examinations and follow-up questions addressing faecal evacuation, flatus control and easy passage of stool. Anal tone was also checked by digital rectal examination.

Two patients developed posterior anal fissures which resolved with topical Glyceryl trinitrate and Lidocaine. Moreover, one patient developed a perianal fistula for which fistulectomy was done. Seven patients had mild

**Table 1:** Mean Operating Time, Duration of Hospital Stay and Postoperative Pain Score

Sr #	Outcome Variable	Minimum value	Maximum Value	Mean $\pm$ Standard deviation
1)	Operating time (minutes)	25	65	$45 \pm 16.84$
2)	Duration of hospital stays (hours)	24	72	$31 \pm 7.99$
3)	Postoperative pain score at 24 hours after surgery (VAS)	0	9	$3.43 \pm 2.75$

self-limiting bleeding for three days. Two patients had significant post-operative bleeding which was controlled by re-ligation of the bleeding points. One patient had recurrence of prolapse recorded during the six-month follow-up period and he underwent open haemorrhoidectomy for this prolapse (Table.2).

**Table 2:** Outcome of HAL-RAR with Doppler

Sr#	Outcome Variable	Percentage
1).	Surgical site infection	0%
2).	Anal stenosis	0%
3).	Faecal incontinence due to anal sphincter damage	0%
4)	Perianal fistula	1%
5).	Recurrence of prolapse	1%
6).	Recurrence of bleeding	2 %
7).	Post-operative anal fissure	2%

## Discussion

Advanced procedures are currently in exploration for haemorrhoidal disease. Conventional open haemorrhoidectomy results in increased post-operative pain with subsequent increase of analgesic abuse and often progression to prolonged opioid use.<sup>4</sup> HAL-RAR contradicts traditional open haemorrhoidectomy in reducing pain medication administration and analgesic monitoring as seen in this study and similar researches.<sup>18</sup> The objective of this observational study was to assess a novel technique recently introduced in Pakistan that encompasses decreased post-operative pain, post-operative complications and hospital stay.<sup>18</sup> The efficacy and safety of HAL-RAR for managing grade-II, III and IV internal haemorrhoids is widely recognised.<sup>12</sup> This treatment method is relatively painless with a minimal rate of complications.<sup>12</sup>

The HAL-RAR approach depicts decreased complications as compared to stapled haemorrhoidectomy. Stapled haemorrhoidectomy results in serious long-term consequences such as chronic anal pain and sepsis.<sup>9</sup> In HAL-RAR, no post-operative septicaemia or sustained pain persisted. Therefore, it can be acknowledged that HAL-RAR has better results than the stapled haemorrhoidectomy, thus resulting in earlier functional recovery of the patient.<sup>11</sup> Similar results can be seen in the Faucheron study, in which decreased hospital stay can be seen.<sup>11</sup>

Doppler-guided HAL-RAR is a safe treatment for grade III and IV haemorrhoids.<sup>17</sup> Its minimally invasive technique involves combining Haemorrhoidal Artery Ligation with Recto-Anal Repair.<sup>16</sup> This serves to lift and then secure the protruding haemorrhoids in place.<sup>10</sup> The HAL-RAR strategy achieves symptomatic resolution earlier in terms of bleeding, with seven patients in this study experiencing self-limited bleeding within one week and the rest recovering within two weeks. A research

conducted in Sao Paulo mirrored the same result, achieving symptomatic relief quicker using doppler guidance.<sup>16</sup>

In this study, one patient who experienced severe pain on defecation had symptom relief at the six week follow-up after an increase NSAID use and reassurance by the primary surgeon. One patient developed a perianal fistula which was detected at the six week follow up and this is a known complication of the doppler guidance technique which can be witnessed in many studies, conducted in Brazil, India, and France respectively.<sup>16,17,18</sup> The primary surgeon conducted a fistulectomy after two months of the initial procedure. Another complication that occurred was the formation of anal fissures in 2% of the sample size which were relieved by prescribing Glyceryl trini-trate and Lidocaine ointment application inside the anal canal for three weeks and daily sitz bath. This treatment resulted in complete resolution of the fissures. This complication has also been reported in literature with doppler guidance. One patient complained of excessive pain at three weeks not controlled by a minimum dose of NSAID. Reassurance was given and with an increase dose of NSAID, pain on defecation was relieved within one week. As compared with recent research, HAL-RAR using doppler guidance results in complications which can be managed effectively by the surgical team.<sup>11,17,18</sup>

Defining re-occurrence varies throughout research evaluating haemorrhoidal treatment outcome. In this study, reoccurrence is portrayed as prolapse even without bleeding in contrast to research conducted by Faucheron et al. who categorised reoccurrence as prolapse with bleeding.<sup>11</sup> Furthermore, another study interpreted reoccurrence as symptoms requiring surgery.<sup>14</sup> This is an advantage point as there is a wider portrayal of post-operative complications in this study as compared to previous reported research.<sup>11,14</sup>

A limitation to doppler guidance was cost. The medical equipment needed was expensive, resulting in a costly procedure which must be borne by the patients. In a developing country such as Pakistan, this is a factor that needs to be considered. To change the hemorrhoidal operative curve in favour of HAL-RAR, the technology needs to be widely available.<sup>13</sup> The lack of operative equipment cannot match the rate of haemorrhoidal disease that exists in the subcontinent.<sup>11,15</sup> Follow up time

can be considered another limitation. In this study, only one patient had recurrence of prolapse in one year. However, an observation time of five years is needed to effectively assess HAL-RAR outcome to compare with the gold standard open haemorrhoidectomy, which was achieved in a particular study by Faucheron which evaluated long term results.<sup>11</sup> This study has achieved five year follow ups for procedures conducted in 2015 and early 2017. More than two years of assessment is still required to reach an adequate comparison with conventional haemorrhoidectomy.

### Conclusion

This study explored a relatively new surgical procedure (HAL-RAR) in Pakistan as a potential alternate to open haemorrhoidectomy. The results showed less post-operative pain, minimal complications, and a decrease in the duration of hospital stay. Despite being slightly expensive as compared to open haemorrhoidectomy, this procedure remains economical in the long-term as there is less follow-up requirement due to a decrease in complication rate and decrease in hospital expenditure with less hospital stay time.

**Ethical Approval:** Given

**Conflict of Interest:** The authors declare no conflict of interest.

**Funding Source:** None

### References

1. Sun Z, Migaly J. Review of hemorrhoid disease: presentation and management. *Clinics in colon and rectal surgery*. 2016 Mar;29(01):022-9.
2. Riss S, Weiser FA, Schwameis K, Riss T, Mittlböck M, Steiner G, et al. The prevalence of hemorrhoids in adults. *International journal of colorectal disease*. 2012 Feb; 27(2):215-20.
3. Pata F, Sgrò A, Ferrara F, Vigorita V, Gallo G, Pellino G. Anatomy, physiology and pathophysiology of hemorrhoids. *Reviews on recent clinical trials*. 2021 Feb 1; 16(1):75-80.
4. Roka S, Gold D, Walega P, Lancee S, Zagriadsky E, Testa A, et al. DG-RAR for the treatment of symptomatic grade III and grade IV hemorrhoids: a 12-month multicentre, prospective observational study. *European Surgery*. 2013 Feb;45(1):26-30.
5. Fischer JE, Jones DB, Pomposelli FB, Upchurch GR, Klimberg VS, Schwaitzberg SD, et al. Fischer's mastery of surgery, 6E [Internet]. Lippincott Williams & Wilkins; 2018 [cited 2023 Jul 22]. Available from: <https://surgery.lwwhealthlibrary.com/book.aspx?bookid=922>
6. Morinaga K, Hasuda K, Ikeda T. A novel therapy for internal hemorrhoids: ligation of the hemorrhoidal artery with a newly devised instrument (Moricorn) in conjunction with a Doppler flowmeter. *American Journal of Gastroenterology (Springer Nature)*. 1995 Apr 1; 90(4). Thomson WH. The nature of haemorrhoids. *British Journal of Surgery*. 1975 Jul;62(7):542-52.
7. Theodoropoulos GE, Sevrisianos N, Papaconstantinou J, Panoussopoulos SG, Dardamanis D, Stamopoulos P, et al. Doppler-guided hemorrhoidal artery ligation, rectoanal repair, sutured haemorrhoidopexy and minimal mucocutaneous excision for grades III–IV haemorrhoids: a multicenter prospective study of safety and efficacy. *Colorectal disease*. 2010 Feb; 12(2): 125-34.
8. Balciscueta Z, Balciscueta I, Uribe N. Post-hemorrhoidectomy pain: can surgeons reduce it? A systematic review and network meta-analysis of randomized trials. *International Journal of Colorectal Disease*. 2021 Dec; 36(12):2553-66.
9. Oughriss M, Yver R, Faucheron JL. Complications of stapled hemorrhoidectomy: a French multicentric study. *Gastroentérologie clinique et biologique*. 2005 Apr 1; 29(4):429-33.
10. Faucheron JL, Poncet G, Voirin D, Badic B, Gangner Y. Doppler-guided hemorrhoidal artery ligation and rectoanal repair (HAL-RAR) for the treatment of grade IV hemorrhoids: long-term results in 100 consecutive patients. *Diseases of the Colon & Rectum*. 2011 Feb 1; 54(2):226-31.
11. Giordano P, Overton J, Madeddu F, Zaman S, Gravante G. Transanal hemorrhoidal dearterialization: a systematic review. *Diseases of the colon & rectum*. 2009 Sep 1;52(9):1665-71.
12. Scheyer M, Antonietti E, Rollinger G, Mall H, Arnold S. Doppler-guided hemorrhoidal artery ligation. *The American journal of surgery*. 2006 Jan 1;191(1):89-93.
13. Ratto C, Donisi L, Parello A, Litta F, Doglietto GB. Evaluation of transanal hemorrhoidal dearterialization as a minimally invasive therapeutic approach to hemorrhoids. *Diseases of the colon & rectum*. 2010 May 1; 53(5):803-11.
14. Ho YH, Seow-Choen F, Low JY, Tan M, Leong AP. Randomized controlled trial of trimebutine (anal sphincter relaxant) for pain after haemorrhoidectomy. *British Journal of surgery*. 1997 Mar;84(3):377-9.
15. Figueiredo MN, Campos FG. Doppler-guided hemorr-

- hoidal dearterialization/transanal hemorrhoidal dearterialization: technical evolution and outcomes after 20 years. *World journal of gastrointestinal surgery*. 2016 Mar 27;8(3):232-7.
16. Gupta PJ, Kalaskar S, Taori S, Heda PS. Doppler-guided hemorrhoidal artery ligation does not offer any advantage over suture ligation of grade 3 symptomatic hemorrhoids. *Techniques in Coloproctology*. 2011 Dec; 15(4): 439-44.
  17. Ferrandis C, De Faucal D, Fabreguette JM, Borie F. Efficacy of Doppler-guided hemorrhoidal artery ligation with mucopexy, in the short and long terms for patients with hemorrhoidal disease. *Techniques in coloproctology*. 2020 Feb;24(2):165-71.