

Case Report

Mutiple Hybrid Odontomas Involving All Four Quadrants of Jaws: A Rare Case Report

Sana Arif,¹ Nabeela Riaz,² Ehsah-ul-Haq,³ Hafiz Nasir⁴

¹⁻⁴Department of Oral & Maxillofacial Surgery, KEMU/ Mayo Hospital, Lahore, Pakistan

Abstract

Odontomas are odontogenic tumors in which complete functional discrepancy of ameloblasts or odontoblasts occur with the development of enamel and dentine in an irregular arrangement due to lack of association of these cells to reach usual state of morphodifferentiation. Multiple hybrid odontomas present as many complex or compound odontomas involving one to all four quadrants of jaws. This present case is of a female aged 12 years who presented with mild pain and swelling in the right body of mandible for 1 year. After initial clinical and radiographic assessment, a tentative diagnosis of multiple hybrid odontomas involving all four quadrants of jaws was made. Surgical excision of the lesion which was causing facial deformity was performed. Excisional biopsy report verified the clinical diagnosis. This case report describes the first unique case of multiple hybrid odontomas involving all four quadrants of jaws presented in last five years' literature.

Corresponding Author | Dr. Sana Arif, Department of Oral & Maxillofacial Surgery, KEMU/ Mayo Hospital, Lahore
Email: roshaaney@gmail.com

Keywords | multiple odontomas, hybrid odontomas, hamartoma, developmental malformations

Introduction

Odontomas are classified as developmental malformations (hamartomas), instead of true neoplasm, with stem cells originated from both epithelium and mesenchyme consisting of enamel, dentine, pulp, and cementum.¹ Odontoma is the most common odontogenic tumor with 75% prevalence followed by ameloblastoma and odontogenic myxoma.² Most odontomas present as single lesion in the jaw whereas multiple odontomas (MOs) consist of many odontomas present in one to all four quadrants of the jaws, a case series mentioned 15 cases of MOs, of which 9 were complex.³ They were further classified

into two types; complex or compound odontomas. They are usually asymptomatic or found incidentally in a routine radiograph or manifest as gradual swelling of the involved jaw bone, however unusually swelling and pain may occur in association with other odontogenic tumors, most notably calcifying odontogenic cyst and dentigerous cysts.¹ Multiple odontoma is a rare pathology, very less information is available regarding its clinical features.³ This is a unique case report that manifests multiple hybrid odontomas in a 12 years old female involving all four quadrants of jaws.

Case Report

A 12 years old female presented in outdoor patient department of Oral and Maxillofacial Surgery in Mayo Hospital Lahore with the chief complaint of mild pain and swelling at right side of lower jaw for 1 year which progressively increased in size. Past medical, surgical, personal & family history was insignificant. Systemic



Production and Hosting by KEMU

DOI: <https://doi.org/10.21649/akemu.v29i2.5483>
2079-7192/© 2023 The Author(s). Published by Annals of KEMU on behalf of King Edward Medical University Lahore, Pakistan.
This is an open access article under the CC BY4.0 license <http://creativecommons.org/licenses/by/4.0/>

examination was unremarkable. On local examination extra-orally there was facial asymmetry because of 3cm × 3cm (AP & TT) diffuse, bony hard, non-tender swelling on right body of mandible 1cm behind right commissure of mouth to 3cm in front of angle of mandible anteroposteriorly and inferiorly reaching up to the lower border of mandible. Overlying skin was intact, free from underlying structures, normal in color, temperature and texture. Intra-orally 5cm×4cm (AP& TT) swelling extending from distal of canine to retromolar region anteroposteriorly with expansion of both buccal and lingual cortex and obliterating the buccal vestibule. Overlying mucosa was intact, slight erythematous in color and of normal texture. Maxillary and mandibular anterior teeth were present along with right upper premolars and left lower second primary molar. There was microdontia and spacing in all teeth with yellowish brown discoloration.

Orthopantomogram (OPG) of patient showed six well demarcated radiopacities with radiolucent borders in mandible and four in maxilla. Irregular and calcified mass with no identifiable tooth like structures favors the diagnoses of complex odontoma in mandible while in maxilla miniature tooth like structures were identified favoring compound odontoma. (Figure 1)

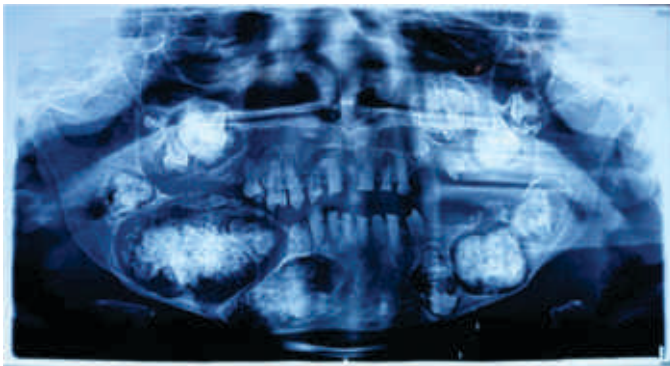


Figure 1: OPG of patient showing multiple compound and complex odontomas.

Diagnoses were made on the basis of clinical and radiographic assessment and excision of odontoma of right mandibular body region causing facial asymmetry was planned under GA keeping in mind patient's chief complaint.

After getting informed consent from the patient, all required baseline investigations were done. And surgery was planned under general anesthesia. Right lower vestibular incision given (figure 2), lesion exposed and excised en-block with hammer and chisel.

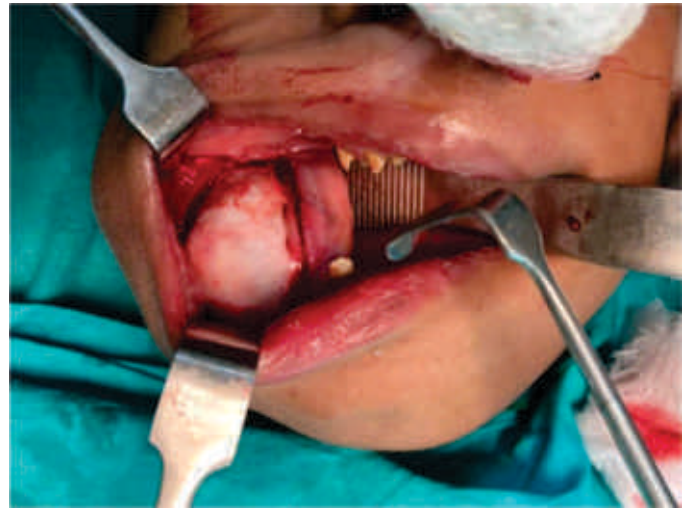

Figure 2: Exposed lesion on right lower buccal vestibule. Mental nerve identified and saved. Hemostasis achieved. Bismuth Iodoform Paraffin Paste (BIPP) pack placed and primary closure done with 3-0 vicryl. Recovery from anesthesia was uneventful. Sample (figure 3) submitted for excisional biopsy and patient was discharged very next day on oral medications as Tab. Co-amoxiclave, Tab. Metronidazole and Tab. Ibuprofen for 3 days. BIPP pack changed after 2 weeks and patient was put on strict follow-up because of remaining odontomas of jaws which are currently not causing any problem. (figure 4 & 5 showing OPG of patient after 6 months and 1 year follow-up respectively, where marked bone regeneration at excision site can be seen and halted growth of all remaining odontomas currently not causing any problem.)

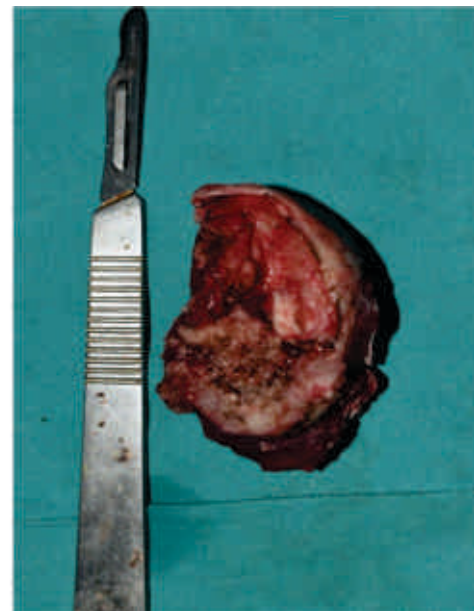


Figure 3: Excised Lesion.

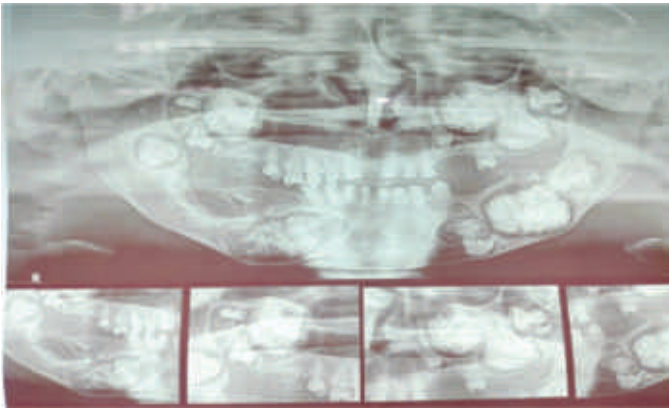


Figure 4: OPG after 6 months follow-up.

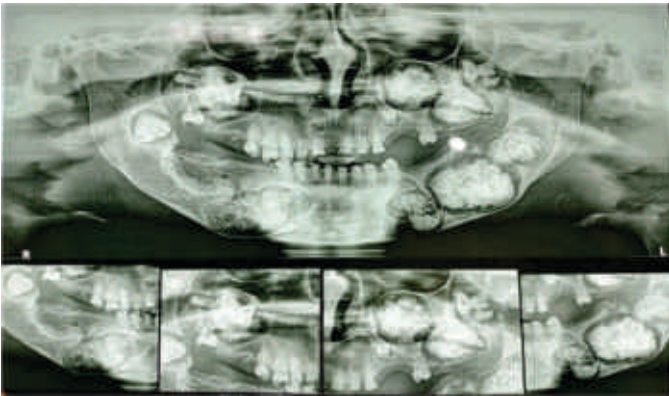


Figure 5: OPG after 1 year follow-up.

Discussion

Paul Broca is pioneer to use the name ‘Odontoma’ a generally asymptomatic, slowly growing hamartomatous lesion composed of both hard and soft tissues of odontogenic origin which constitutes 22%–67% of all odontogenic tumors.⁵ Compound odontomas are common in anterior maxilla while complex odontomas in posterior mandible,¹ with incidence rate of 2:1.2 Less than 5% hybrid lesions also reported,⁶ resembling with this case (compound odontomas in maxilla while complex in mandible). Odontomas clinically present during the first and second decade of life, mean age is 14 years with male to female ratio as 1:1,⁷ close to this patient’s age which is 12 years old. Regardless of the high prevalence of odontomas, multiple odontomas are extremely rare in humans with an unknown prevalence.³ This case of multiple hybrid odontoma involving all four quadrants is first to be reported in last five years. Odontomas are slow growing and of small size but if become enlarged they can cause cortical bone expansion,³ as in this case one odontoma at right body of mandible was causing

buccal and lingual cortex expansion with slight facial asymmetry. Several dental abnormalities can guide to the existence of an odontoma; persisting deciduous tooth, delayed tooth eruption and missing or impacted permanent tooth,² similar features were found in this case. The etiology of odontoma is unknown, but some reported etiologies are trauma, infection, inheritance and some syndromes like basal cell nevus syndrome, Gardner syndrome, familial colonic adenomatosis, Tangier disease, Hermann syndrome, or odontomaldysphagia syndrome,⁵ no features of these syndromes were found in this case. The surgical treatment consists of complete excision of the lesion and curettage of the surrounding area, recurrence is uncommon.⁸ Same management was done for this patient.

Conclusion

Odontomas make up the large percentage of odontogenic tumors. They can restrict eruption of permanent teeth and can alter the arch-forms resulting in malocclusion, so in time excision should be done. While multiple odontomas involving all four quadrants in a young patient is extremely rare entity requiring comprehensive and strategic treatment planning along with long follow up.

Conflict of Interest: The authors declare no conflict of interest.

Funding Source: None

References

- 1- Aschaitrakool Y, Panyawaraphon T, Chinkrua C, Chamusti N, Wimardhani YS. Management of Large Odontoma in Mandible: A Rare Case Report. *CM Dent J.* 2021; 42(2):120-7
- 2- Minya F, Trimmel B, Simonffy L, Dobo-Nagy C, Gyulai-Gaal S. Odontoma Removal and Oral Rehabilitation via Insertions of Albumin and Gentamycin Coated Bone Allograft and Dental Implants-A Case Report. *Biomedical Journal of Scientific & Technical Research.* 2021;33(4):26116-20.
3. Botelho J, Machado V, Gomes JC, Borrecho G, Maia P, Mendes JJ, et al. Multiple complex odontomas of the mandible: a rare case report and literature review. *Contemporary Clinical Dentistry.* 2019;10(1):161.
- 4- Singla M, Verma KG, Goyal T, Kakkar A, Ahuja L.

- Compound odontoma in primary dentition- A case report. *J Oral Med Oral Surg Oral Pathol Oral Radiol*, 2017; 3(1): 62-4.
- 5- Zhuoying C, Fengguo Y. Huge erupted complex odontoma in maxilla. *Oral and Maxillofacial Surgery Cases*. 2019;5(1):100096.
- 6- Brooks JK, Tran LT, Basile JR, Khoury ZH, Wu LL, Price JB. Synchronous gubernacular canals with compound odontoma associated with a calcifying odontogenic cyst and transmigrated canine: An extremely rare event. *Pediatric Dental Journal*. 2020;30(1):39-44.
- 7- Prabhu N, Issrani R, Patil S, Srinivasan A & Alam MK. Odontoma- An Unfolding Enigma. *J Intl Oral Health* 2019;11(1):334-9.
- 8- Bhalerao S, Lone V, Bhoware R, Mohod S. Giant complex odontomas erupting in the Oral Cavity. *Intl J Maxillofac Imaging*. 2017;3(3):100-3.