

Case Report

A Unique Case of Adrenal Insufficiency Coexisting with Two Primary Malignancies

Hilal Bektas Uysal,¹ Murat Duran,² Engin Güney,³ Irfan Yavasoglu,⁴ Hulki Meltem, Sonmez⁵

^{1,2,5}Department of Internal Medicine, Aydin Adnan Menderes University Faculty of Medicine, 09100, Aydin, Turkey;

³Department of Endocrinology and Metabolism, Aydin Adnan Menderes University School of Medicine, 09100, Aydin, Turkey; ⁴Department of Hematology, Aydin Adnan Menderes University School of Medicine, 09100, Aydin, Turkey,

Introduction

Endocrine system originated lymphoma accounts 3% of all extra-nodal lymphoma cases and primary adrenal lymphoma (PAL) constitutes only 0.2% of them.¹ In our literature research, there are nearly 250 cases published about PAL, until today. To the best of our knowledge, in addition to this extremely rare incidence of PAL, another accompanying primary malignancy has not been reported in the literature to date. Here, we present the first case of adrenal insufficiency, coexisting with bilateral PAL and follicular thyroid carcinoma.

Key Words: Adrenal, Coexisting, Malignancies

Case Report

A 78-year-old woman with a known history of asthma, was admitted to our clinic with loss of appetite, fatigue and weight loss. She had a 2 two-month history of fatigue with further deterioration. She lost nearly 10 kg (>10% of her body weight) in last month and had no additional neurological, gastrointestinal, respiratory or cardiovascular symptoms. In her physical examination, blood pressure was 90/60mmHg, pulse rate 85/min and body temperature 36.8°C. She had pale conjunctiva and hyperpigmentation on her neck. There was no palpable lymphadenopathy or organomegaly. In her laboratory examinations (Table 1), complete blood cell count

revealed a normochromic normocytic anemia supported by peripheral blood smear examination with no atypical cells. Besides normal kidney function tests she had hyponatremia with normal potassium levels. ACTH (250 µg iv) stimulation test was performed because her morning cortisol was 10.6 µg/dL. Test showed no response in plasma cortisol levels revealing adrenal failure (Table 1). Her ACTH levels found high with 77.4 pg/ml, indicating primary adrenal insufficiency (AI). Additionally, plasma aldosterone levels were decreased with normal renin levels, supporting the primary AI diagnosis. Replacement therapy was initiated with 30 mg/day of hydrocortisone. To investigate the etiology of AI some advanced examinations were performed. Tuberculin skin test was negative. Serology for HIV, hepatitis B and C were all negative. In accordance with decreased albumin/globulin ratio, serum protein electrophoresis and urine immunoelectrophoresis were performed which were all in normal ranges.

Her abdominal CT showed bilateral adrenal masses with a diameter of 62×26 mm in left and 72×21 mm in right adrenal (Figure 1A). Almost no washout (<50%) detected in these adrenal masses. In adrenal MRI, masses revealed moderate hyperintensity on T2 imaging and hypo-intensity on T1 imaging, strongly indicating malignancy (Figure 1B). With suspicion of malignancy, she underwent positron emission tomography with 18F-fluorodeoxyglucose (PET-CT), which showed intensely hypermetabolic involvement in both enlarged adrenal glands with a 48.6 standardized maximum uptake value (SUVmax) (Figure 1C). There was an additional involvement in a 1.6 cm diameter thyroid nodule on the left side



Production and Hosting by KEMU

DOI: <https://doi.org/10.21649/akemu.v29i2.5487>
2079-7192/© 2023 The Author(s). Published by Annals of KEMU on behalf of King Edward Medical University Lahore, Pakistan.
This is an open access article under the CC BY4.0 license <http://creativecommons.org/licenses/by/4.0/>

with 14.6 SUVmaxvalue (Figure 1D). Thyroid fine needle aspiration biopsy was performed. Biopsy showed Hurthle cell type follicular thyroid carcinoma. The endocrinology-surgery council decision was to perform adrenal gland biopsy to exclude metastases, lymphoma, adrenocortical adenoma/carcinoma or functioning/non-functioning adenoma for the determination of the treatment protocol. Before biopsy, pheochromocytoma was excluded with normal urine metanephrines (Table 1). Ultrasound guided right adrenal gland needle biopsy was performed and no complication reported. Biopsy result revealed, diffuse large B-cell lymphoma (DLBCL) with diffuse staining of CD20 and Bcl-2 70%, Bcl-6 60%, c-myc 50% positive (Figure 2). Hematology consultants decided to give chemotherapy for PAL before thyroid surgery. Just before the scheduled first cycle of chemotherapy, the patient developed septicemia and died shortly thereafter.

Discussion

PAL is a very rare condition that usually presents in elderly men with mean age 68 years. It is bilateral in nearly 70% of all cases. DLBCL is the most common subtype which accounts 78% of all. PAL has an aggressive behavior which has 68% B-symptoms, 61% AI and fatigue 48% in patients.^{1,3} Contrary to the literature our patient was female but had all leading symptoms and findings as consistent with the literature.

Metastatic solid tumors especially originating from breast, lung and kidney, lymphoma, pheochromocytoma, adrenocortical adenoma/carcinoma and hemorrhage should be evaluated in the adrenal gland mass differential diagnosis.⁴ Besides an exhaustive history and physical examination, biochemical and radiological examinations are also needed to reveal the etiology. In CT, lesions which demonstrate moderate enhancement of contrast and above 4 cm diameter, highly indicate malignancy. On MRI, PAL lesions often show hypointense in T1 and hyperintense enhancement in T2 sequences.^{1,5} PET-CT may give information about the functional status of the mass as well as anatomical information and reveal the extra-adrenal extensions.⁵ But for a definitive diagnosis, ultrasound/CT guided needle biopsy is the key tool. In our case, CT and MRI findings were consistent with literature and PET-CT revealed an additional involvement in thyroid besides adrenal glands.

Despite the good survival rates of follicular thyroid carcinoma, prognosis of PAL is poor. Survival time of PAL has a broad spectrum between 4 and 15 months.^{6,7} Large mass size, high LDH levels, older age, bilateral

Table 1: Laboratory Data

Analyte	Result	Reference interval
Haemoglobin (g/L)	9.6	11.2 – 15.7
White cells (*10 ⁹ /L)	7.94	3.98 – 10.04
Platelets (*10 ⁹)	468	180 - 370
Sodium (mmol/L)	120	136 - 145
Potassium (mmol/L)	4.9	3.5 – 5.1
Bicarbonate (mmol/L)	25.1	22 - 32
Urea (mmol/L)	29	13 - 43
Creatinine (umol/L)	0.66	57 - 111
eGFR (mL/min/1.73 m ²)	84.61	90 - 120
LDH (U/L)	651	125-243
CRP (mg/L)	1510	0-5
ESR (mm/hour)	35	0-20
Cortisol, early morning (µg/dL)	10.6	2.9 – 19.40
ACTH (Synacthen) stimulation test (µg/dL), serum cortisol results	9,0 (preinjection) 10,3 (30 min) 9,3 (60min) 8,9 (90min) 9,0 (120min)	
ACTH (pg/ml)	77.4	0-46
Aldosterone (pg/ml)	57.76	70-300
Renin (µIU/ml)	16.65	3.11-41.2
Normetanephrine (urine) (µg/day)	148.5	138-521
Metanephrine (urine) (µg/day)	1.45	30-180
Alanine Aminotransferaz (IU/L)	49	0-55
Aspartat Aminotransferaz (IU/L)	49	5- 34,00
MCV (fL)	77	79.4 – 94.8
LH (UI/L)	11.60	2.39 – 6.60
FSH (mIU/ml)	38.93	3.35 – 21.63
Estradiol (pg/mL)	<10	21- 251
Prolaktin (ng/mL)	14.41	1.20 – 29.93
17-OH Progesterone (ng/ml)	0.45	0.13-1.38
TSH (mIU/L)	0.6858	0.35 – 4.94

involvement and AI presence is considered as negative prognostic factors.⁴ Adrenalectomy may be better choice in most cases unless the presence of extra-adrenal malignancy or the suspicion of lymphoma.³

In conclusion, adrenal masses should be evaluated carefully with multidisciplinary approach. Although rare, PAL should be considered in the differential diagnosis

of adrenal masses. PET-CT may help both in the diagnosis of PAL and revealing additional malignancies.

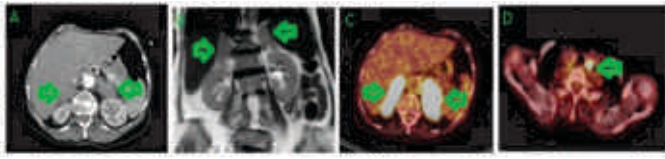


Figure 1: Radiological Images

(A) Contrast-enhanced computed tomography (CT) of the adrenals showing bilateral masses (arrows) (B) Abdominal MRI coronal plane showing bilateral adrenal masses (arrows) (C) ^{18}F -fluorodeoxyglucose positron emission tomography showing the intensely hypermetabolic involvement in both enlarged adrenal glands (arrows). (D) ^{18}F -fluorodeoxyglucose positron emission tomography showing the involvement in left thyroid nodule (arrow).

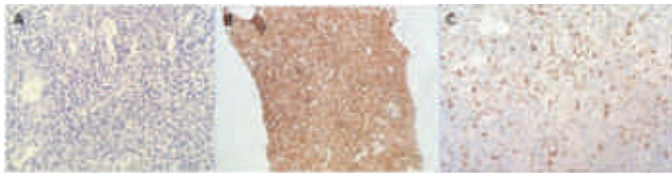

Figure 2: Histological Findings of Adrenal Biopsy

(A) H&E stain cellular detail (H&E x 400)—large cells with irregular nuclear contour and diffuse tumoral infiltration (B) CD20 immunostaining (x400) showing large CD20+ B lymphocytes (C) c-myc immunostaining (x400)

Reference

1. Rashidi A, Fisher SI. Primary Adrenal Lymphoma: A Systematic Review. *Ann Hematol.* 2013; 92(1): 1583–93.
2. Horiguchi K, Hashimoto K, Hashizume M. Primary bilateral adrenal diffuse large B-cell lymphoma demonstrating adrenal failure. *Intern Med.* 2010; 49(1): 2241–6.
3. Grønning K, Sharma A, Mastroianni MA, Karlsson BD, Husebye ES, Løvås K, et al. Primary adrenal lymphoma as a cause of adrenal insufficiency, a report of two cases. *Endocrinol Diabetes Metab Case Rep.* 2020; 10(1):19-0131
4. de Sousa Lages A, Bastos M, Oliveira P, Carrilho F. Diffuse large B-cell lymphoma of the adrenal gland: a rare cause of primary adrenal insufficiency. *BMJ Case Rep* 2016,18(1): bcr2016214920.
5. Dunnick NR, Korobkin M. Imaging of adrenal incidentalomas: current status. *AJR Am J Roentgenol.* 2002; 179(1):559–68.
6. Zeng J, Yan F, Chen Y, Zang L, Chen K, Lyu Z, et al. Primary Adrenal Lymphoma: Two Case Series from China. *Front Endocrinol (Lausanne).* 2022; 28(1):12-778984.
7. Singh D, Kumar L, Sharma A, Vijayaraghavan M, Thulkar S, Tandon N. Adrenal Involvement in non-Hodgkin's Lymphoma: Four Cases and Review of Literature. *Leuk Lymphoma.* 2004; 45(4):789–94.