

Isolated Sphenoidal Fungal Sinusitis, Presentation But Potentially Life Eatening Outcome

LATIF S., ASLAM N., AHMED R. AND SARFRAZ S.*

Department of ENT, Head and Neck Surgery, Sheikh Zayed Hospital, Lahore

For correspondence: Dr. Sarfraz Latif, Senior Registrar, Department of ENT Sheikh Zayed Hospital Lahore, *E-mail:* drsarfrazlatif@hotmail.com

Objective: The objective of this study is that one should keep high index of suspicion for isolated fungal sinusitis in patients of unexplained headache and visual disturbances. Computed Tomography and Magnetic Resonance Imaging are the best diagnostic tools.

Study design: Retrospective, descriptive study.

Place and duration of study: Department of ENT and Head and neck surgery sheikh Zayed hospital Lahore from March 2001 to April 2005.

Patients and methods: In this study twelve patients with a complaint of headache and visual disturbance were investigated thoroughly and among all there were isolated sphenoidal fungal sinusitis which were explored endoscopically and proven on culture and histopathologically, in all patients oral itraconazole was given for six months.

Results: In all patients headache improved 100% while visual changes like diplopia, improved in 5 patients 71%, cranial nerve palsies improved in 2 patients 40%.

Conclusion: It is concluded that isolated sphenoidal sinus pathology should be excluded in patients having un-explained headache and visual disturbance. Computed Tomography / Magnetic Resonance Imaging are the investigations of choice for final diagnosis.

Key words: Fungal sinusitis, sphenoid sinus.

Introduction

Fungal infection of nose and sinuses appears to be increasing rapidly but isolated sphenoid fungal sinusitis is a rare condition seen in ENT practice. This condition is usually difficult to diagnose as the presenting symptoms are often vague and non-specific. This is the reason that there is involvement of orbit, brain with multiple cranial nerves palsies on presentation. The exact mechanism of spread of fungal infection only to sphenoid sinus is not known but its symptoms are explained due to involvement of the surrounding vital structures. Regarding the anatomical location of sphenoid sinus, its relations are,

Anteriorly, olfactory tract, optic chiasma, and frontal lobe.

Laterally, optic nerve, internal carotid artery, maxillary nerve *Posteriorly,* pituitary gland, sella turcica.

Lateral wall related to cavernous sinus, internal carotid artery, 3rd, 4th, 5th, and 6th cranial nerves.

Although fungal infection of paranasal sinuses is common but only sphenoid sinus involvement is rare disorder and difficult to diagnose¹, delay in treatment either due to lack of imaging facilities or lack of expertise, result in serious and potentially life threatening complications. The diagnosis and treatment of sinunasal disorders are relatively easy because symptoms and signs are obvious but in case of sphenoid sinus due to lack of nasal symptoms initially these patients do not present to ENT surgeons.

The most presenting symptom is headache, drastically emerging from vertex and sometimes, deep seated throbbing pain. Although pain may arise from other areas. Disturbance of facial sensation indicate spread of infection beyond the sinus wall to involve the upper two branches of trigeminal nerve.

The cavernous sinus is an immediate lateral relation and conveys the internal carotid artery and cranial nerves 3rd, 4th, 5th, 6th causing visual symptoms like diplopia, change of color vision and restriction of eye ball movements. All these non-rhinogenic symptoms mislead the patient as well as the doctor. So, commonly, patient presents to neurologist, ophthalmologist and sometime to neurosurgeon.

The best radiological investigation of choice is CT / MRI. As for concerning the final diagnosis and treatment, surgical opening of sinus is important; preferably with endoscopic sinus clearance and its confirmation of diagnosis on culture and sensitivity of specimen, followed by antifungal therapy.

Early diagnosis and treatment of fungal impaction of sphenoid sinus prevents fatal morbidity and mortality of this condition.

Material and Methods

This study was conducted in the department of ENT sheikh zayed hospital Lahore during four years from March 2001 to

April 2005. Overall, six patients in last one and a half year while ten patients were previously reported in this duration. The patients that comprises this study were seen by neurophysicians, neurosurgeons ophthalmologist and by Physicians which were referred to ENT department on findings based on CT/MRI scans (Fig. 1). All patients had second or third specialist referral than reported to ENT department. In this study we included the patients with opaque sphenoid sinus on CT / MRI. All patients excluded having involvement of other paranasal sinus, maxillary, ethmoidal sinus etc. All patients with sinunasal malignancy were excluded. Patients having acute rhinosinusitis were also excluded. From the study.

All patients were thoroughly investigated including routine like CBC, PT / APTT, Blood urea, creatinin, hepatitis profile, ECG, and X-Ray chest done. All patients had already CT scan or MRI done.

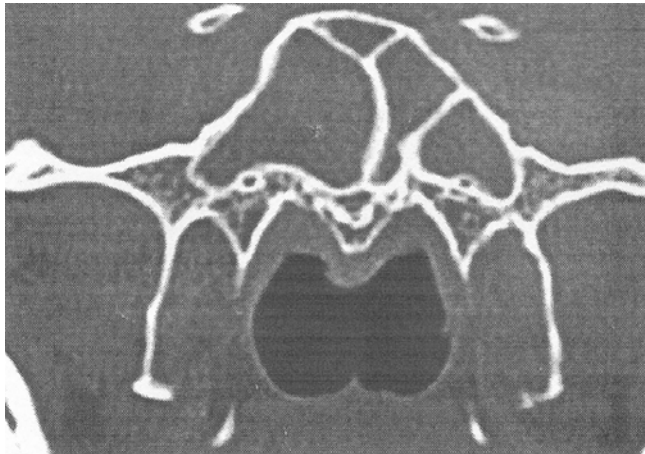
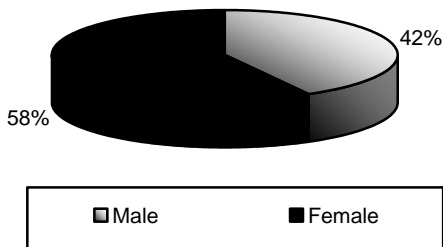


Fig. 1: CT Scan of paranasal sinus showing opacity in the sphenoid sinus.

In all patients' endoscopic clearance of sphenoid sinus done under general anesthesia. And specimen sent for culture and sensitivity, fungal study and histopathology.

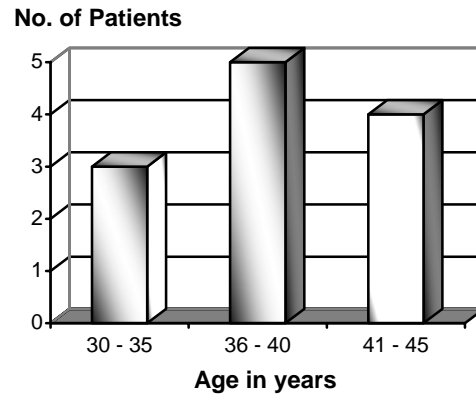
Results



Graph 1: Sex distribution.

All patients were given oral Itraconazole postopera-

tively for 3 to 6 months .These patients were followed up in out patient department .In all patients, CT scan was done postoperatively after three months and results collected after six months on completion of antifungal therapy.



Graph 2: Age distribution.

The results were assessed in terms of improvement of clinical features and calculated in percentage.

Table 1: Clinical feature.

Clinical features	No. of Patients	% age
Headache	16	100%
Visual change (Diplipia)	9	56.2%
Cranial nerve palsies	6	37.5%

Table 2: Improvement in clinical feature.

Clinical features	No. of Patients	% age
Headache Improved	11	100%
Visual changes (Diplopia)	11	68.7%
Cranial nerve palsies	7	43.7%

Discussion

In our routine ENT clinics, mostly patients having sinunasal diseases present with rhinogenic symptoms that are easily diagnosed and managed medically as well as surgically. The scenario is difficult when there is sinus disease without nasal symptoms both for diagnosis and treatment. Similary in this study we noted all these patients having isolated sphenoidal sinus disease but initially patients reported to neurophysicians, ophthalmologist and neurosurgeons for vague symptoms.

This study highlights number of points concerning isolated fungal sphenoiditis .There are reported references in literature to the late diagnosis of this condition and presentation with complication is due to the fact that patient are seldom seen initially by ENT surgeons².

The incidence of isolated sphenoid sinus involvement

in sinus disease has been decreased from 33% to 8% in more recent series³, but this is meant for acute sinus infections. As for concerning the fungal infection of sphenoid sinus no data is available in only sphenoid sinus infection. There is no significant age and sex discrimination, but females are slightly more than males. Regarding the predisposing factors in our patients, there was no significant correlation like use of steroids, uncontrolled diabetes, immunocompression noted in our patients.

Regarding the symptomatology headache appears to be the most common presenting symptom⁴. The typical headache is usually assigned as deep seated and throbbing, localized, more over vertex. Clinical observations have however involvement of retro-orbital, occipital and mastoid area. It must be stressed that due to location of the sphenoid sinus signs are seldom present as compared to the involvement of the other sinuses. In our patients, visual disturbance was the second most complaint encountered. Interestingly, headache improved in all 16 patients while visual changes like diplopia improved in 5 patients.

Regarding the diagnosis of this conditions plain x-ray films are useless for diagnosis because basal view films are always deficient and clinicians rarely familiar with this view.

A CT scan however appears to be the most useful means of demonstrating sphenoid sinus opacification.⁵ MRI is also helpful when intracranial extension is suspected. In CT scan there are areas of increased attenuation in paranasal soft tissue masses, while on unattenuated CT scan has strongly suggestive of fungal infections. In MRI, decrease signal intensity on T₁ and very decrease intensity on T₂ weighted images has even more characteristics of fungal sinusitis⁶.

The definite diagnosis is however based on fungal study. Surgical treatment is always indicated in all forms of fungal sinusitis in order to aerate the affected sinuses and to take the specimen for histopathological studies. The primary treatment consists of surgically opening of the sphenoid sinus. There are six approaches to the sphenoid sinus.⁷

These include a washout through natural ostia, puncture wash out through the anterior wall of sinus, intranasal sphenoidotomy, trans-septal sphenoidotomy, trans-ethmoidal sphenoidectomy and trans-antral sphenoidectomy. These days functional endoscopic sinus surgery technique is most

effective with good vision. In our practice we commonly use this technique safely for the clearance of sinuses.

Surgical treatment alone may not be able to treat this condition so adjuvant oral itraconazole is recommended for 3 to 6 months. Most authors recommend antifungal chemotherapy before and after the surgical clearance⁸. Systemic amphotericin B may be used for invasive type aspergilloma but it carries considerable morbidity. In this study in histopathologically it was semi-invasive aspergilloma, so surgical clearance followed by itraconazole was used. This treatment protocol was used in our study with good results.

Conclusion

It is concluded that patients having unexplained headache and visual disturbance should be evaluated for isolated sphenoidal sinus pathology. Computed Tomography / Magnetic Resonance Imaging are the investigations of choice to reach diagnosis.

Reference

1. A.C Urquhart, G. fung, W.A Mcintosh The JLO May 1989. vol 103. pp 526-527.
2. Dale, B, A.B, Mackenzie, I.J. The complications of sphenoid sinusitis journal of laryngology and otology, 1983; 97: 661-670.
3. Lew, D, Soutwick, F; S, Mout gomery, W.W, weber, A.L, baker, A.S. Sphenoid sinusitis, a review of 30 cases new England journal of medicine, 1983; 309: 1149-1154.
4. Wylle J.W, kem E.B and Djalibian, M. Isolated sphenoid sinus lesion, Laryngoscope, 1973; 83: 1252-1265.
5. Forbes. W fawcett. RA. Fsherwood, I, webb, R and fanxngton. T, CT in diagnosis of disease of paranasal sinuses. clinical radiology, 1978; 29: 501-511.
6. Sethi DS. Isolated sphenoid lesion: diagnosis and management. Otolaryngol Head Neck Surg. May 1999; 120 (5): 730-6.
7. Metson R, gliklich RE Endoscopic treatment of sphenoid sinusitis, otolaryngology, head and neck surgery 1996, 114:736-744.
8. Turgut S, Ozcan KM, Celikkanat S. Isolated sphenoid sinusitis. Rhinology. Sep 1997; 35 (3): 132-5.