

## Frequency and Pattern of Bone Marrow Infiltration in Non-Hodgkin's Lymphoma

Ayaz Lone,<sup>1</sup> Samina Naeem<sup>2</sup>

### Abstract

**Introduction:** Lymphomas are divided into two, groups Hodgkin's Lymphoma and Non-Hodgkin's Lymphoma. Staging of Non-Hodgkin's Lymphoma is important for the management and treatment of the patient. Bone marrow biopsy is one of the initial investigations carried out for staging of the disease along with other investigations. This study was carried out to determine the frequency of bone marrow infiltration at the time of diagnosis and various patterns of bone marrow involvement was noted.

**Materials and Methods:** Clinical history and physical findings were recorded and investigations were carried out. Bone marrow aspirate and trephine biopsies were carried out from posterior iliac crest. Aspirates and trephine biopsies were evaluated and assessed for cytology, marrow architecture, haemopoietic tissue and any lymphomatous infiltration. In cases with infiltration the infiltration pattern was studied.

**Results:** Bone marrow infiltration was found in 20 (40%) of cases. Most common pattern of infiltration seen was interstitial in 9 patients (45%) followed by

King Edward Medical University, Lahore – Pakistan diffuse pattern in 5 cases (25%). Focal para-trabecular involvement was seen in 4 cases (20%) and 1 case each of focal patchy and focal nodular pattern.

**Conclusion:** Bone marrow involvement in Non-Hodgkin's Lymphoma is more common in our setup as patients presents at a later stage. It is recommended that bone marrow examination should be performed as a part of staging investigations in patients with Non-Hodgkin's Lymphoma.

**Key Words:** Non-Hodgkin's Lymphoma (NHL), bone marrow Infiltration.

### Introduction

Lymphomas are malignant neoplasms characterized by the proliferation of cells native to the lymphoid tissue. They are divided into two broad groups, Hodgkin's lymphoma (HL) and non-Hodgkin's lymphoma (NHL). The NHL is a complex and heterogeneous group of malignant diseases, which are increasing in incidence in the developed world.<sup>1</sup> The incidence has increased from 6.9 / 100,000 to 17.4 / 100,000 in UK and the USA. NHL is slightly more common in males than in females and incidence rises with age. Patients usually present with painless lymphadenopathy but in some cases primary site may be skin, GIT, salivary glands, lungs, CNS and renal tract.<sup>2</sup>

WHO classification of NHL, which relies on cytological, phenotypic, genotypic and clinical characteristics of NHL, is used now and it includes all hemato-

---

Lone A.<sup>1</sup>  
Assistant Professor Haematology  
Fatima Memorial Hospital  
College of Medicine and Dentistry Lahore

Naeem S.<sup>2</sup>  
Professor Pathology

poietic and lymphoid neoplasm's.<sup>3</sup> Bone marrow trephine biopsy is one of the first investigation, which is carried out for staging<sup>4</sup>, along with clinical findings and other investigations like CBC, CT scanning, Ultrasonography and MRI. In many centers flow cytometry of bone marrow aspirates is also used in staging<sup>5, 6</sup>. Bone marrow infiltration by lymphoma places the patient in Stage IV disease.<sup>7</sup>

This study was conducted to see how many patients presenting to us have bone marrow infiltration at the time of diagnosis. This places them in Stage IV disease, which is associated with poor prognosis. Patterns and extent of bone marrow involvement in different varieties of NHL was also studied.

## Materials and Methods

This study was conducted at King Edward Medical University, department of Pathology, Lahore and included cases from the affiliated and referring hospitals from January 2004 to January 2005. The patients of Non-Hodgkin's Lymphoma diagnosed on tissue biopsy (nodal and extra nodal) were included in the study. Patients already on treatment and relapsed cases were not included. A detailed clinical history was taken from the patients and they were thoroughly examined clinically. Relevant investigations which included blood complete examination, urine complete examination, estimation of urea and creatinine levels, liver function tests, LDH levels, tissue biopsy, ultrasonography and CT scanning were also recorded. Bone marrow aspira-

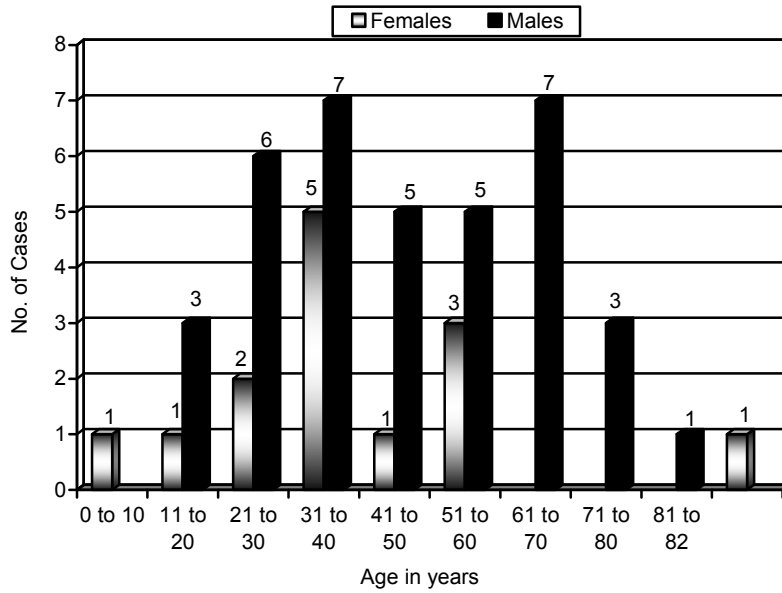
tion and trephine biopsy was performed from posterior Iliac crest, under local anesthesia with minimal discomfort. Marrow aspirates were stained with Wright-Giemsa stain. Sections of trephine biopsy were stained with Hematoxylin and Eosin. Assessment was made on cytological features of cells in aspirate smears. Trephine biopsies were evaluated for architecture, vessels, stroma, haemopoietic tissue and pattern of lymphoid infiltrates (diffuse, interstitial, focal, nodular, focal patchy and paratrabeular).

## Results

Out of 50 Non-Hodgkin's Lymphoma patients 13 (20%) were females and 37 (74%) were males. The age of patient ranged from 10 – 82 years with a mean age of 47.6 years S.D  $\pm$  18.78. Two patients (4%) belonged to pediatric age group, below 15 years (1 female and 1 male). The age and sex distribution of the cases is shown in figure 1.

Twenty % of our patients presented with isolated cervical lymphadenopathy and 18% had generalized lymphadenopathy. Twenty eight (56%) had Large B cell lymphoma (7 females and 21 males), 12 patients (24%) had small lymphocytic lymphoma (4 females and 8 males), 6 (12%) had Marginal zone lymphoma MALT type (2 females and 4 males), 3 (6%) had T-lymphoblastic lymphoma (males) and only 1 (2%) was of Peripheral T cell lymphoma (male).

**Fig. 1:** Age and Sex Distribution in Non-Hodgkin's Lymphoma in Females and Males (n = 50).



These patients presented in following stages of disease prior to bone marrow examination. Twenty patients (40%) were in Stage I, 11 (22%) patients were in Stage II, 17 (34%) were in Stage III and 2 (4%) were already in Stage IV with Liver involvement. Ten (20%) patients had B symptoms (3 females and 7 males) as well.

Bone marrow infiltration was seen in 20 (40%) of cases (5 females and 15 males). Infiltrate comprised of lymphoma cells along with areas of fibrosis and necrosis in some cases. Out of these 20 cases showing bone marrow infiltration 5 patients (25%) were in Stage I (1 female and 4 males), 3 (15%) were in Stage II (2 females and 1 male), 10 patients (50%) were in stage III (2 females and 8 males) and 2 (10%) were already in Stage IV with Liver involvement. Infiltration was present in 12 (42.8%) of the 28 cases of Large B-cell lymphoma, in 5 (41.6%) of the 12 cases of Small lymphocytic lymphoma, 2 (66.6%) of 3 cases T-lymphoblastic lymphoma and 1 (16%) of 6 cases Marginal zone lymphoma MALT type (Table 1).

Most common pattern of infiltration seen was interstitial in 9 patients (45%) followed by diffuse

pattern in 5 cases (25%). Focal Para-trabecular involvement was seen in 4 cases (20%) and there was 1 case each of focal patchy and focal nodular pattern (Table 2). Two patients showed peripheral spill over of lymphoma, both had infiltration of marrow too. These two cases had small lymphocytic lymphoma.

### Discussion

Fifty cases of Non-Hodgkin’s lymphoma were studied and the tissue biopsies were already categorized and typed by immunohistochemistry into B and T cell type. Out of these 20 (40%) had bone marrow infiltration. Bone marrow involvement was most frequently seen in Diffuse Large B Cell Lymphoma (60%) followed by Small Lymphocytic Lymphoma (25%). T-Lymphoblastic Lymphoma had 10% frequency and Marginal Zone Lymphoma MALT Type had lowest frequency (5%) in our study. In a local study carried out by Fauzia<sup>8</sup> et al the frequency of bone marrow involvement in Non-Hodgkin’s Lymphoma was

**Table 1:** Frequency of bone marrow involvement in different types of Non-Hodgkin’s Lymphoma in total Cases, females and males.

Key: Small Lymphocytic Lymphoma SLL Marginal zone B-cell lymphoma of MALT

		MALT		6	1	16.6	2	-	-	4	1	25
Total		T- Lymphoblastic cases		3	2	66.6	-	-	-	3	2	66.6
		Peripheral T-cell B.M		1	-	-	-	-	-	1	-	-
Total	Involved	Total		5	2	40	Involved		38.4	37	15	40.5
		No	%	No	%	No	%					
28	12	42.8	7	4	57.1	21	8	38				
12	5	41.6	4	1	25	8	4	50				

**Table 2:** Pattern of infiltration in different histological types of Non-Hodgkin's Lymphoma.

Types	Interstitial Infiltration	Diffuse Infiltration	Focal Infiltration
Large B-cell	5	3	*4
SLL	3	1	**1
MALT	-	1	-
T- Lymphoblastic	1	-	***1
Peripheral T-cell	-	-	-

\* Out of these 4 focal infiltrates, 2 were paratrabeular, 1 focal patchy and 1 focal nodular.

\*\* Focal paratrabeular infiltrate

\*\*\* Focal paratrabeular infiltrate

**Table 3:** Role of bone marrow examination in staging of Non-Hodgkin’s Lymphoma.

Type	Total No of Cases	Before Bone Marrow Examination								After Bone Marrow Examination							
		Stage								Stage							
		I		II		III		IV		I		II		III		IV	
		No.	%	No.	%	No.	%	No.	%	No.	%	No.	%	No.	%	No.	%
Large B-cell	28	11	39.2	8	28.5	7	25	2	7.1	8	28.5	5	17.8	3	10.7	12	42.8
SLL	12	3	25	1	8.3	8	66.6	–	–	3	25	1	8.3	3	25	5	41.6
MALT	6	3	50	1	16.6	2	33.3	–	–	3	50	1	16.6	1	16.6	1	16.6
T-Lymphoblastic	3	3	100	–	–	–	–	–	–	1	33.3	–	–	–	–	2	66.6
Peripheral T-cell	1	–	–	1	100	–	–	–	–	–	–	1	100	–	–	–	–
Total	50	20	40	11	22	17	34	2	4	15	30	8	16	7	14	20	40

Key: Small Lymphocytic Lymphoma SLL Marginal zone B-cell lymphoma of MALT

54.7%. Commonest type of lymphoma showing infiltration was Diffuse Small and Large Cell Type (REAL Classification). Kumar S<sup>9</sup> et al reported incidence of infiltration in 54.1% of their cases.

Durosinmi MA<sup>10</sup> et al reported bone marrow infiltration in 40% cases and most common pattern was diffuse type while infiltration was seen in 46.8% in a study carried out by Lim E J<sup>11</sup> et al again with diffuse infiltration being most frequent (74.4%).

In our study most common pattern of infiltration was Interstitial (45%) followed by Diffuse pattern (25%). Study carried out at Post-graduate Medical Institute, Lahore showed 34 % infiltration on bilateral trephine biopsy.<sup>12</sup> Another study carried by Aziz M showed a much higher incidence of marrow infiltration with follicular large cell lymphoma showing 77.8% followed by Immunoblastic Lymphoma 22.9%.<sup>13</sup>

Arber DA<sup>14</sup> et al found in their study that follicular grade 1 lymphoma was the most common type to involve the marrow (30.4%), followed by diffuse large B-cell lymphoma (16.0%), mantle cell lymphoma (9.3%), low grade B-cell lymphoma NOS (8.7%), lymphoplasmacytic lymphoma (8.4%), follicular grade2 (7.1%) and mature T and NK cell lymphoma (6.4%). Mixed pattern of infiltration was most common followed by paratrabeular, nodular, diffuse and interstitial. A study by Kittivoprat J<sup>15</sup> showed marrow infiltration of 28.8%. In our study after the bone marrow biopsy 5 patients from stage I, 3 from stage II and 10 from stage III showed bone marrow infiltration (Table 3). The corresponding aspirates were negative for infiltration

by lymphomatous infiltrates. This shows that the trephine biopsies are more helpful in diagnosing the infiltration by lymphoma.

**Conclusion**

Bone marrow involvement in Non-Hodgkin’s Lymphoma was seen in CS II and beyond, therefore it is recommended that bone marrow examination should be performed as a part of staging investigations in patients with Non-Hodgkin’s Lymphoma. Due to poor economic conditions, lack of awareness and treatment facilities in rural areas these patients come at a late stage of disease. Although some lymphomas are potentially curable due to advanced stage there prognosis becomes worse.

**References**

1. Sweetenham J, hieke K, Kerrigan M, Howard P, Pamela F, Smartt M et al. Cost – minimization analysis of CHOP, Fludarabine and Rituximab for the treatment of relapsed indolent B-cell NHL in UK. *Br J Haematol* 1999; 106: 47-54.
2. Aetiology and management of non-Hodgkin’s lymphoma In: Hoffbrand VA, Catovsky D, Tuddenham EGD, editors. *Postgraduate haematology*. 5<sup>th</sup> ed. Blackwell 2005: 735.
3. Ping Lu. Staging and classification of lymphoma. *Semin Nucl Med* 2005; 35 (3): 160-4.

4. Howell SJ, Grey M, Chang J, Morgenstern GR, Cowan RA, Deakin DP et al. The value of bone marrow examination in the staging of Hodgkin's lymphoma: a review of 955 cases seen in a regional cancer center. *Br J Haematol* 2002; 119: 408-411.
5. Palacio C, Acebedo G, navarrete M, Ruiz- Marrcellan C, Sanchez C, Blanio A, Lopez A. Flow cytometry in the bone marrow evaluation of follicular and diffuse large B-cell lymphoma. *Haematologica* 2001; 86 (9): 934-940.
6. Vinnicombe SJ, Reznick RH. Computerised topography in the staging of Hodgkin's disease and NHL. *Eur J Nucl Med Mol Imaging* 2003; 30 (Suppl 1): S 42-55.
7. Armitage JO. Staging Non- Hodgkin's lymphoma. *CA Cancer J Clin* 2005; 55: 368-376.
8. Butt F, Akhtar R, Rahmani T, Waheed A, Aman S, Hamid S. Bone marrow involvement in lymphoma: Incidence and co-relation with age and sex. *Biomedica* 2002; 18: 53-57.
9. Aziz Z, Rehman A and Akram M. *Singapore Med J* 2000; 41: 279-285.
10. Durosinmi MA, Mabayoje VO and Akinola NO. A review of histology of bone marrow trephine in malignant lymphomas. *Niger j Med* 2003; 12 (4): 198-201.
11. Lim EJ and Peh SC. Bone marrow and peripheral blood changes in NHL. *Singapore Med J* 2000; 41 (6): 279-85.
12. Khan FS, Tayyab M, Tasneem T and Chaudry NA. Bone marrow infiltration in NHL. *Pakistan Postgrad Med J* 2001; 11 (1): 8-11.
13. Aziz M, Naeem S, Sadiq A, Iodhi Y and Naveed IA. Bone marrow involvement in NHL. *Biomedica* 2000; 16: 10-13.
14. Arber DA and Geroge TI. Bone marrow biopsy involvement by NHL: Frequency of lymphoma types, pattern, blood involvement and discordance with other sites in 450 specimens 2005; 29 (12): 1549-57.
15. Kittivorapart J and Chinthammitr Y. Incidence and risk factors of bone marrow involvement by non-Hodgkin's lymphoma. *J Med Assoc Thai* 2011; 94 Suppl 1: S239-45.