

LOCALIZATION OF INTRADUCTAL MASS THROUGH THE OSTIUM OF THE DUCT USING WIRE GUIDED DUCTOGRAPHY TECHNIQUE

Muhammad Ovais Aslam¹, Zeeshan Sarwar², Aftab Ahmed³

ABSTRACT

PURPOSE

To localize intraductal mass (Papilloma) before surgery

MATERIALS

Guide wire 10-15 cm length of 2/3-0 Prolene/Surgipro

Plastic 26G to 20G I/V cannulas

Kopans breast lesion localization hook wire

Disposable syringe heaving 2ml non-ionic contrast

High intensity light and magnified glass.

METHODS:

Prepare patient in sitting or lying position adjust high intensity light clean the nipple with antiseptic lotion. Elicit the discharge with gentle

periareolar pressure or ask the patient to bring the discharge. If the opening with discharge is not clearly visualize use magnified glass or loop. Slowly inserted the wire into the duct orifice, it should pass freely into the duct. Introduce the 26G I/V plastic cannula coaxially over the guide wire and remove the guide wire. Gently inject 0.2-0.4 ml contrast, remove and the syringe and apply stopper. The cannula stopper assembly is secured to the breast with tape. Magnified craniocaudal view of the breast is taken, the 26G cannula removed and bigger length 22/20G cannula gradually passed over the guide wire according to distance of lesion from the ostium. Intraductal mass location is verified the hook wire is replaced with guide wire, the position of hook confirmed by mammographic film. The wire is cut 2cms from the nipple and pt. send to operation theater

RESULTS:

Hook localization has been successfully carried out in six patients.

CONCLUSION:

This is a new method of localization of intraductal mass it enables the surgeon to do microductectomy with minimal cosmetic effects to the breast.

Localization of Intraductal Mass through the ostium of the duct using Wire Guided Ductography Technique

INTRODUCTION:

A new technique is described for localizing of intraductal mass. The intraductal mass is localized through the ostium of the duct using wire guided ductography (DG) technique described by Aslam et al 2012. DG is a radiological procedure to find

Aslam M O¹

Professor of Radiology,
KEMU, Lahore

Sarwar Z²

Senior Registrar,
West Surgical ward,
KEMU, Lahore

Ahmed A³

Consultant Surgeon,
Liaquat National Hospital,
Karachi.

out pathology causing nipple discharge. It provides the diagnosis, exact location in the duct as filling defect or either ductal abnormality like ductectasia (1,2,3). Six patients selected after initial DG heaving intraductal mass for localization of tumor prior to surgery using wire guided technique for ductography. Kopans localization hook wire (William Cook Europe) is placed at the intraductal lesion through the ostium of the duct before surgery.

There are surgeons who believe that when there is problematic nipple discharge and surgical duct exploration is treatment of choice, the DG will not change the management; as a result, these surgeons do not request DG (4). In the past decade due to advancement in interventional radiology procedures, surgical excision of large segment of the breast has been replaced to microsurgery and excision of small portion of breast tissue.

After diagnosis of intraductal tumor the patient is prepared for surgery to remove it, most of the centers use methylene blue injection (5) into the discharging duct to facilitate localization, then circumareolar incision was performed, the ducts and lobules identified by the presence of the blue dye and excision was performed of the dye-stained ducts and lobules. With our technique the surgeon after tiny circumareolar incision localize the hook remove it and the mass.

MATERIALS:

Stiff plastic guide wire 10-15 cms. Prolene/Surgipro 2-0/3-0 (Polypropylene mono filament non-absorbable surgical suture). Readily available in the operation theatres can be used as guide wire.

Plastic 26G to 20G intravenous cannulas used for cannulation and placement of the hook wire.

Kopans breast lesion localization hook wire (William Cook Europe)

Disposable syringe heaving 2ml non-ionic contrast.

High intensity light and magnified glass.

METHODS:

The procedure is planned when nipple discharge is present (3). Prepare patient in sitting or lying position adjust high intensity light clean the nipple with antiseptic lotion. Elicit the discharge with gentle periareolar pressure or ask the patient to bring the discharge most of the time patient know

specific point “trigger point” (1, 2, 3, 5) to bring out discharge (Fig 1). On examination of the ostium of the duct with discharge compared to the adjacent normal duct openings, the orifice of discharging duct may be slightly erythematous (4). If the opening with discharge is not clearly visualize use magnified glass or loop. Slowly insert the wire into the duct orifice, it should pass freely and painlessly into the duct, if patient feel pain make sure your wire is in the duct, pulling the nipple and spinning the wire can help in passing the wire deep into the duct (Fig 2). Introduce the 26G I/V cannula coaxially over the guide wire (Fig 3). The guide wire is removed the discharge is seen coming up in the hub of the cannula it confirm that the duct with pathology is cannulated (Fig 4). Gently inject 0.2-0.4 ml contrast, remove the syringe and apply stopper. The cannula stopper assembly is secured to the breast with tape. Magnified craniocaudal view of the breast is taken (Fig 5), the image is view and the guide wire is again passed through the cannula another craniocaudal view is taken the guide wire will appear as filling defect in the contrast filled duct. Check the relationship of wire, tip of the cannula and the tumour. If the guide wire and cannula assembly is not in the branch of the duct containing the tumour remove the cannula reposition the wire. If the tumour is deep in the duct bigger length cannula (22/20G) exchanged till the tip of the cannula is in relation to the tumour now the guide wire is replaced with hook wire through the cannula. Confirm the position of hook by mammographic film (Fig 6). The wire is cut 2cms from the nipple. A plastic disposable drinking cup is placed over the breast secured in position with sticking tape and patient send to Operation Theater.

RESULTS:

This technique has been successfully carried out in six patients between the year 2007 - 2011. The ages of the patients were between 30 to 56 years. This technique is more precise and accurate in intraductal mass localization for the surgeon than the methylene blue injection technique in which lobules had to be removed. This technique enables microsurgery to be done with selective removal of the duct containing the mass. For successful localization with hook the patient selection is important its better performed in the cases heaving

tumor up to less than 5cm from the nipple with fairly straight course of the duct.

CONCLUSION /DISCUSSION:

This is a new method of localization of intraductal mass uses wire guided ductography technique, the surgeon feel comfortable during operation to locate the lesion heaving hook around it and enables the surgeon to do microsurgery with minimal cosmetic effects to the breast.

REFERENCES:

1. Muhammad Ovais Aslam, Salwa Ramadan , Muneera Al Adwani, Technical Report : Wire Guided Ductography. **European Journal of Radiology** 81 (2012) 1543-1545.
2. S. Horatio Slawson, Braddley A. Johnson, Ductography: How to and what it? **Radiographics** 2001; 21:133-150.
3. Audrey K. Tucker, Yin Yuen Ng. Text book of Mammography, 2nd edition. Churchill Livingstone 2001; 260.
4. Mark A. Guenin, MD Benign Intraductal Papilloma: Diagnosis and Removal at Stereotactic Vacuum-assisted Directional Biopsy Guided by Galactography **Radiology** 2001; 218:576-579
5. Hou MF, Huang TJ, Huang YS, Hsieh JS. A simple method of duct cannulation and localization for galactography before excision in patients with nipple discharge. **Radiology** 1995; 195:568-569.
6. Cardenosa G, Doudna C, Elelund GW. Ductography of the breast: Technique and findings. **AJR Am J Roentgenol** 1994; 162: 1081-1087.

Fig 1. Bloody discharge from ostium of single duct

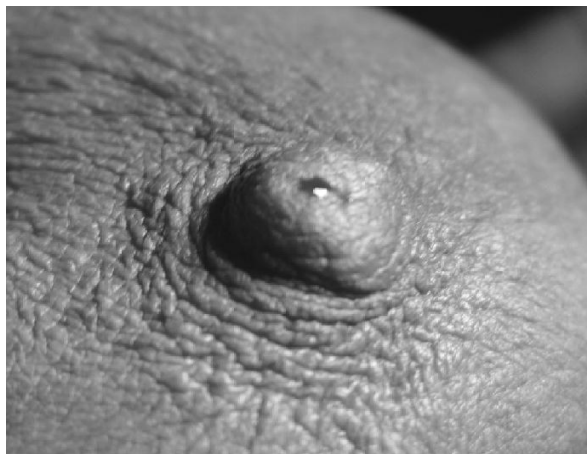

Fig 2. Guide wire is inserted into the duct

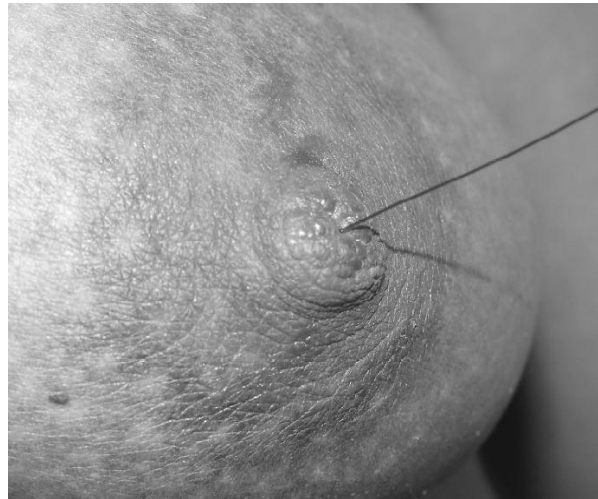


Fig 3 : Cannula is inserted into the duct over the guide wire

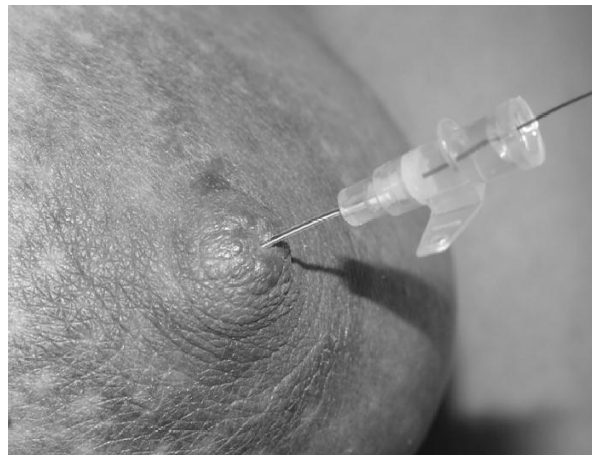


Fig 4: Cannula is completely inserted into the duct, the Guide wire is removed, Secretions seen in the hub of cannula

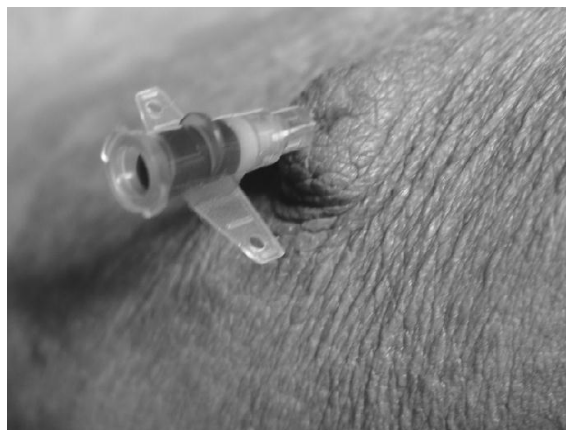

Fig 5: Irregular filling defect is seen in the duct (Arrow).

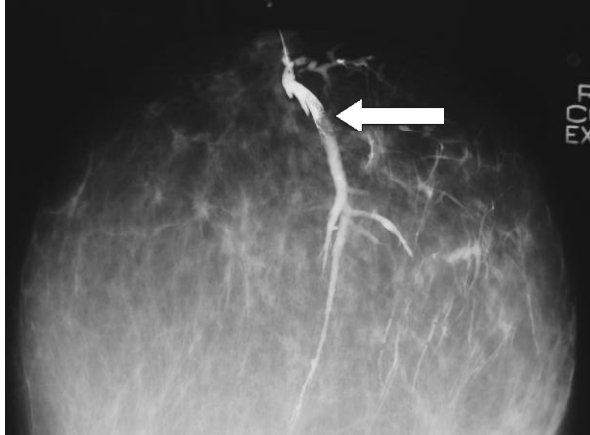


Fig 6: Kopans hook is placed in the duct containing the mass.

