

A COMPARATIVE STUDY TO DETERMINE THE EFFECTIVENESS OF THREE SURGICAL TECHNIQUES USED IN THE TREATMENT OF SEVERE CONGENITAL IDIOPATHIC CLUB FOOT USING THE DIMIGLIO SCORING SYSTEM.

Usman Zafar Dar ¹, Ayesha Saeed ², Abdul Latif Sami ³, Syed Muhammad Awais ⁴

ABSTRACT:

BACKGROUND:

Club foot, or congenital talipes equinovarus (CTEV), is a congenital deformity with an incidence of 1 in 1000 live births. The deformity is 3-dimensional with 4 components including cavus, forefoot adduction, heel varus and equinus (CAVE). Severity of the CTEV is determined by Dimiglio scoring system. Benign and moderate forms can be treated conservatively but severe and very severe forms require extensive posteromedial soft tissue release for its correction. The posteromedial soft tissue release can be done

through medial Turco incision, Cincinnati incision, and Cincinnati incision with medial rotational fasciocutaneous flap.

OBJECTIVE:

The Objective of this study is to determine the effectiveness of three types of surgical techniques (Medial Turco, Cincinnati and Cincinnati with medial rotational fasciocutaneous flap), used in the posteromedial release of severe CTEV.

METHODOLOGY:

This Interventional Longitudinal study was conducted at Department of Orthopedic Surgery & Traumatology Mayo Hospital Lahore for a period of one year. A total of 45 patients were diagnosed as severe CTEV and 15 cases were randomly divided in three groups each. Patients were operated and followed-up in OPD by Dimiglio scoring and wound healing at 0, 4th and 18th week postoperatively to determine the amount of correction. . Data was analyzed using SPSS 16.

RESULTS:

Patients in Group-A were treated with Cincinnati with medial rotational fasciocutaneous flap, in group B with Cincinnati Technique and in group-C with Medial Turco Technique.

In group A, 7 (46.7%) cases had excellent outcome while 8 (53.3%) cases had good outcome. In group B, 2 (13.3%) cases had excellent outcome, 10 (66.7%) cases had good outcome and 3 (20%) cases had fair outcome. In group C, none of the case had excellent outcome while 9 (60%) cases had good outcome and 6 (40%) cases had fair outcome depending upon Dimiglio scoring.

Dar UZ¹

Medical Officer

Dept. of Orthopaedic Surgery

Mayo Hospital, Lahore

Saeed A²

Women Medical Officer

Dept. of Orthopaedic Surgery

Mayo Hospital, Lahore

Sami AL³

Associate Professor

Dept. of Orthopedic Surgery,

KEMU/Mayo Hospital, Lahore.

Awais SM⁴

Chairman Dept. of Orthopedic Surgery,

KEMU/Mayo Hospital, Lahore.

There was significant difference among all groups for final outcome of the incision type.

CONCLUSION:

This study showed that Cincinnati with medial rotational fasciocutaneous flap and Medial turco incision are better than Cincinnati incision alone and Cincinnati with medial rotational fasciocutaneous flap is better than both other groups.

KEY WORDS:

Congenital talipes equinovarus, Clubfoot, Cincinnati incision, medial rotational fasciocutaneous flap, Medial Turco incision.

INTRODUCTION:

Club foot or congenital talipes equinovarus, or, is one of the most common congenital orthopedic condition. Up to 50% cases of CTEV are bilateral with an incidence of 1:1000 live births approximately in United Kingdom (1-3). It is always recognizable at birth but with recent advances it is now frequently diagnosed at 18 to 20 weeks of gestation by ultrasound(2). Idiopathic CTEV is a complex foot deformity in an otherwise normal child consisting of four components:

equinus, heel varus, forefoot adduction and cavus(4). The aim of treatment is to achieve a painless, plantigrade foot with good mobility. The initial treatment is nonsurgical as agreed by most orthopedic surgeons and begins soon after birth. There are many methods, most of which involve serial manipulation and casting. The nonsurgical treatment is not always successful and may end up in complications like partial correction, recurrence etc. this has led to popularity of surgical intervention within the first year of life(5). However, surgical treatment may follow complications like painful, stiff and weak feet(6).

The condition is variable in its clinical course and severity. It may be difficult to assess the severity at initial presentation or to compare the results of treatment. Many classification systems have been proposed to address this problem.

The system of Diméglio et al is derived from a detailed scoring system based on the measurement of eight parameters as seen in Table 1. From the score, which has a maximum of 20 points, the deformity can be graded as benign, moderate, severe or very severe (2).

The Table 1 shows system of Diméglio et al for the classification of severity congenital talipes equinovarus

Parameters Measured		Reducibility (degrees)	Score	0 week score
Equinus deviation in sagittal plane.		90 to 45	4	
Varus deviation in frontal plane.		45 to 20	3	
Derotation of calcaneopedal block in horizontal plane.		29 to 0	2	
Adduction of forefoot relative to hind foot in horizontal plane.		0 to -20	1	
Other elements considered				
Posterior crease marked			1	
Mediotarsal crease marked			1	
Plantar retraction or cavus			1	
Poor muscle condition			1	
Possible total score			20	
Grade	Type	Score	Reducibility (Degrees)	
I	Benign	1-4	>90% soft-z, resolving	
II	Moderate	5-9	>50% soft-stiff, reducible, partially resistant	
III	Severe	10-14	>50% stiff-soft, resistant, partially reducible	
IV	Very severe	15-20	<10% stiff-stiff, resistant	

Table 1: Dimeglio et al Classification of severity of congenital talipes equinovarus.

Severe CTEV is surgically treated by posteromedial soft tissues release during which lengthening of tendo achilles, tibialis posterior, flexor hallucis longus, flexor digitorum longus and adductor hallucis is done. Superficial deltoid ligament, fibulocalcaneal ligament, Henrys knot are released, and capsulotomies of subtalar, talonavicular and tibiotalar joints are done. Posteromedial soft tissue release is done by medial incision of Turco, two incision technique, transverse circumferential incision (Cincinnati incision), and Cincinnati incision with medial rotational fasciocutaneous flap (7). Among all the above incisions medial Turco incision and Cincinnati incisions are widely practiced for posterior medial soft tissues release of severe CTEV surgery (8). Medial Turco incision provides adequate exposure of medial soft tissues but approach to the posterior and lateral tight structures is technically difficult. This may result in inadequate surgical correction of the deformity. Transverse circumferential incision (Cincinnati incision) provides excellent exposure on the medial, posterior and lateral aspects of the ankle joint for surgical release of the tight structures, but it is difficult to close the wound with foot in corrected position. To overcome this problem medial rotational fasciocutaneous flap is developed with Cincinnati incision (9). This flap provides skin cover on the medial side and wound can be closed without tension with foot in fully corrected position (10).

In this study, medial Turco incision, Cincinnati and Cincinnati incision with medial rotational fasciocutaneous flap are being compared for their efficacy in posteromedial soft tissue release of severe CTEV deformity in term of wound healing and correction of deformity, as determined by Dimiglio scoring system.

METHOD:

The study was conducted in department of orthopedics and Traumatology Unit 1, Mayo hospital Lahore. A total of 45 consecutive severe and very severe idiopathic club feet of 35 patients were included in the study and placed randomly in three groups of 15 club feet each. A single team assessed and scored the patients according to Dimiglio scoring system. Patients in Group-A were treated with Cincinnati with medial rotational

Fasciocutaneous flap, in Group-B with Cincinnati Technique and in Group-C with Medial Turco Technique. A surgical team lead by a single surgeon performed all the surgeries from January 2011 to December 2011.

All patients were operated in General anesthesia under tourniquet control. A single club foot was operated for the patients with bilateral club feet at a time. Group A and B patients were placed in prone position while Group C patients were operated supine. Patients were discharged on the first post-operative day and kept under close follow up for a period of six months for regular POP change. The same team of surgeons performed Dimiglio scoring of the patients at preoperative, immediate postoperative and at 4th and 18th week of follow up.

OPERATIVE TECHNIQUES:

Group A: Cincinnati incision with Medial Rotational Fasciocutaneous flap:

Fig 1(A):

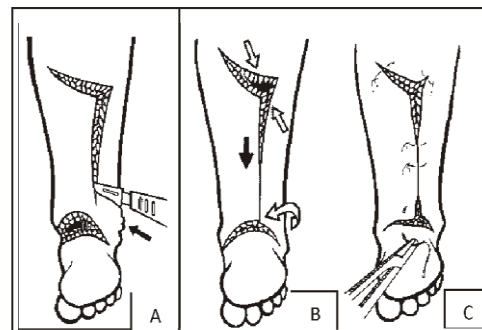


Figure 1: Cincinnati with medial rotational fasciocutaneous flap

The approach starts with a classic Cincinnati incision. A 45° medially angulated flap is created by making a vertical incision on the lateral side of the tendoachilles till the distal extent of proximal third of lower leg. **Fig 1 (B):** In order to cover the posteromedial defect (curved white arrow) the flap is moved downwards onto the blemish area (black arrow) and the surplus skin on the posterolateral side is pulled medially. The pliability of the skin on the lateral side of the longitudinal incision makes easy cover of the wound (oblique white arrow).

Fig 1 (C): After reasonable mobility of the flap is attained, both distal and proximal edges of the flap are approximated (11, 12).

Group B: Cincinnati incision:

It is a transverse circumferential incision extending from the navicular-cuneiform joint medially, and runs posteriorly at the level of tibiotalar joint, ending at sinus tarsi on lateral aspect of the foot as shown in fig 2 (A,B,C) (11, 13).

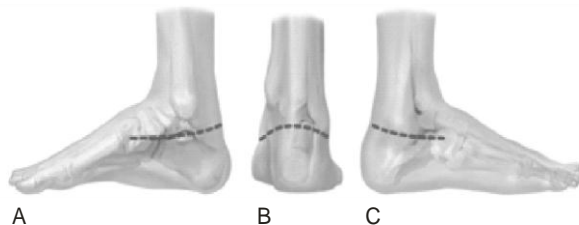


Figure 2; Cincinnati Incision

GROUP C: MEDIAL TURCO INCISION:

Medial Turco incision extends from the first metatarsal proximally under the medial malleolus to the tendoachilles. Medial Turco incision provides adequate access to expose medial soft tissues but approach to the posterior and lateral

tight structures is technically difficult which may result in inadequate surgical release (14).

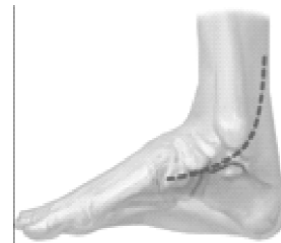


Figure 3; Medial Turco Incision

RESULTS:

The frequency of severe CTEV was noted as 54.6%. The mean age of the cases was 2.18 ± 1.04 years with There were 30 (67%) male cases and 15 (33%) female cases in the study. The male to female ratio was of 2:1. In 15 (33%) patients, only right side was involved, in 10 (23%) patients, only left side was involved while in 20 (44%) cases, both sides (bilateral) were involved.

Table 2; Comparison of total Dimiglio score among all groups at different follow-up visits
Group A= Cincinnati with medial fasciocutaneous flap, Group B= Cincinnati Incision
Group C= Medial turco incision

Study groups		pre-op	At 0 week	At week 4	At week 18
Total score	Group A	14.94±1.64	7.12±2.52	6.35±2.52	6.06±2.41
	Group B	14.67±1.45	7.67±1.54	7.47±1.64	6.87±1.73
	Group C	15.69±1.25	8.00±1.10	7.63±1.26	7.56±1.36
	p-value	0.139	0.389	0.124	0.086

In group A, the mean total score of the patients was 14.94 ± 1.64 pre-operatively and 7.12 ± 2.52 post-operatively after 0 week which was reduced to 6.35 ± 2.52 after 18 weeks of treatment. In group B, the mean total score of the patients was 14.67 ± 1.45 pre-operatively and 7.67 ± 1.54 post-operatively after 0 week which was reduced to 6.87 ± 1.73 after 18 weeks of treatment. In group C, the mean total score of the patients was 15.69 ± 1.25 pre-operatively and 8.00 ± 1.10 post-operatively after 0 week which was reduced to 7.56 ± 1.36 after 18 weeks of treatment. There was insignificant difference among all groups. Group A and B showed more reduction in total score as compared to group C but the difference was insignificant (p-value>0.05).

In group B and C, infection was present in 1 (6.7%) case, while in group A none of the case showed infection during follow-up. Wound Dehiscence was observed in 1 (6.7%) case in group A. There was statistically insignificant difference among the study groups. (P-value= 0.359)

DISCUSSION:

Treatment of congenital talipes equinovarus (clubfoot) begins as soon as possible with serial casting techniques with 20-95% of success rate. However, in cases of failure of serial casting or recurrence, or in whom parents seek medical intervention too late, surgical treatment can be performed (5). There are different types of surgical procedures according to the remaining deformities ranging from simple posterior release and tendon

transfers to extensive procedures like postero-medial release and complete subtalar release. The tremendous benefit of Cincinnati approach is that it gives exposure to all structures horizontally across the tarsus. (8, 13). After all the severe club foot surgeries soft tissue coverage is a demanding task. The possibility of skin closure is further hampered by various factors like amniotic strings, arthrogyposis multiplex congenita (decreased elasticity), scars from previous surgeries etc (7, 13, 15).

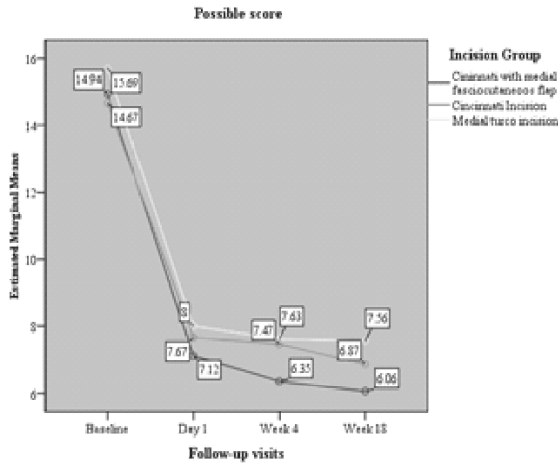


Figure 4: Graphical representation of the results with the three approaches

In our trial, with Cincinnati with medial fasciocutaneous flap, 46.7% cases had excellent outcome while 8 (53.3%) cases had good outcome, with Medial turco incision, only 13.3% cases had excellent outcome, 66.7% cases had good outcome and 20% cases had fair outcome and with Cincinnati incision alone none of the case had excellent outcome while 60% cases had good outcome and 40% cases had fair outcome. There was significant difference among all groups for final outcome of the incision type. This showed that Cincinnati with medial rotational fasciocutaneous flap and Medial turco incision are better than Cincinnati incision alone and Cincinnati with medial fasciocutaneous flap is better than both other groups. Thompson GH et al achieved excellent results in 86% of cases corrected with Turco’s postero-medial release. Hoque MF got excellent to good results in 75% rigid clubfeet and had 11% fair and 13% poor results with Turco’s postero-medial release. With Turco’s postero-medial release, in patients of 9

months to 4 years of age, Otremski I achieved full correction, of equinus in 98%, heel varus in 91%, cavus in 85% and forefoot adduction in 91% of cases (16-18).

With Cincinnati with medial rotational fasciocutaneous flap, 46.7% cases had excellent outcome, Medial Turco technique had excellent 13.3% outcome and 66.7% cases had good outcome and with Cincinnati Incision alone, 60% cases had good outcome and 40% cases had fair outcome. There was significant difference among all groups for final outcome of the incision type. Thus it was concluded that Cincinnati with medial rotational fasciocutaneous flap is better approach than other two incisions.

REFERENCES:

1. Sami AL, Hanif A, Awais SM. Causes of Failure of Conservative Treatment of Club Foot. *Annals of King Edward Medical University*. 2010;16(1).
2. Wainwright AM, Auld T, Benson MK, Theologis TN. The classification of congenital talipes equinovarus. *Journal of Bone & Joint Surgery, British Volume*. 2002;84(7):1020-4.
3. Saghieh S, Bashoura A, Berjawi G, Afeiche N, Elkattah R. The correction of the relapsed club foot by closed distraction. *Strategies in Trauma and Limb Reconstruction*. 2010;5(3):127-35.
4. Dobbs MB, Rudzki J, Purcell DB, Walton T, Porter KR, Gurnett CA. Factors predictive of outcome after use of the Ponseti method for the treatment of idiopathic clubfeet. *The Journal of Bone & Joint Surgery*. 2004;86(1):22-7.
5. Morcuende JA, Dolan LA, Dietz FR, Ponseti IV. Radical reduction in the rate of extensive corrective surgery for clubfoot using the Ponseti method. *Pediatrics*. 2004;113(2):376-80.
6. Changulani M, Garg N, Rajagopal T, Bass A, Nayagam S, Sampath J, et al. Treatment of idiopathic club foot using the Ponseti method Initial experience. *Journal of Bone & Joint Surgery, British Volume*. 2006;88(10):1385-7.
7. Anand A, Sala DA. Clubfoot: Etiology and treatment. *Indian journal of orthopaedics*. 2008;42(1):22.

8. Macnicol M, Nadeem R, Forness M. Functional results of surgical treatment in congenital talipes equinovarus (clubfoot): a comparison of outcome measurements. *Journal of Pediatric Orthopaedics B*. 2000;9(4):285-92.
9. Morcuende JA. Congenital idiopathic clubfoot: prevention of late deformity and disability by conservative treatment with the Ponseti technique. *Pediatric annals*. 2006;35(2):128.
10. Reize C, Exner GU. Acute correction of severe neglected club feet using a circumferential incision. *Journal of Pediatric Orthopaedics B*. 2007;16(3):213-5.
11. Joseph B, Ajith K, Varghese R. Evaluation of the hemi-Cincinnati incision for posteromedial soft-tissue release in clubfoot. *Journal of Pediatric Orthopaedics*. 2000;20(4):524-8.
12. Szabó G, Mester S, Tóth F. Cincinnati incision combined with medial rotation fasciocutaneous flap for clubfeet with pathologic soft tissues. *Orthopedics*. 2005;28(4):368-70.
13. Lubicky JP, Altiok H. Regional fasciocutaneous flap closure for clubfoot surgery. *Journal of Pediatric Orthopaedics*. 2001;21(1):50-4.
14. Desai L, Oprescu F, DiMeo A, Morcuende JA. Bracing in the treatment of children with clubfoot: past, present, and future. *The Iowa orthopaedic journal*. 2010;30:15.
15. Gray K, Pacey V, Gibbons P, Little D, Frost C, Burns J. Interventions for congenital talipes equinovarus (clubfoot). *Cochrane Database Syst Rev*. 2012;4.
16. Thompson GH, Richardson A, Westin G. Surgical management of resistant congenital talipes equinovarus deformities. *The Journal of bone and joint surgery American volume*. 1982;64(5):652.
17. Hoque M, Uddin N, Sultana S. Operative management of rigid congenital club feet in Bangladesh. *International orthopaedics*. 2001;25(4):260-2.
18. Otremski I, Salama R, Khermosh O, Wientroub S. An analysis of the results of a modified one-stage posteromedial release (Turco operation) for the treatment of clubfoot. *Journal of Pediatric Orthopaedics*. 1987;7(2):149-51.