

VESICOVAGINAL FISTULA REPAIR THROUGH VAGINAL APPROACH

Shahzad Ashraf,¹ Nadir Hussain,² M. Nasir Ibrahim,³ Jamshed Rahim⁴

Abstract

Objectives: To evaluate the outcome of trans-vaginal repair of vesico-vaginal fistula through vaginal approach.

Study Design: Prospective study.

Material and Methods: This study was carried out in Department of Urology, Shaikh Zayed Postgraduate Medical Institute and National institute of Kidney Diseases, Lahore for the period extending from April 2009 to April 2014. Total 17 patients were included in the study. History, physical examination and findings on investigations were reviewed. In all patients cystoscopy and vaginal examination was performed to see fistula site and ureteral orifices. Then trans-vaginal repair was done in all cases.

Results: VVF repair was performed on 17 patients

aging 25 to 45 years (mean 35.83 ± 7.37 years). The symptoms preceded for a period of 3 months to 8 years. The cause was gynecological hysterectomy 8 (47.05%), obstetric C-section 7 (41.17%) and obstructed labor 2(11.76%). In three of our patients VVF was previously repaired trans-abdominally. On cystoscopy no patients had more than one fistula. In two (11.76%) patients fistula was supratrigonal. The average size of fistula was 2.05 cm, detail of fistula site and size is given in table. One patient had leakage on second post op day that was managed with change of Foleys catheter. Successful repair was achieved in all patients and no patient required second attempt. No ureteric injury and other complications were observed.

Conclusion: Trans-vaginal repair of VVF avoid laparotomy and bladder bisection. It has reduced hospital stay and morbidity.

Key Words: Urinary bladder, vagina, fistula, VVF.

Ashraf S.¹
Professor and Head of Department
Kidney Transplant Unit Sheikh Zayed Hospital, Lahore

Hussain N.²
Assistant Professor
Kidney Transplant Unit Sheikh Zayed Hospital, Lahore

Ibrahim M. N.³
Senior Registrar
Kidney Transplant Unit Sheikh Zayed Hospital, Lahore

Rahim J.⁴
Assistant Professor
Department of Urology Sheikh Zayed Hospital, Lahore

Introduction

Vesicovaginal fistula (VVF) is an abnormal communication between the urinary bladder and vagina resulting in an uncontrollable, involuntary leakage of urine per vagina.¹ Vesicovaginal fistula in females is still a dreadful complication in both developing and developed world. The leading cause in developing countries is deficient obstetric facilities and prolonged obstructed labor. Contrary to this radical hysterectomy and radiation to pelvic tumors are the causes in progressed countries.^{2,3} The WHO showed that about 50 lac females are affected with fistulae from obstetric reasons every year.⁴

Vesicovaginal fistula is treated by various surgical ways. Better diagnosis and in time repair is required for successful closure of a VVF.⁵ Fistula closure results in improvement of sexual health and social life. VVF repair through vaginal approach requires less operative time and decrease in hospital stay and analgesia. If patient fulfills inclusion and exclusion criteria trans-vaginal repair is better than abdominal repair.⁶ Recurrence is dreadful complication after VVF repair.

Successful repair of VVF depends on the experience of the surgeon and adhering to basic surgical principles. Very high success rates were seen with flap interposition.⁷

Material and Methods

It is a prospective study conducted at Department of Urology Sheikh Zayed Hospital, Lahore From April 2009 to April 2014.

Inclusion Criteria

- Unoperated VVF.
- Recurrent VVF after abdominal approach.
- Recurrent VVF after vaginal approach.
- Supratrigonal VVF.

Exclusion Criteria

- Small immobile vagina.
- Concomitant urethrovaginal or ureterovaginal fistula.
- Radiation induced VVF.
- Malignant fistula.
- Multiple fistulae.

After taking informed consent and approval from ethical committee, demographic information and disease related history of patients obtained at the Department of Urology Sheikh Zayed Hospital, Lahore. Urine culture and sensitivity, KUB ultrasonography, cystography and intravenous urography were performed to diagnose VVF and rule out ureterovaginal fistulae. All patients underwent Examination under Anesthesia and cystoscopy to assess urinary bladder capacity, location and relation of fistula to ureteric orifice. Size of vagina and fistula and scarring from previous repair was assessed before opting for vaginal repair.

A gap of three months was given before VVF repair for inflammatory process to stop. Procedure performed in lithotomy position. Temporary ureteric cath-

eter passed before starting procedure if fistula was near to ureteric opening. Circumferential incision was made around the fistulous opening. Vagina dissected from urinary bladder. Defect in urinary bladder and vagina repaired separately with vicryl 2/0 or 3/0. Vagina was packed with Povidone iodine soaked gauze for 24 hours. Patient was discharged home on 4th post op day and called back for removal of Foleys catheter on 10th post-surgical day.

Follow up was done at one month, three months, six months and every year afterwards. The couple was prohibited from sexual contact for three months. Procedure was declared successful if patient was free of urinary leak for 3 months.

Results

VVF repair was performed on 17 patients aging 25 to 45 years (mean 35.83 ± 7.37 years). The symptoms preceded for a period of 3 months to 8 years. The cause was gynecological hysterectomy 8 (47.05%), obstetric C-section 7 (41.17%) and obstructed labor 2 (11.76%) as shown in graph. In three of our patients VVF was previously repaired by trans-abdominal approach (table 3). On cystoscopy no patients had more

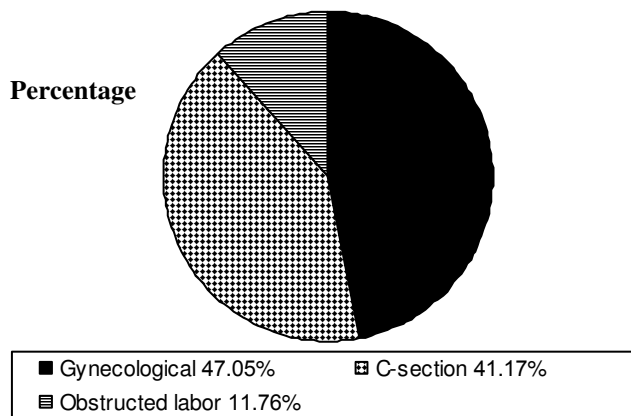


Fig. 1: Etiology of VVF (Graph).

Table 1: Site of VVF.

| Site of VVF | Number N = 17 | Percentage |
|---------------|------------------|------------|
| Trigonal | N = 15 | 88.23% |
| Supratrigonal | N = 02 | 11.76% |

Table 2: Size of VVF.

| Size of VVF | Number of Patients | Average Size | | Percentage |
|-------------|--------------------|--------------|---------|------------|
| < 2 cm | N = 10 | 1.67 cm | 2.05 cm | 58.88% |
| > 2 cm | N = 07 | 2.60 cm | | 41.17% |

Table 3:
Primary / secondary repair.

| Type of Repair | Initial Repair | Repair | Number of Patients | Percentage |
|------------------|-----------------|---------------|--------------------|------------|
| Primary repair | - | Trans-vaginal | N = 14 | 82.35% |
| Secondary repair | Trans-abdominal | Trans-vaginal | N = 03 | 17.64% |

than one fistula. In two (11.76%) patients fistula was supratrighonal. The average size of fistula was 2.05 cm, detail of fistula site and size are given in (tables 1 and 2). One patient had leakage on second post op day that was managed with change of Foleys catheter. Successful repair was achieved in all patients and no patient required second attempt. No ureteric injury and other complications were observed.

Discussion

VVF is mostly a problem of developing nations arising from poorly managed labor and gynecological surgeries.^{8,9} In VVF, the persistent odor and leakage of urine badly affects social status of females. They are unable to perform their religious activities and even get divorce in some cases with psychological implications.¹⁰

Lee et al used tissue interposition for transvaginal closure of VVF and he was successful in 97% of cases. Mean age of patients in his study was 45 years. VVF was found in 88% of the women from gynaecological origin. Mean age in our study was 35.83 years and 47.05% of VVF were due to gynaecological cause. This difference seems to be because of increased number of hysterectomies in United States and poor obstetric care in Pakistan.¹¹

Shoukry MS et al, used vaginal flap reinforcement for vesicovaginal fistula repair and he was successful without complications.¹² While we achieved 100% results without any reinforcement or interposition of different tissues.

In 2005 Hanif MS published study at Karachi. According to his study 71.4% of patients developed fistula from obstetric and 28.6% from gynaecological cause.¹⁰ In 2006 at Larkana Jalbani MH showed causes of Vesico-vaginal fistula were obstetrical in 80%,

Gynecological in 17.5% and in 2.5% the fistula developed due to other causes.¹³ Our study shows reduced obstetric 52.95% etiology. Perhaps this is because of improvement in obstetric care in Pakistan with passage of time.

Many urologists and gynecologists used omental, peritoneal,¹⁴ Martius flaps¹⁵ and gracilis muscle¹⁶ as an interposition between vagina and bladder to provide support for VVF repair. Laparoscopic¹⁷ and robotic repair¹⁸ and closure of fistula with fibrin glue¹⁵ have been introduced. But we performed vaginal repair for VVF without the use of any of the above means with 100% results. Three of our patients presented after failure of transabdominal repair but we were successful in repairing them through transvaginal approach.

Conclusion

Trans-vaginal repair for VVF is the easy and safe option for single fistulous opening irrespective of site, size and previously failed repair with lesser morbidity to the patient. Trans-vaginal repair of VVF avoid laparotomy and bladder bisection with reduced hospital stay.

References

1. Raashid Y, Majeed T, Nadeem M, Shafia S, Jaffri TH. Iatrogenic Vesicovaginal Fistula. JCPSP, 2010; Vol. 20 (7): 436-438.
2. Singh RB, Satish Dalal, Nanda S, Pavithran NM. Management of female uro-genital fistulas: Framing certain guidelines. Urology Annals, 2010; Vol. 2 (1): page 2-6.
3. Hilton P. Urogenital fistula in the UK: a personal case series managed over 25 years. BJU International. 2012; 110: 102-110.
4. RMathur R, Joshi N, Aggarwal G, Raikwar R, Shrivastava

- tava V, Mathur P, Raikwar P, Joshi R. Urogenital fistulae: A prospective study of 50 cases at a tertiary care hospital. *Urology Annals*, 2010; Vol. 2 (2): 67-70.
5. Ayed M, Atat RE, Hassine LB, Sfaxi M, Chebil M, Zmerli S. Prognostic factors of recurrence after vesico-vaginal fistula repair. *International Journal of Urology* 2006; 13: 345–349.
 6. Mohr S, Brandner S, Mueller MD, Dreher EF, Kuhn A. Sexual function following vaginal and abdominal fistula repair. *Am J Obstet Gynecol*. 2014 Feb 13.
 7. Altaweel MW, Rajih E, Alkhudair W. Interposition flaps in vesicovaginal fistula repairs can optimize cure rate. *Urology Annals*, 2013; Vol. 5 (4):
 8. Singh O, Gupta SS, Mathur RK. Urogenital fistulas in women, 5 – years’ experience at a single center. *Urol J*. 2010; 7: 35–3.
 9. Hilton P, Ward A. Epidemiological and surgical aspects of urogenital fistulae: A review of 25 years’ experience in southeast Nigeria. *Int Urogynecol J Pelvic Floor Dysfunct*. 1998; 9: 189–94.
 10. Hanif MS, Saeed K, Sheikh MA. Surgical Management of Genitourinary Fistula. *JPMA*, 2005; Vol. (55): 280.
 11. Lee D, Dillon BE, Lemack GE, Zimmern PE. Long-Term Functional Outcomes Following Non-radiated Vesicovaginal Repair. *The Journal of Urology*, 2014; Volume 191 (1): Pages 120-4.
 12. Shoukry MS, Hassouna ME, El-Salmy S, Abdel-Karim AM. Vaginal flap re-enforcement of vesico-vaginal fistula repair. *Int Urogynecol J*. 2010 Jul; 21 (7): 8299.
 13. Jalbani MH, Deenari RA, Shaikh JM. Vesico-Vaginal Fistula – Experience of Surgical Repair at Larkana. *Pak J Med Res*. 2006; Vol. 45 (3).
 14. Altaweel WM, Rajih E, Alkhudair W. Interposition flaps in vesicovaginal fistula repairs can optimize cure rate. *Urol Ann*. 2013 Oct-Dec; 5 (4): 270–272.
 15. Safan A, Shaker H, Abdelaal A, Mourad MS, Albaz M. Fibrin glue versus martius flap interpositioning in the repair of complicated obstetric vesicovaginal fistula. A prospective multi-institution randomized trial. *Neuro-urol Urodyn*. 2009; 28 (5): 438-41.
 16. Kaoutzanis C, Pannucci CJ, Sherick D. Use of gracilis muscle as a “walking” flap for repair of a rectovaginal fistula. *J Plast Reconstr Aesthet Surg*. 2013 Jul; 66 (7): e197-200.
 17. Sotelo R, Mariano MB, García – Seguí A, Dubois R, Spaliviero M, Keklikian W, Novoa J, Yaime H, Finelli A. Laparoscopic Repair Of Vesico-vaginal Fistula. *The Journal of Urology*, 2005; Vol. 173 (5): 1615–1618.
 18. Khan A, Sevilla C, Anger J. V858 Robotic Vesico-vaginal Fistula Repair. *The Journal of Urology*. 2011; Vol. 185 (4): e344.